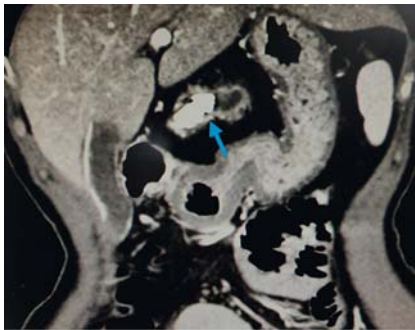
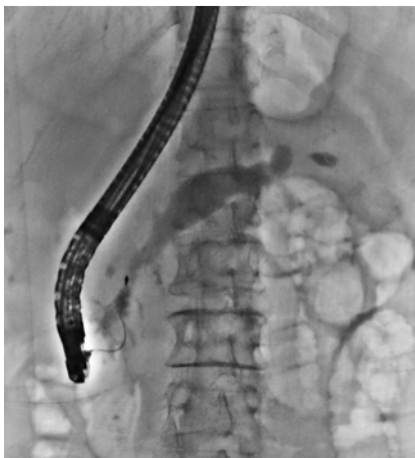

## Pancreatic sphincterotomy allows removal of a fractured stone basket trapped in the pancreatic duct after lithotripsy

OPEN  
ACCESS

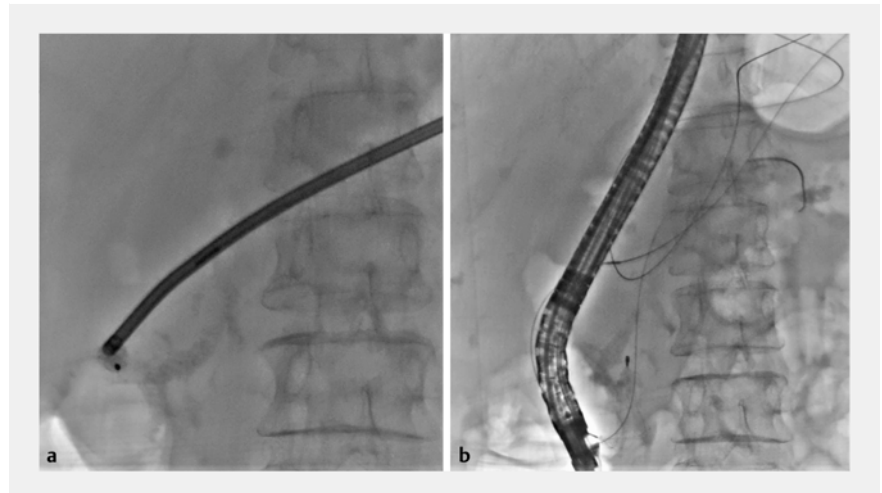

► **Fig. 1** A radiopaque stone within the dilated pancreatic duct seen on computed tomography.

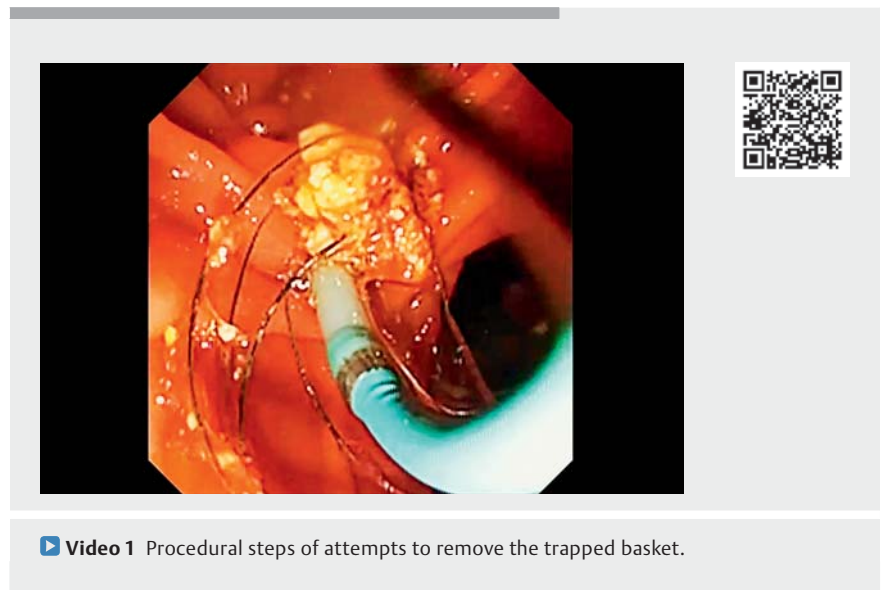


► **Fig. 2** The basket with the entrapped stone was impacted within the pancreatic duct at the papilla.

A 57-year-old woman presented with recurrent epigastric pain. Computed tomography of the abdomen revealed a 26-mm pancreatic stone obstructing the main pancreatic duct (MPD) in the body portion (► **Fig. 1**). We performed three sessions of extracorporeal shockwave lithotripsy (ESWL) using a third-generation lithotripter (Delta Compact II; Dornier MedTech, Weßling, Germany). Up to 5000 shocks were delivered per therapeutic session on a scale of 1 to 6, with a frequency of 120 shocks/min. Endoscopic retrograde cholangiopancreatog-



► **Fig. 3 a** A captured pancreatolith with mechanical lithotripsy being performed. **b** The basket fractured at the handle portion of the lithotripter and the wires fell into the digestive tract.



► **Video 1** Procedural steps of attempts to remove the trapped basket.

raphy (ERCP) was routinely performed to remove the pancreatolith after ESWL to avoid steinstrasse. After sphincterotomy, we attempted to remove the pancreatolith with an eight-wire basket (MB5-2X4-8; Wilson-Cook Medical Inc., Bloomington, Indiana, USA); however, the basket became trapped by the calculi near the pancreatic orifice at the papilla

(► **Fig. 2**). The first solution we thought of was mechanical lithotripsy, and as we feared, the wires broke near the handle of the lithotripter (► **Fig. 3 a, b**). Attempted reduction of the calculi with forceps and re-cannulating the MPD both failed. We employed a DualKnife (KD-650U, Olympus Corporation, Tokyo, Japan) to extend the sphincterotomy by approxi-

mately 3 mm. With the exposure of the trapped pancreatolith, forceps removed part of the calculi at the papilla. A guide-wire was then successfully passed through the fractured basket and pancreatolith complex, and the impacted complex was retrieved with a balloon (AMH-RBT; Anrei Medical, Hangzhou, China). Following this, the fractured basket was also successfully removed by forceps (► **Video 1**). The fragmented pancreatolith was also successfully removed by balloon and the patient was discharged uneventfully. Here, we report a successful retrieval of an impacted basket with the entrapped pancreatolith. Although the situation may have been reported in the literature [1–3], the operative procedure was thrilling and fascinating. We have shown that sphincterotomy extension is safe and effective in the management of this condition.

Endoscopy\_UCTN\_Code\_CPL\_1AK\_2AF

## Funding

National Natural Science Foundation of China  
<http://dx.doi.org/10.13039/501100001809>  
 82200718

## Competing interests

The authors declare that they have no conflict of interest.

## The authors

Yan Chen<sup>1,2‡</sup>, Li Yang<sup>1‡</sup>, Ting Yang<sup>1</sup>, Cui Liu<sup>1</sup>, Jie Chen<sup>1,2</sup>

- 1 Digestive Endoscopy Center, Changhai Hospital, Shanghai, China
- 2 Department of Gastroenterology, Changhai Hospital, Shanghai, China

## Corresponding author

### Jie Chen, MD

Department of Gastroenterology and Digestive Endoscopy Center, Changhai Hospital, 168 Changhai Road, Shanghai 200433, China  
 Fax: +86-021-55621735  
 cijj702@163.com

## References

- [1] Thomas M, Howell DA, Carr-Locke D et al. Mechanical lithotripsy of pancreatic and biliary stones: complications and available treatment options collected from expert centers. *Am J Gastroenterol* 2007; 102: 1896–1902
- [2] Cho MK, Song TJ, Park DH et al. Extracorporeal shock wave lithotripsy allows successful endoscopic removal of a fractured stone basket trapped in the pancreatic duct. *Endoscopy* 2016; 48: E65–E66
- [3] Ryozaawa S, Iwano H, Taba K et al. Successful retrieval of an impacted mechanical lithotripsy basket: a case report. *Dig Endosc* 2010; 22: S111–S113

## Bibliography

*Endoscopy* 2023; 55: E949–E950

DOI 10.1055/a-2134-8947

ISSN 0013-726X

© 2023. The Author(s).

This is an open access article published by Thieme under the terms of the Creative Commons Attribution License, permitting unrestricted use, distribution, and reproduction so long as the original work is properly cited.

(<https://creativecommons.org/licenses/by/4.0/>)

Georg Thieme Verlag KG, Rüdigerstraße 14, 70469 Stuttgart, Germany



## ENDOSCOPY E-VIDEOS

<https://eref.thieme.de/e-videos>



*E-Videos* is an open access online section of the journal *Endoscopy*, reporting on interesting cases

and new techniques in gastroenterological endoscopy. All papers include a high-quality video and are published with a Creative Commons CC-BY license. *Endoscopy E-Videos* qualify for HINARI discounts and waivers and eligibility is automatically checked during the submission process. We grant 100% waivers to articles whose corresponding authors are based in Group A countries and 50% waivers to those who are based in Group B countries as classified by Research4Life (see: <https://www.research4life.org/access/eligibility/>).

This section has its own submission website at

<https://mc.manuscriptcentral.com/e-videos>

<sup>‡</sup> Yan Chen and Li Yang contributed equally to this work.