



Nasopharyngeal Carcinoma: Case Presentation and Literature Review of Treatment Innovation with Immunotherapy

Somtochi Okafor¹ Jameel Muzaffar² David Jang¹ Ivan El Sayed³ Ralph Abi Hachem¹

¹Department of Head and Neck Surgery and Communication Sciences, Duke University Hospital, Durham, North Carolina, United States

²Department of Medicine, Medical Oncology, Duke University Hospital, Durham, North Carolina, United States

³Department of Otolaryngology Head and Neck Surgery, University of California, San Francisco, San Francisco, California, United States

Address for correspondence Somtochi Okafor, MD, Department of Head and Neck Surgery and Communication Sciences, Duke University Hospital, Durham, North Carolina, United States (e-mail: somtochi.okafor@duke.edu; somtochiokafor12@gmail.com).

J Neurol Surg Rep 2023;84:e113–e115.

Abstract

Nasopharyngeal carcinoma (NPC), a rare head and neck malignancy, arises from the epithelial lining of nasopharyngeal mucosa. The confluence of various risk factors, such as latent Epstein–Barr virus infection, genetic susceptibility, smoking, alcohol consumption, and high nitrosamine diet, is thought to contribute to NPC pathogenesis. Radiation therapy serves as the mainstay of treatment for early stage while concurrent chemotherapy and radiation are the basis of treatment for locoregional advanced disease with overall 80% five-year survival rate. Recurrent or metastatic disease pose treatment challenges as reirradiation, repeat cycles of chemotherapy, and surgery follow with high likelihood of treatment toxicity or postoperative morbidities. Typically reserved for nonresectable recurrent or metastatic disease, immunotherapy serves as novel treatment for NPC. NPC tumor microenvironment predominated by a dense infiltrate of immune cells hosts an ideal target for immunotherapy. Several clinical trials have investigated the efficacy of anti-programmed cell death protein 1 antibodies such as pembrolizumab, nivolumab, and camrelizumab with promising results. Treatment of recurrent and metastatic NPC remains a challenge; however, the advent of immunotherapy has provided additional options and potential for preventative and therapeutic measures.

Keywords

- ▶ nasopharyngeal carcinoma
- ▶ immunotherapy
- ▶ nasopharynx
- ▶ head and neck cancer
- ▶ EBV
- ▶ immune checkpoint inhibitors
- ▶ recurrent disease
- ▶ adoptive cell therapy

Case Presentation

A 60-year-old female presented with T2N0M0 nonkeratinizing Epstein–Barr virus (EBV) negative squamous cell carcinoma of the left nasopharynx (nasopharyngeal carcinoma [NPC]). She underwent 6 weeks of chemoradiation with cisplatin. Post-treatment positron emission tomography/computed tomog-

raphy (PET/CT) illustrated cervical lymphadenopathy and persistent disease in the nasopharynx (▶**Fig. 1**). Biopsy of cervical nodal uptake confirmed persistent disease. Thus, left neck dissection was performed. She was then referred to our center for endoscopic endonasal resection and craniotomy with carotid resection/bypass. Surgical margins were

received
July 12, 2023
accepted after revision
August 1, 2023
accepted manuscript online
August 3, 2023

DOI <https://doi.org/10.1055/a-2148-2429>.
ISSN 2193-6358.

© 2023. The Author(s).

This is an open access article published by Thieme under the terms of the Creative Commons Attribution-NonDerivative-NonCommercial-License, permitting copying and reproduction so long as the original work is given appropriate credit. Contents may not be used for commercial purposes, or adapted, remixed, transformed or built upon. (<https://creativecommons.org/licenses/by-nc-nd/4.0/>)

Georg Thieme Verlag KG, Rüdigerstraße 14, 70469 Stuttgart, Germany

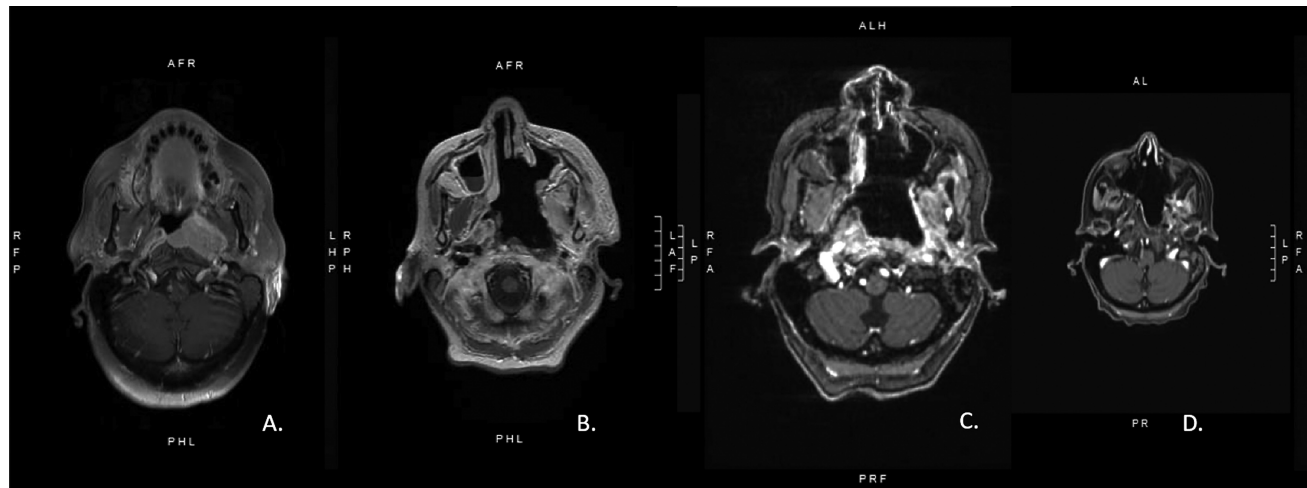


Fig. 1 Magnetic resonance imaging (MRI) throughout treatment course: presurgical, postsurgical, 3 months postsurgery, and 6 months postsurgery. (A) Presurgical MRI. (B) Postoperative MRI. (C) Three months postoperative MRI. (D) Six months postoperative MRI illustrating recurrence in the left nasopharynx.

negative. However, 7-month posttreatment PET/CT illustrated residual disease, which was confirmed on biopsy (→**Fig. 2**). She started pembrolizumab and experienced interval improvement over the course of 8 months. She then completed four cycles of gemcitabine/cisplatin (GP). Due to persistent disease, she continued pembrolizumab and started capecitabine as well. Given disease progression, lenvatinib was added in lieu of capecitabine. She remains on pembrolizumab and lenvatinib 3 years since initial diagnosis with stable disease.

Literature Review

Radiation therapy serves as the mainstay of treatment for NPC in early-stage disease while concurrent chemoradiation is the basis for locoregional advanced disease with 80% five-year survival rate.¹⁻⁶ Approximately 15% of patients experience recurrent or metastatic disease.³⁻⁶ Locoregional recurrence may prompt surgical intervention.^{1,7,8} Recurrence or metastasis pose treatment challenges as reirradiation, repeat

chemotherapy, and surgery are associated with treatment toxicity and morbidity.^{1,9}

Immunotherapy is reserved for nonresectable recurrent or metastatic disease.¹⁰ Current strategies include immune checkpoint inhibitors, EBV-directed vaccination, and adoptive T cell therapy.^{1,10}

The immunosuppressive NPC tumor microenvironment boasts an overexpression of inhibitory immune checkpoints, an ideal target for immune checkpoint inhibitors (ICIs).^{1,10} Clinical trials have investigated the efficacy of anti-programmed cell death protein 1 (PD-1) antibodies such as pembrolizumab, nivolumab, and camrelizumab with promising results.¹¹⁻¹³ The KEYNOTE-028 trial investigated the efficacy of pembrolizumab in unresectable recurrences revealing a 26% objective response rate (ORR) and 33% one-year progression-free survival (PFS).¹¹ However, the KEYNOTE-122, phase III trial illustrated that pembrolizumab did not improve PFS or ORR compared with chemotherapy.¹⁴ A phase II trial assessing nivolumab response in recurrent or metastatic NPC noted a 20% ORR with 59% one-year overall survival (OS).¹²

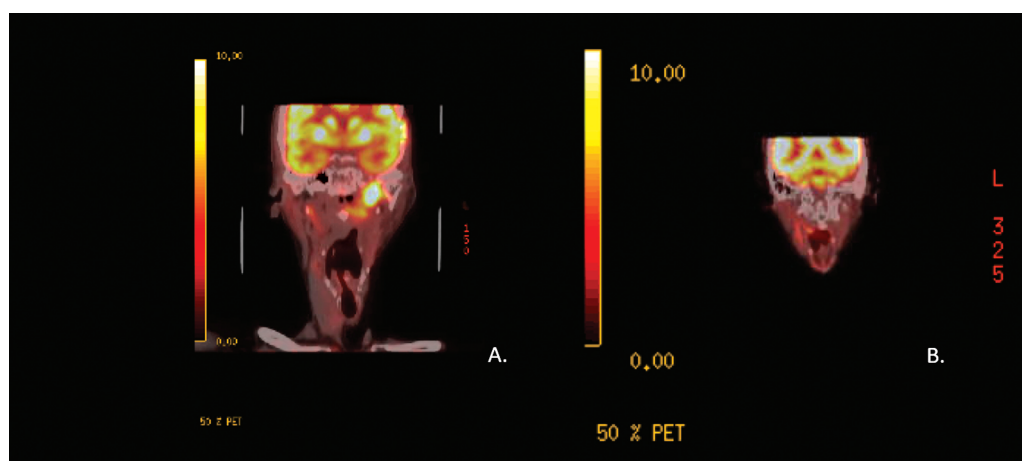


Fig. 2 Positron emission tomography/computed tomography (PET/CT) scan imaging illustrating recurrence postsurgery and immunotherapy treatment response. (A) PET/CT illustrating recurrence postsurgery. Six months PET/CT illustrating complete response to pembrolizumab.

Two single-arm phase I trials evaluated camrelizumab as (1) monotherapy in recurrence or metastasis with a 34% ORR and 27% one-year PFS and (2) combined with GP in patients with recurrence or metastasis disease yielding a 91% ORR and 61% PFS.^{1,13} The JUPITER-02 trial assessed the efficacy of toripalimab combined with GP versus placebo and GP, revealing 49.4% of patients in the combination arm experienced PFS, compared with 27.9% in the control arm.^{15,16} A meta-analysis of ICIs noted 27% ORR and 61% OS.¹⁷

EBV-directed vaccination offers preventative and therapeutic strategies against infection with EBV, a key contributor to the pathogenesis of NPC.¹⁸ Previous clinical trials investigated peptide and viral vaccines by targeting EBV glycoproteins: gH/gL and gB, membrane proteins critical for epithelial cell infection, and virus-like proteins target antigens such as latent membrane protein 1 (LMP1) or LMP2, key drivers in malignant transformation of EBV-infected cells.^{18,19} A phase I trial noted partial clinical response in advanced EBV-associated NPC.¹⁹

Ultimately, treatment of recurrent or metastatic NPC remains complex and requires a multifaceted approach. The advent of immunotherapy, primarily anti-PD-1 antibodies, as novel treatment for recurrent or metastatic NPC has provided an additional treatment option. Although clinical trials have illustrated promising results, long-term follow-up studies are necessary.

Conflict of Interest

None declared.

References

- Chen YP, Chan ATC, Le QT, Blanchard P, Sun Y, Ma J. Nasopharyngeal carcinoma. *Lancet* 2019;394(10192):64–80
- Chen L, Hu CS, Chen XZ, et al. Adjuvant chemotherapy in patients with locoregionally advanced nasopharyngeal carcinoma: long-term results of a phase 3 multicentre randomised controlled trial. *Eur J Cancer* 2017;75:150–158
- Kong L, Zhang Y, Hu C, Guo Y, Lu JJ. Effects of induction docetaxel, platinum, and fluorouracil chemotherapy in patients with stage III or IVA/B nasopharyngeal cancer treated with concurrent chemoradiation therapy: final results of 2 parallel phase 2 clinical trials. *Cancer* 2017;123(12):2258–2267
- Li W-F, Chen N-Y, Zhang N, et al. Concurrent chemoradiotherapy with/without induction chemotherapy in locoregionally advanced nasopharyngeal carcinoma: long-term results of phase 3 randomized controlled trial. *Int J Cancer* 2019;145(01):295–305
- Yang Q, Cao S-M, Guo L, et al. Induction chemotherapy followed by concurrent chemoradiotherapy versus concurrent chemoradiotherapy alone in locoregionally advanced nasopharyngeal carcinoma: long-term results of a phase III multicentre randomised controlled trial. *Eur J Cancer* 2019;119:87–96
- Hong RL, Hsiao CF, Ting LL, et al. Final results of a randomized phase III trial of induction chemotherapy followed by concurrent chemoradiotherapy versus concurrent chemoradiotherapy alone in patients with stage IVA and IVB nasopharyngeal carcinoma-Taiwan Cooperative Oncology Group (TCOG) 1303 Study. *Ann Oncol* 2018;29(09):1972–1979
- Zou X, Han F, Ma WJ, et al. Salvage endoscopic nasopharyngectomy and intensity-modulated radiotherapy versus conventional radiotherapy in treating locally recurrent nasopharyngeal carcinoma. *Head Neck* 2015;37(08):1108–1115
- Chen MY, Wang SL, Zhu YL, et al. Use of a posterior pedicle nasal septum and floor mucoperiosteum flap to resurface the nasopharynx after endoscopic nasopharyngectomy for recurrent nasopharyngeal carcinoma. *Head Neck* 2012;34(10):1383–1388
- Lee AWM, Ng WT, Chan JYW, et al. Management of locally recurrent nasopharyngeal carcinoma. *Cancer Treat Rev* 2019;79:101890
- Wong KCW, Hui EP, Lo KW, et al. Nasopharyngeal carcinoma: an evolving paradigm. *Nat Rev Clin Oncol* 2021;18(11):679–695
- Hsu C, Lee SH, Ejadi S, et al. Safety and antitumor activity of pembrolizumab in patients with programmed death-ligand 1-positive nasopharyngeal carcinoma: results of the KEYNOTE-028 study. *J Clin Oncol* 2017;35(36):4050–4056
- Ma BBY, Lim WT, Goh BC, et al. Antitumor activity of nivolumab in recurrent and metastatic nasopharyngeal carcinoma: an international, multicenter study of the Mayo Clinic Phase 2 Consortium (NCI-9742). *J Clin Oncol* 2018;36(14):1412–1418
- Fang W, Yang Y, Ma Y, et al. Camrelizumab (SHR-1210) alone or in combination with gemcitabine plus cisplatin for nasopharyngeal carcinoma: results from two single-arm, phase 1 trials. *Lancet Oncol* 2018;19(10):1338–1350
- Chan ATC, Lee VHF, Hong RL, et al. Pembrolizumab monotherapy versus chemotherapy in platinum-pretreated, recurrent or metastatic nasopharyngeal cancer (KEYNOTE-122): an open-label, randomized, phase III trial. *Ann Oncol* 2023;34(03):251–261
- Tan LLY, Le QT, Lee NYY, Chua MLK. JUPITER-02 trial: advancing survival for recurrent metastatic nasopharyngeal carcinoma and next steps. *Cancer Commun (Lond)* 2022;42(01):56–59
- Mai HQ, Chen QY, Chen D, et al. Toripalimab or placebo plus chemotherapy as first-line treatment in advanced nasopharyngeal carcinoma: a multicenter randomized phase 3 trial. *Nat Med* 2021;27(09):1536–1543
- Wang B-C, Cao R-B, Fu C, et al. The efficacy and safety of PD-1/PD-L1 inhibitors in patients with recurrent or metastatic nasopharyngeal carcinoma: a systematic review and meta-analysis. *Oral Oncol* 2020;104:104640
- Li W, Duan X, Chen X, et al. Immunotherapeutic approaches in EBV-associated nasopharyngeal carcinoma. *Front Immunol* 2023; 13:1079515
- Lin CL, Lo WF, Lee TH, et al. Immunization with Epstein-Barr virus (EBV) peptide-pulsed dendritic cells induces functional CD8+ T-cell immunity and may lead to tumor regression in patients with EBV-positive nasopharyngeal carcinoma. *Cancer Res* 2002;62(23):6952–6958