Thieme

Endoscopic intermuscular dissection of a residual rectal neuroendocrine tumor with high-pressure injection and double-clip traction

Endoscopic resection, with advanced techniques such as modified endoscopic mucosal resection (EMR) or endoscopic submucosal dissection (ESD), is the first-line treatment for small grade 1 rectal neuroendocrine tumors (NETs), and complete histological resection is mandatory to avoid overtreatment or unnecessary follow-up [1]. Rectal NETs are rare tumors that can be misdiagnosed and consequently inadequately resected with cold snare, hot snare polypectomy, or biopsy forceps, leading to incomplete resection [2]. In such cases, complementary resection using ESD or transanal endoscopic microsurgery can be proposed to achieve complete resection and dispense with further follow-up [3]. Recently, endoscopic intermuscular dissection has been described to increase the deep resection margin for invasive submucosal rectal cancer [4].

We report the case of a 26-year-old man with previously incomplete resection by conventional EMR of a grade 1 10-mm rectal NET with deep margin involvement (▶ **Fig. 1**). In order to achieve complete en bloc resection of the residual lesion with tumor-free margins, we performed intermuscular endoscopic dissection (▶ **Video 1**).

After marking the lesion, submucosal injection of glycerol mixed with indigo carmine and mucosal incision using a HybridKnife type I (Erbe Elektromedizin GmbH, Tübingen, Germany) were performed, followed by trimming of the submucosal layer. Then, a circumferential incision of the circular muscular layer was performed, with exposure of the longitudinal muscular layer (▶ **Fig. 2**). Exposure of the intermuscular plan was improved with double-clip countertraction, with the clip grasping the internal circular muscular layer (▶ **Fig. 3**). In addition, high-pressure glycerol injection through the HybridKnife was useful in dramatical-

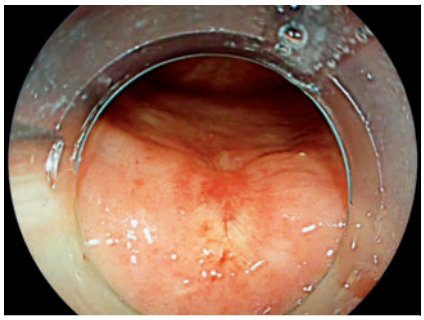

▶ **Fig. 1** Residual rectal neuroendocrine tumor.

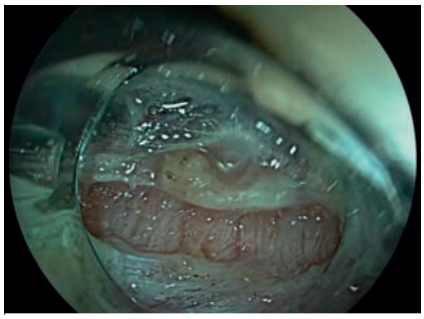

▶ **Fig. 2** Incision of the circular muscular layer and visualization of the intermuscular space.

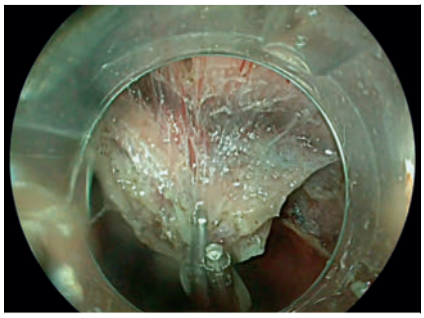

▶ **Fig. 3** Double-clip traction increasing visualization of the intermuscular space.

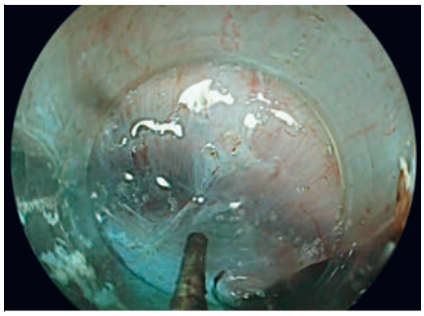

▶ **Fig. 4** High-pressure intermuscular injection enlarging intermuscular space.

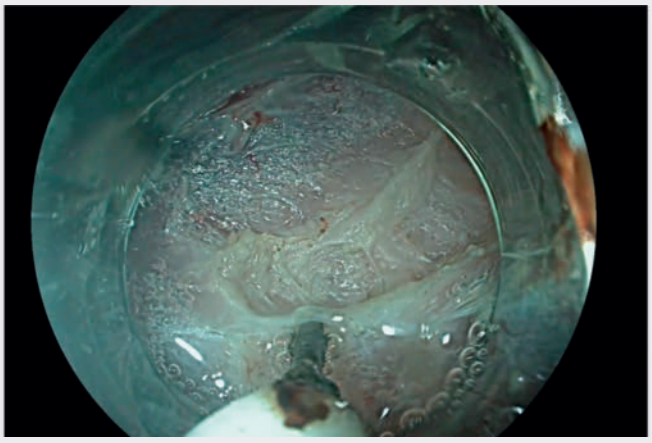

Video 1 Endoscopic intermuscular dissection of a residual rectal neuroendocrine tumor with high-pressure injection and double-clip traction.

ly enlarging the visible plan between the two muscular layers (▶ **Fig. 4**) and performing safe complete endoscopic resection without damage to the longitudinal muscular layer.

Histopathological examination of the specimen showed millimetric residual grade 1 well-differentiated NET, with lateral and deep free margins of more than 2 mm. The patient was discharged the same day and no adverse events occurred.

Endoscopic intermuscular dissection with traction and efficacious injection allows accurate resection of small rectal NETs, thus avoiding the risk of positive deep margins, and should be considered in order to protect against incomplete resection.

Endoscopy_UCTN_Code_TTT_1AQ_2AD

Conflict of Interest

M. Schaefer and J. Jacques have received honoraria from ERBE Medical for educational purposes.

The authors

Marion Schaefer[1], Jérémie Albouys[2], Sophie Geyl[2], Romain Legros[2], Timothée Wallenhorst[3], Mathieu Pioche[4], Jérémie Jacques[2,5]

1 Hepatogastroenterology, Nancy Regional University Hospital Center, Nancy, France
2 Hepatogastroenterology, Dupuytren Hospital, Limoges, France
3 Department of Gastroenterology, Pontchaillou Hospital, Rennes, France
4 Endoscopy and Gastroenterology, Edouard Herriot Hospital, Lyon, France
5 BioEM, XLim, UMR 7252, CNRS, Limoges, France

Corresponding author

Marion Schaefer, MD
Service d'hépatogastroentérologie, CHRU de Nancy, Rue du Morvan, 54511 Vandoeuvre les Nancy, France
m.schaefer@chru-nancy.fr

References

[1] Deprez PH, Moons LMG, O'Toole D et al. Endoscopic management of subepithelial lesions including neuroendocrine neoplasms: European Society of Gastrointestinal Endoscopy (ESGE) Guideline. Endoscopy 2022; 54: 412–429. doi:10.1055/a-1751-574235180797

[2] Fine C, Roquin G, Terrebonne E et al. Endoscopic management of 345 small rectal neuroendocrine tumours: a national study from the French group of endocrine tumours (GTE). United European Gastroenterol J 2019; 7: 1102–1112

[3] de Mestier L, Lepage C, Baudin E et al. Digestive neuroendocrine neoplasms (NEN): French Intergroup clinical practice guidelines for diagnosis, treatment and follow-up (SNFGE, GTE, RENATEN, TENPATH, FFCD, GERCOR, UNICANCER, SFCD, SFED, SFRO, SFR). Dig Liver Dis 2020; 52: 473–492. doi:10.1016/j.dld.2020.02.01132234416

[4] Moons LMG, Bastiaansen BAJ, Richir MC et al. Endoscopic intermuscular dissection for deep submucosal invasive cancer in the rectum: a new endoscopic approach. Endoscopy 2022; 54: 993–998. doi:10.1055/a-1748-857335073588

Bibliography

Endoscopy 2023; 55: E1126–E1127
DOI 10.1055/a-2173-7103
ISSN 0013-726X

Georg Thieme Verlag KG, Rüdigerstraße 14, 70469 Stuttgart, Germany