



Identification of impactful imaging biomarker: Clinical applications for breast and prostate carcinoma

Ermittlung aussagekräftiger Bildgebungsbiomarker: Klinische Anwendungen bei Mamma- und Prostatakarzinomen

Authors

Tobias Bäuerle¹, Matthias Dietzel¹ , Katja Pinker², David Bonekamp³, Kevin S. Zhang³, Heinz-Peter Schlemmer³, Peter Bannas⁴, Clemens C. Cyran⁵, Michel Eisenblätter⁶, Ingrid Hilger⁷, Caroline Jung⁴, Fritz Schick⁸, Franz Wegner⁹, Fabian Kiessling¹⁰ 

Affiliations

- 1 Institute of Radiology, University Medical Center Erlangen, Germany
- 2 Department of Radiology, Memorial Sloan Kettering Cancer Center, New York, United States
- 3 Department of Radiology, German Cancer Research Center, Heidelberg, Germany
- 4 Institute of Diagnostic and Interventional Radiology, University Medical Center Hamburg-Eppendorf, Hamburg, Germany
- 5 Institute of Radiology, University Medical Center München (LMU), München, Germany
- 6 Diagnostische und Interventionelle Radiologie, Universitätsklinikum OWL, Universität Bielefeld Campus Klinikum Lippe, 32756 Detmold, Germany
- 7 Experimental Radiology, University Medical Center Jena, Germany
- 8 Experimental Radiology, University Medical Center Tübingen, Germany
- 9 Department of Radiology, University Hospital Schleswig-Holstein Campus Lübeck, Germany
- 10 Experimental Molecular Imaging, University Medical Center Aachen, Germany

Keywords

quantification, artificial intelligence, imaging, breast cancer, prostate cancer, biomarker

received 14.04.2023

accepted 19.08.2023

published online 09.11.2023

Bibliography

Fortschr Röntgenstr 2024; 196: 354–362

DOI 10.1055/a-2175-4446

ISSN 1438-9029

© 2023, Thieme. All rights reserved.

Georg Thieme Verlag KG, Rüdigerstraße 14, 70469 Stuttgart, Germany

Correspondence

Herr Prof. Tobias Bäuerle

Institute of Radiology, University Medical Center, Maximiliansplatz 1, 91054 Erlangen, Germany

Tel.: +49/(0)91 31/8 52 33 43

Fax: +49/(0)91 31/8 53 60 68

tobias.baeuerle@uk-erlangen.de

ABSTRACT

Background Imaging biomarkers are quantitative parameters from imaging modalities, which are collected noninvasively, allow conclusions about physiological and pathophysiological processes, and may consist of single (monoparametric) or multiple parameters (bi- or multiparametric).

Method This review aims to present the state of the art for the quantification of multimodal and multiparametric imaging biomarkers. Here, the use of biomarkers using artificial intelligence will be addressed and the clinical application of imaging biomarkers in breast and prostate cancers will be explained. For the preparation of the review article, an extensive literature search was performed based on Pubmed, Web of Science and Google Scholar. The results were evaluated and discussed for consistency and generality.

Results and Conclusion Different imaging biomarkers (multiparametric) are quantified based on the use of complementary imaging modalities (multimodal) from radiology, nuclear medicine, or hybrid imaging. From these techniques, parameters are determined at the morphological (e. g., size), functional (e. g., vascularization or diffusion), metabolic (e. g., glucose metabolism), or molecular (e. g., expression of prostate specific membrane antigen, PSMA) level. The integration and weighting of imaging biomarkers are increasingly being performed with artificial intelligence, using machine learning algorithms. In this way, the clinical application of imaging biomarkers is increasing, as illustrated by the diagnosis of breast and prostate cancers.

Key Points

- Imaging biomarkers are quantitative parameters to detect physiological and pathophysiological processes.

- Imaging biomarkers from multimodality and multiparametric imaging are integrated using artificial intelligence algorithms.
- Quantitative imaging parameters are a fundamental component of diagnostics for all tumor entities, such as for mammary and prostate carcinomas.

Citation Format

- Bäuerle T, Dietzel M, Pinker K et al. Identification of impactful imaging biomarker: Clinical applications for breast and prostate carcinoma. *Fortschr Röntgenstr* 2024; 196: 354–362

ZUSAMMENFASSUNG

Hintergrund Bildgebungsbiomarker sind quantitative Parameter aus bildgebenden Modalitäten, welche nicht-invasiv erhoben werden und Aussagen über physiologische und pathophysiologische Abläufe zulassen, wobei diese aus einzelnen (monoparametrisch) oder mehreren Parametern (bi- bzw. multiparametrisch) bestehen können.

Methode Die vorliegende Übersichtsarbeit soll den Stand der Technik zur Quantifizierung von multimodalen und multiparametrischen Bildgebungsbiomarkern vorstellen. Hierbei wird die Nutzung von Biomarkern mittels künstlicher Intelli-

genz thematisiert und die klinische Anwendung von bildgebenden Biomarkern bei Mamma- und Prostatakarzinomen erläutert. Für die Anfertigung des Übersichtsartikels wurde basierend auf Pubmed, Web of Science und Google Scholar eine ausführliche Literaturrecherche durchgeführt. Die Ergebnisse wurden hinsichtlich Stimmigkeit und Allgemeingültigkeit ausgewertet und diskutiert.

Ergebnisse und Schlussfolgerung Die Quantifizierung von unterschiedlichen bildgebenden Biomarkern erfolgt aus der Nutzung komplementärer Bildgebungsmodalitäten (multimodal) radiologischer und nuklearmedizinischer Techniken bzw. von Hybridverfahren. Aus diesen Techniken werden Parameter auf morphologischer (z. B. Größe), funktioneller (z. B. Vaskularisierung oder Diffusion), metabolischer (z. B. Glukosestoffwechsel) und molekularer (z. B. Expression des Prostata-spezifischen Membranantigens, PSMA) Ebene bestimmt. Die Integration und Wichtung von bildgebenden Biomarkern erfolgt zunehmend mit der künstlichen Intelligenz, wobei Algorithmen des maschinellen Lernens genutzt werden. Auf diesem Wege nimmt die klinische Anwendung von bildgebenden Biomarkern zu, was anhand der Diagnostik von Mamma- und Prostatakarzinomen erläutert wird.

1. Introduction

Biomarkers are measurable parameters that are recorded in blood, urine or tissue, and reveal regular biological processes as well as pathological changes. The mission of biomarkers is to make diseases more treatable. This can be achieved by either better classifying disease processes and creating patient subpopulations to which therapies can be tailored, or by better monitoring and managing the response of therapies. Compared to biomarkers from blood, urine or tissues, imaging biomarkers allow a local assignment of the processes and thus often have a higher sensitivity and specificity. In general, biomarkers should be quantifiable, reproducible, inexpensive, and require as little time as possible to collect. In this regard, imaging biomarkers often have a disadvantage compared to, for example, laboratory parameters, but this can be compensated by incorporating the collection of imaging biomarkers into routine imaging that is performed anyway. Compared to histological biomarkers, an advantage is the lack of invasiveness, the possibility of multiple longitudinal examinations, and the often higher representativeness compared to small tissue biopsies taken [1].

This review article discusses the strengths and weaknesses of different classes of imaging biomarkers for use in disease screening, treatment planning, and therapy monitoring. It will explain how computer-based image analysis using artificial intelligence (AI) will create new qualities of imaging biomarkers and what the challenges for their implementation in clinical practice are. An extensive literature search based on Pubmed, Web of Science, and Google Scholar was performed for the preparation of the

present work. The results were evaluated and discussed in terms of consistency and general validity.

2. Quantification and validation of biomarkers

Non-invasive imaging biomarker detection is primarily performed from radiological and nuclear medicine datasets of magnetic resonance imaging (MRI), computed tomography (CT), ultrasound (US), positron emission tomography (PET), and single photon emission computed tomography (SPECT), the latter being used almost exclusively in hybrid PET/CT, PET/MRI, or SPECT/CT. The goal is the standardized quantitative recording of imaging parameters (quantitative imaging biomarkers, QIB), which are as independent as possible from the respective center, imaging technique and equipment manufacturer. To this end, the *Quantitative Imaging Biomarkers Alliance* of the Radiological Society of North America (RSNA) and the European Society of Radiology (ESR) have proposed a cross-platform biomarker qualification profile that allows standardization at the acquisition level [1, 2]:

A prerequisite for the use of quantitative biomarkers is comprehensive validation at the technical and clinical level. First, a multilevel technical validation of the biomarkers is performed, assessing the precision of the imaging parameters depending on the center of data acquisition, the equipment manufacturer, the examination protocol, and the patient preparation. The parameter accuracy must then be checked on the phantom and compared with the current reference standard – in most cases with the histology after biopsy backup [3]. The final validation at the clinical level includes the assessment of diagnostic and therapeutic

value in the short-term course and the evaluation of prognostic significance in the longer-term observation [1, 2].

For the quantitative detection of biomarkers, the definition of a target region of interest (ROI) or a target volume of interest (VOI) is of central importance [4]. Since the definition of the outer limits of a lesion is subjective and depends in particular on the experience of the examiner, automated segmentation can increase accuracy and repeatability. Pattern recognition methods are used for (semi-)automated segmentation, often supported by machine learning (ML) or neural networks [5]. A consensus recommendation from ESR and the European Organization for Research and Treatment of Cancer (EORTC) recently presented the following recommendations for standardized segmentation of lesions (abbreviated from [2]):

- Segmentation should follow organ-specific policies and standard operating protocols, and always use the same algorithms.
- Direct reconstruction, iterative reconstruction, and machine and deep learning-based reconstructions are allowed in segmentation.
- A reference standard that uses manual or automated segmentation must include multiple independent segmentations by trained observers.
- When segmenting fuzzy-bordered lesions, multimodal imaging should be used as a reference to determine the extent of the structure in conjunction with morphologic and functional or metabolic imaging.

Specific examples of quantification and validation of biomarkers such as size, diffusion, and perfusion of lesions of the breast and prostate are given in Sections 5.1 and 5.2.

3. Integration of biomarkers using artificial intelligence

The multitude of quantitative biomarkers resulting from multimodal (use of complementary imaging modalities) and multiparametric (use of multiple contrast mechanisms) imaging with varying accuracy and relevance to the particular disease entity requires complex statistical evaluation. For example, following the assumption that quantitative features from radiological images (radiomics) reflect pathophysiological processes, several hundred features are extracted from radiological datasets and then analyzed [6]. These consist of mathematical descriptors of texture, heterogeneity, and shape. Extensive computational processes are required to establish a relationship between the radiological signature of the radiomics analysis and a clinical target parameter. In recent years, AI algorithms have been increasingly used to address this issue by integrating biomarkers and weighting them differently.

Artificial neural networks, which can combine multiple parameters and perform predictive classification tasks with high accuracy, are often used to integrate multiple parameters from multimodal imaging by ML [7]. The functioning of a neural network is similar to the human brain, in which nerve cells represent nodes that are interconnected. Specific connections that provide advantages in behavior, body movement, memory, or mental activity

are practiced and formed over time, which we call learning. Artificial neural networks are combinations of artificial nodes organized into layers, with the prediction parameters forming the bottom layer and the output forming the top layer. An additional intermediate layer contains hidden neural nodes that receive inputs from the predictors and form the output. The connections between these artificial neural nodes are initially randomly weighted, but are adjusted as the network is trained. This allows trained artificial networks to solve, for example, classification tasks with high accuracy. Their accuracy can be further increased by averaging the outputs of multiple models, resulting in Averaged-Model Neural Networks (avNNet). The underlying consideration is that the bias of such a network ensemble remains unchanged, while the error variance decreases significantly. In addition to classical neural networks, Generative Adversarial Networks (GAN) and Latent Space Models (LSPMs) may gain importance in the future, which can generate synthetic data and provide prognostic information in addition to diagnostic information [8]. For example, ML algorithms successfully integrated QIB from multiparametric imaging to characterize suspicious lesions of breast and prostate carcinoma, with ML-integrated parameters showing higher sensitivities and specificities than the respective individual parameters with respect to dignity determination (► Fig. 1) [9, 10].

4. Clinically relevant biomarkers

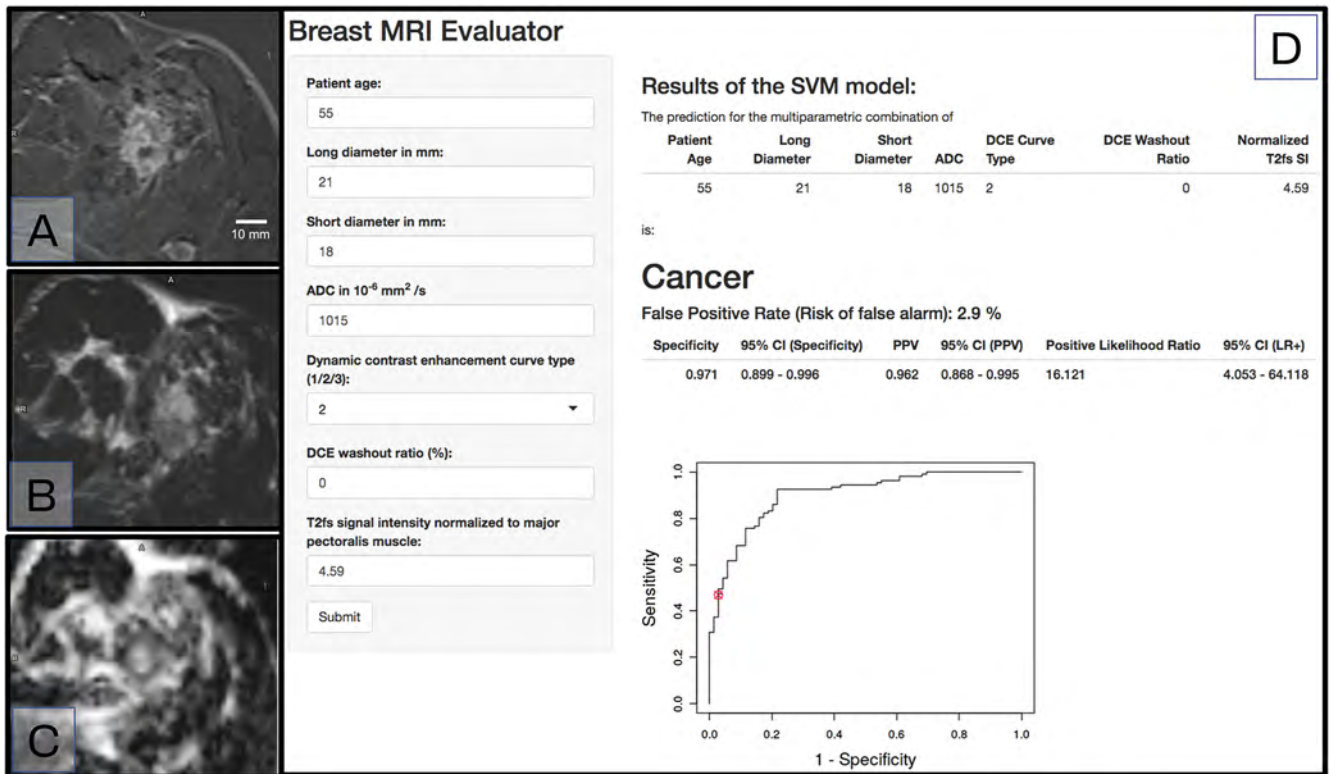
The clinical relevance of quantitative biomarkers is undisputed and is used in almost all clinical pictures that can be detected with radiology and nuclear medicine. However, the use of definitive thresholds to confidently distinguish normal from pathologic tissue based on absolute quantitative measures is often difficult. In this respect, semi-quantitative scoring systems are often used for assessment, such as in multiple sclerosis with MRI [11], in lymphoma with PET [12], or in liver tumors with CT/MRI [13].

The simplest quantitative measurement is the recording of size or diameter, for example used for staging and follow-up of solid tumors in the Response Evaluation Criteria in Solid Tumors (RECIST) [14]. The use of volumes instead of size measurement is not currently used in routine clinical practice, although several studies have shown the prognostic superiority of this method [15]. However, robust automated segmentation is needed for clinical implementation of volumetry of target structures. Quantitative biomarkers in breast and prostate carcinomas are discussed below.

5. Clinical validation

5.1 Breast carcinoma

Breast cancer is the most common cancer affecting women and was responsible for 684 996 deaths worldwide in 2020 [16]. Breast diagnostic imaging is essential in the screening and treatment of the disease [17, 18]. Digital mammography (including more advanced techniques such as digital tomosynthesis and contrast-enhanced mammography), ultrasound and MRI are the main methods of breast diagnostic imaging [17, 18]. Imaging biomar-



► **Fig. 1** Integration of multiparametric breast MRI data by an AI tool to predict malignancy probability. Shown is a clinical example and the corresponding results of the interactive AI tool. Clinical example of a 55-year-old female patient. This shows a 21 × 18 mm lesion in subtracted T1w after application of gadolinium (A). A type 2 curve was present. Analysis of signal intensity in T2w (B) revealed a signal intensity value of 4.6. The apparent diffusion coefficient (C) was 1015 × 10⁻⁶ mm²/s. Histopathology: G3 invasive breast carcinoma nonspecific type. User interface of the integrative AI tool (D): In the left column, the values from the clinical case are already entered. From this, the integrative AI tool first determines a binary diagnosis (here: “Cancer”), which is differentiated with a statistical measure (“false positive rate”). At the same time, the diagnostic window of the finding is shown on the area under the receiver operating curve. Specificity, positive predictive value (PPV) together with corresponding confidence interval (CI) finally enable.

kers of breast carcinoma are widely used in both routine clinical practice and scientific research [19]. In this section we present essential imaging biomarkers of breast cancer and discuss their future development using selected examples.

Breast density is the most important imaging biomarker of breast cancer [20]. At the same time, it is considered one of the most important and best-validated QIB ever. Breast density describes the ratio of fibroglandular and fatty tissue of the breast. In addition to limited sensitivity of mammography, women with higher breast density have a higher risk of developing breast cancer in the future [20]. In clinical practice, breast density is assessed in four categories (A to D) [21]. Using an automated volumetric analysis, breast density can be measured as QIB. Various software tools are now available to automatically quantify breast density and are widely used in clinical and scientific practice.

The randomized controlled DENSE trial is an example of the central importance of QIB in breast diagnostic imaging. Based on the QIB “extremely dense breast” (measured in an automated fashion), women were offered screening MRI in addition to X-ray mammography. This risk stratification made it possible to detect significantly more breast carcinomas and, at the same time, reduce the rate of interval carcinomas. Based on these results, the European Society of Breast Imaging (EUSOBI) now recommends

that women aged 50 to 70 years with extremely dense breasts be offered breast MRI examinations every 2 to 4 years [22].

In addition to this quantitative assessment of breast tissue, AI-assisted structural analysis of the parenchyma is increasingly coming into scientific focus [23, 24]. Available results suggest that this allows for improved risk profiling [23]. However, the current data on this QIB should still be interpreted as preliminary. Comprehensive clinical validation is still pending [23, 24].

From a molecular imaging perspective, expression of estrogen receptors (ER), progesterone receptors (PR), and HER2 receptors in breast tumors is an important biomarker in breast cancer. They play a significant role in treatment decisions and prognosis assessment of this tumor entity [25].

Tumor vascularization is a typical feature of breast carcinoma. Patterns of tumor vascularization are considered imaging biomarkers of breast carcinoma [19]. Dynamic contrast-enhanced (DCE) MRI has been established for the analysis of tumor vascularization. The method provides imaging biomarkers for both detection and characterization (“benign or malignant?”) of suspicious findings [17, 19]. Semiquantitative and semantic criteria for tumor vascularization are well established in clinical practice [26, 27]. In contrast, QIBs promise a more objective analysis of tumor vascularization and are therefore of utmost interest [28]. Despite the

extensive research activities in the last decades, no such QIB has yet found its way into clinical routine. Sequence design, longer scan time, complex post-processing, and lack of standardization of available methods are considered the biggest hurdles to this.

Tumor size is a classic QIB of breast carcinoma. Larger tumors are usually associated with a worse prognosis [29]. In addition, tumor size is pivotal in assessing the response to therapy [30]. This explains why noninvasive, image-based quantification of tumor size is critical for patient management. In principle, all methods of breast diagnostic imaging are suitable for the assessment of tumor size [17, 18]. However, MRI allows particularly accurate, three-dimensional, and superposition-free quantification of tumor size [17, 30]. In addition to the structural assessment of tumor size, the importance of functional tumor size is increasingly coming to the fore. By combining vascularization and volumetry, a functional analysis of tumor heterogeneity is possible. Current data suggest that functional tumor volumetry provides diagnostically important and prognostically relevant additional information (► **Fig. 2**) [31]. However, the challenges described in quantifying tumor vascularization also apply to this approach. Accordingly, a broad clinical application of functional tumor volumetry is not yet foreseeable at this stage.

Morphology is an essential imaging biomarker in breast cancer diagnosis. Both the morphology of the carcinoma itself and its tumor habitat provide important diagnostic and prognostic information [19]. These allow identification of imaging phenotypes that support both characterization (“benign or malignant?”) and subtyping (“in situ or invasive carcinoma?” “aggressive carcinoma?” etc.). Such phenotypes derived from imaging are objectified by the Breast Imaging Reporting and Documentation System (BI-RADS) [19]. The Kaiser score can be determined from the BI-RADS MRI finding. A comprehensive validated and widely used methodology that documents imaging-derived phenotypes as a simple metric [27, 32]. Notwithstanding the advantages mentioned above, the BI-RADS and Kaiser scores are based on visual analysis. Therefore, the development of QIB for more objective morphological analysis of breast carcinomas is promising. Currently, diffusion-weighted imaging (DWI) is the closest approach to this claim [26]. The DWI determines the apparent diffusion coefficient (ADC). This QIB allows a quantitative evaluation of the tissue microstructure [26]. Clinically, the ADC is already used for tissue characterization: A high ADC value is considered a reliable exclusion criterion for the presence of breast cancer (cut-off: $1.5 \cdot 10^{-3} \text{ mm}^2/\text{s}$) [33]. Of critical importance to the management of breast carcinoma is the early differentiation between invasive and in-situ stages. For this reason, initial results are promising, showing that ADC can predict breast cancer invasiveness with high accuracy.

5.2 Prostate carcinoma

Prostate carcinoma is the second most common cancer in men, with an incidence of 14% and a mortality of 7% [16]. Several multicenter studies have demonstrated the superiority of MRI-guided biopsy over standard ultrasound-guided biopsy (PRECISION [34], MRI-FIRST [35], and PROMIS [36]), so multiparametric MRI of the prostate (mpMRI) is currently mostly performed before biopsy

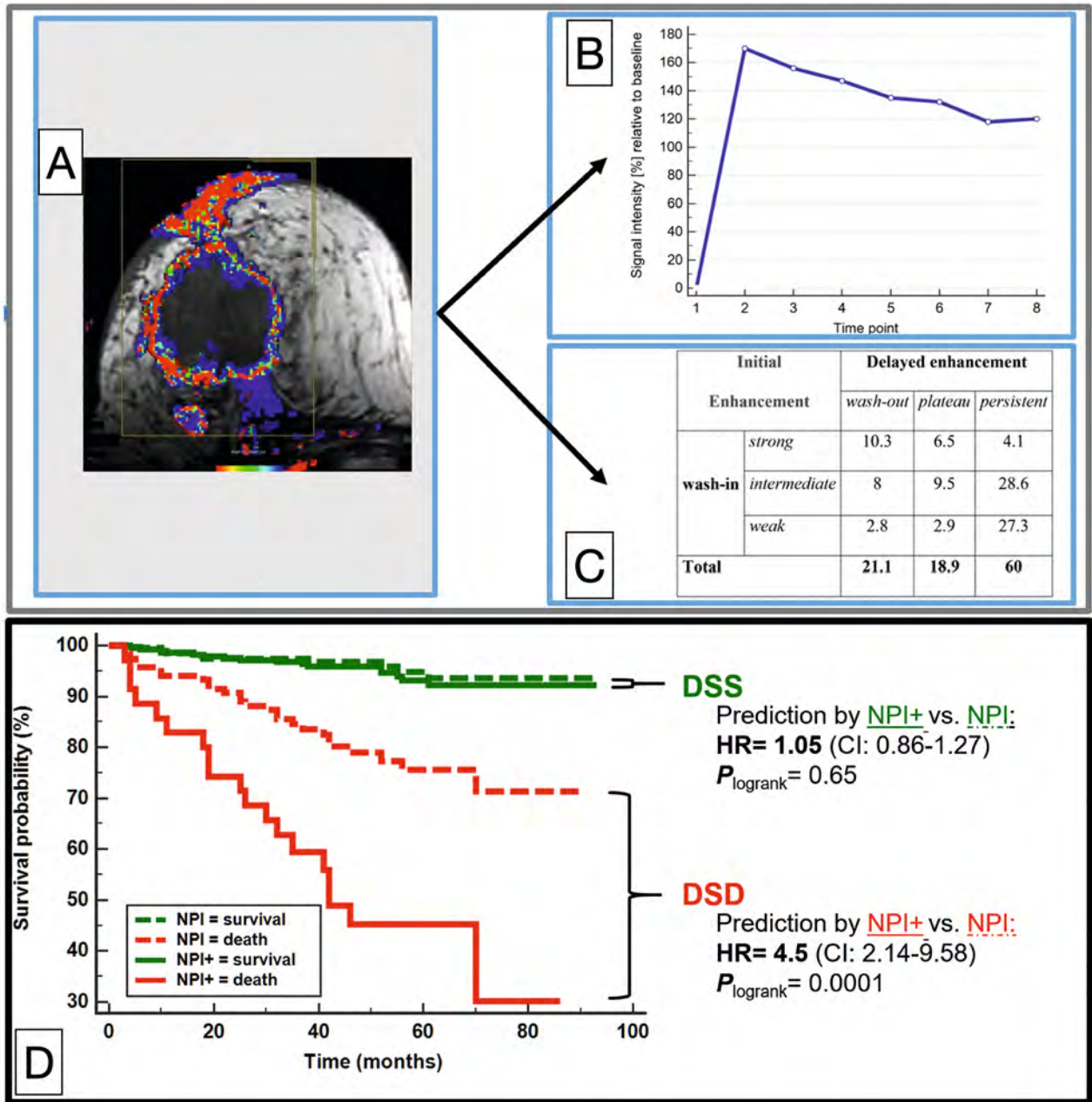
according to guidelines. Patients with low-grade prostate carcinoma are known to often not receive direct therapy, but are regularly monitored clinically regarding their laboratory values and also with MRI follow-up as part of active monitoring [37]. The soft tissue contrast of CT is not sufficient to show the tissue differences within the prostate for adequate diagnosis of prostate carcinoma [38]. In the context of detecting biochemical recurrence, CT is often used for molecular imaging of prostate specific membrane antigen (PSMA) as a hybrid technique (PET/CT). The two most common methods of prostate imaging are ultrasound and mpMRI, with mpMRI currently having the highest sensitivity.

Conventional ultrasound is well suited to visualize the prostate boundaries and prostate volume. However, internal contrast is not sufficient for detecting tumor tissue [38]. Several recent techniques such as super-resolution ultrasound, ultrafast Doppler sonographic techniques, ultrasound elastography, KM-enhanced sonography (CEUS) and histoscanning have coined the term multiparametric ultrasound (mpUS) and raised the sensitivity [39]. However, a randomized controlled trial of 306 patients demonstrated superiority of mpMRI [40]. Therefore, the following focuses primarily on the QIB of mpMRI:

According to the Prostate Imaging Reporting & Data System version 2.1 (PI-RADS) classification, a lesion size of 1.5 cm or larger is used as a criterion for the PI-RADS 5 category. However, this measurement is determined in different sequences depending on the prostate zone, i. e., each on the primary sequence, i. e., T2w for transition zone and DWI for peripheral zone [41]. Size measurement is an important element of both baseline and follow-up studies in this regard. The size of a tumor lesion correlates with the likelihood of disease progression during active monitoring [42], extraprostatic extension, lymph node metastases, and ultimately survival [43], and is also part of the PI-RADS system with a threshold of 15 mm.

Currently, mpMRI consists of three components: T2-weighted imaging, diffusion-weighted imaging (DWI), and DCE MRI. (► **Fig. 3**). DCE MRI provides information on tumor neovascularization. While the PI-RADS version v1 [44] still used the curve progression of DCE MRI semi-quantitatively, the significance has decreased in subsequent PI-RADS versions. Currently (PI-RADS v2.1), only visual and qualitative estimation of early BM uptake compared to surrounding tissue is considered [41]. QIBs derived from heuristic quantitative DCE parameters, such as time to peak (TTP), are being investigated in studies [45], but have at times not found their way into routine clinical practice. The usefulness of DCE MRI is controversial, and some studies attribute it to only a minor contribution to the diagnostic statement [44], although it currently remains an integral part of mpMRI. A recent retrospective quantitative study of mpMRI directly contrasted the value and showed superiority of ADC over DCE MRI parameters [46].

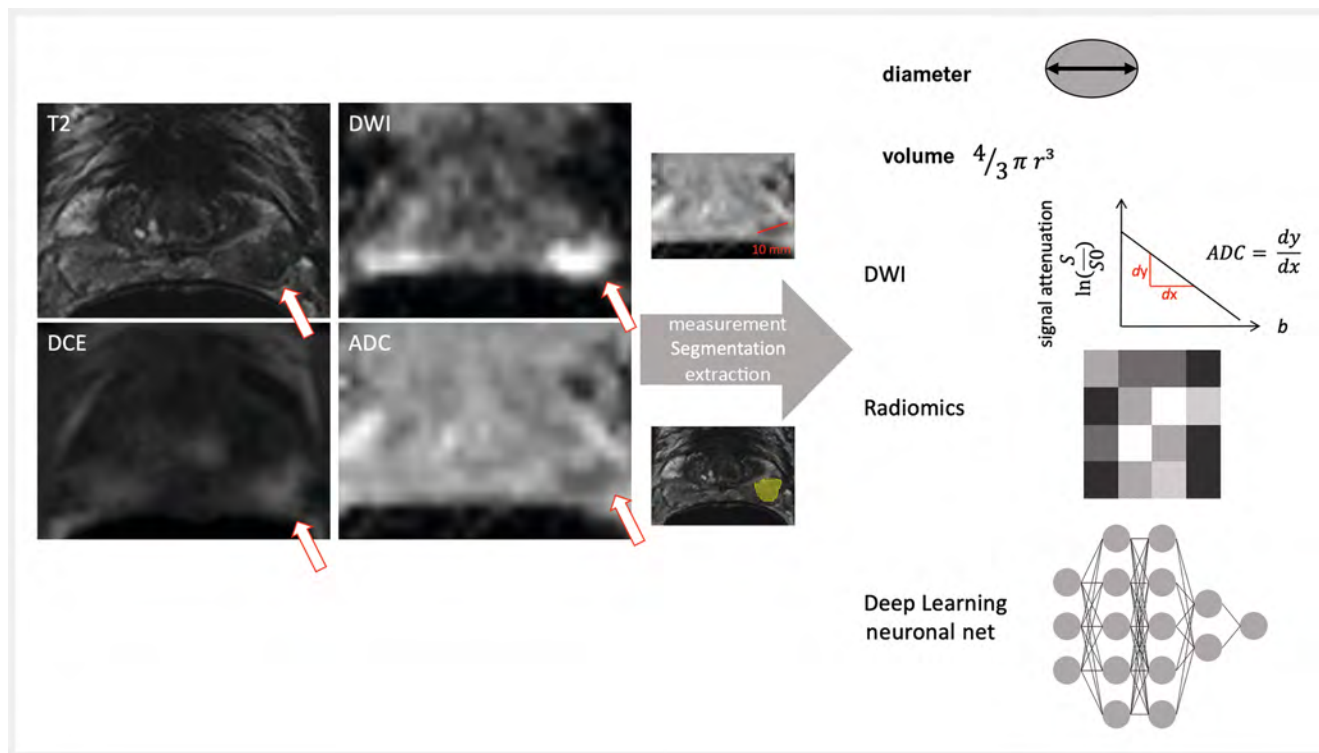
MR spectroscopy (MRS) was traditionally used and was also a component of prostate mpMRI in PI-RADS v1 [44], but is now not routinely performed because of the high expertise required, the time required, and the high frequency of limited data quality. Among the many other MR contrasts investigated in research, MRI relaxometry or MR fingerprinting [47] should be mentioned, although their diagnostic value has not yet been adequately investigated.



► **Fig. 2** Integration of multiparametric data for risk profiling of breast carcinoma in a clinical example (A–C). Corresponding Kaplan-Meier curves (D) illustrate the improvement in risk profiling compared with an established prognostic index (Nottingham prognostic Index: NPI). Above (A–C) the volumetric analysis of the tumor in a representative slice, where the target structure is defined by a rectangle (A). Multi-parametric MRI allows analysis of the vital portions of the tumor. These are marked in color. Each voxel of the tumor is further characterized by means of a signal intensity/time curve (B). Thus, volumetric analysis of vascularization of the vital tumor is possible (simplified in C). Bottom (D) the improvement of risk profiling by integrating multiparametric MRI data into the NPI. This combined model is called NPI+. Note the optimized identification of high-risk patients using NPI+, which was significantly superior to the established prognostic index (adopted from [53]).

From the current clinical and research experience, the quantitative ADC value should be mentioned as probably the best-studied QIB of the prostate [47], which correlates with the histological grade. Modifications of the mathematical ADC model with the use of additional b values have also been investigated, for example, in the context of intravoxel incoherent motion (IVIM) [48] and kurtosis

imaging [49]. The well-known problem here remains the reproducibility of the results, as it is generally known that ADC values depend on the MRI scanner used and the MRI sequence. The benefit of DWI images with b-values exceeding the standard (approx. 1400 s/mm², also possible calculated by extrapolation) has been refuted in studies [46]. This indicates that candidates for new quantitative biomar-



► **Fig. 3** Example of a 66-year-old patient with a radiographic PI-RADS 4 lesion of the basal lateral peripheral zone on the left with a prostate-specific antigen value of 5.7 ng/ml. A carcinoma with a Gleason score of 7 was confirmed by biopsy. The illustration demonstrates the possible steps that can be included in the generation of imaging biomarkers and a small selection of the biomarkers mentioned in the text.

kers need to be carefully screened in studies for their contribution compared with established criteria.

The extraction and evaluation of hundreds of quantitative, fixed parameters in terms of radiomics analysis, as already mentioned, have also been used in the diagnosis of prostate carcinoma in the context of studies [50]. However, a serious restriction here is also the limited reproducibility and repeatability of these basic parameters [51]. In recent years, the trend has evolved away from these established parameters towards neural networks that independently “learn” the parameters. Such AI tools for the prostate already exist and some are commercially available with CE marking. A website of the Radboud University Medical Center (Netherlands) [AI for Radiology – an implementation guide] lists commercial AI software, which is supposed to provide assistance in report generation, segmentation and tumor detection. For the AI tools listed, there is currently insufficient clinical evidence that they have comparable performance to radiologists. Only individual studies currently show comparable performance [52]. However, larger validation studies, especially with multi-center data are still scarce and needed in the future.

6. Summary and outlook

The quantification of multimodal and multiparametric imaging biomarkers allows a standardized approach to record physiological and pathophysiological processes. Due to the large number of imaging biomarkers, AI methods are increasingly being used to

develop ML algorithms that allow specific diagnostic conclusions to be made.

The integration of parameters at the morphological, functional, metabolic, and molecular levels is important because complementary information from disease processes is thus identified. By combining imaging parameters of different qualities, it is possible to obtain the most comprehensive view possible of tissue changes, such as in breast and prostate carcinoma. In these tumors, in addition to tumor size and extension (morphological level), time-varying parameters such as blood flow and diffusion (functional or metabolic level) and ultimately the expression of disease-specific proteins such as PSMA (molecular level) play an essential role.

We are currently observing a steady improvement of pattern recognition methods for (semi-) automated detection of target organs and regions. In the future, these advances will lead to broader integration of imaging biomarkers into clinical practice. This, in turn, will significantly increase the acceptance and value of imaging biomarkers in the coming years.

Conflict of Interest

The authors declare that they have no conflict of interest.

References

- [1] European Society of Radiology. ESR Statement on the Validation of Imaging Biomarkers. *Insights Imaging* 2020; 4 (1): 76

- [2] deSouza NM, van der Lugt A, Deroose CM et al. Standardised lesion segmentation for imaging biomarker quantitation: a consensus recommendation from ESR and EORTC. *Insights Imaging* 2022; 13: 159
- [3] Alberich-Bayarri A, Neri E, Martí-Bonmatí L. Imaging biomarkers and imaging biobanks. In: Ranschaert E, Morozov S, Algra P, Hrsg. *Artificial Intelligence in Medical Imaging: Opportunities, Applications and Risks*. Springer Nature; 2019: 119–126. doi:10.1007/978-3-319-94878-2
- [4] Pfaehler E, Burggraaff C, Kramer G et al. PET segmentation of bulky tumors: Strategies and workflows to improve inter-observer variability. *PLoS One* 2020; 15 (3): e0230901
- [5] Yip SSF, Parmar C, Blezek D et al. Application of the 3D slicer chest imaging platform segmentation algorithm for large lung nodule delineation. *PLoS One* 2017; 12 (6): e0178944
- [6] Gillies RJ, Kinahan PE, Hricak H. Radiomics: Images Are More than Pictures, They Are Data. *Radiology* 2016; 278 (2): 563–577
- [7] Patel JL, Goyal RK. Applications of artificial neural networks in medical science. *Curr Clin Pharmacol* 2007; 2 (3): 217–226
- [8] Han T, Pedersoli KJ, Zimmermann F et al. Image prediction of disease progression for osteoarthritis by style-based manifold extrapolation. *Nat Mach Intell* 2022; 4: 1029–1039
- [9] Ellmann S, Wenkel E, Dietzel M et al. Implementation of machine learning into clinical breast MRI: Potential for objective and accurate decision-making in equivocal breast lesions. *PLoS One* 2020; 15 (1): e0228446
- [10] Ellmann S, Schlicht M, Dietzel M et al. Computer-aided diagnosis in multiparametric MRI of the prostate: An open-access online tool for lesion classification with high accuracy. *Cancers* 2020; 12 (9): E2366
- [11] Molyneux PD, Miller DH, Filippi M et al. Visual analysis of serial T2-weighted MRI in multiple sclerosis: intra- and interobserver reproducibility. *Neuroradiology* 1999; 41 (12): 882–888
- [12] Barrington SF, Mikhael NG, Kostakoglu L et al. Role of imaging in the staging and response assessment of lymphoma: consensus of the International Conference on Malignant Lymphomas Imaging Working Group. *J Clin Oncol* 2014; 32 (27): 3048–3058
- [13] Chernyak V, Fowler KJ, Kamaya A et al. Liver Imaging Reporting and Data System (LI-RADS) Version 2018: Imaging of Hepatocellular Carcinoma in At-Risk Patients. *Radiology* 2018; 289 (3): 816–830
- [14] Eisenhauer EA, Therasse P, Bogaerts J et al. New response evaluation criteria in solid tumours: revised RECIST guideline (version 1.1). *Eur J Cancer* 2009; 45 (2): 228–247
- [15] Jiang Y, You K, Qiu X et al. Tumor volume predicts local recurrence in early rectal cancer treated with radical resection: A retrospective observational study of 270 patients. *Int J Surg* 2018; 49: 68–73
- [16] Sung H, Ferlay J, Siegel RL et al. Global Cancer Statistics 2020: GLOBOCAN Estimates of Incidence and Mortality Worldwide for 36 Cancers in 185 Countries. *CA Cancer J Clin* 2021; 71 (3): 209–249
- [17] Mann RM, Cho N, Moy L. Breast MRI: State of the Art. *Radiology* 2019; 292 (3): 520–536
- [18] Coffey K, Jochelson MS. Contrast-enhanced mammography in breast cancer screening. *Eur J Radiol* 2022; 156: 110513
- [19] Dietzel M, Trimboli RM, Zanardo M et al. The potential of predictive and prognostic breast MRI (P2-bMRI). *Eur Radiol Exp* 2022; 6 (1): 42
- [20] McCormack VA, dos Santos Silva I. Breast density and parenchymal patterns as markers of breast cancer risk: a meta-analysis. *Cancer Epidemiol Biomarkers Prev* 2006; 15 (6): 1159–1169
- [21] Bakker MF, de Lange SV, Pijnappel RM et al. Supplemental MRI Screening for Women with Extremely Dense Breast Tissue. *N Engl J Med* 2019; 381 (22): 2091–2102
- [22] Mann RM, Athanasiou A, Baltzer PAT et al. Breast cancer screening in women with extremely dense breasts recommendations of the European Society of Breast Imaging (EUSOBI). *Eur Radiol* 2022; 32 (6): 4036–4045
- [23] Kontos D, Winham SJ, Oustimov A et al. Radiomic Phenotypes of Mammographic Parenchymal Complexity: Toward Augmenting Breast Density in Breast Cancer Risk Assessment. *Radiology* 2019; 290 (1): 41–49
- [24] Pinto Dos Santos D, Dietzel M, Baessler B. A decade of radiomics research: are images really data or just patterns in the noise? *Eur Radiol* 2021; 31 (1): 1–4
- [25] Gamble P, Jaroensri R, Wang H et al. Determining breast cancer biomarker status and associated morphological features using deep learning. *Commun Med* 2021; 1: 14
- [26] Baltzer P, Mann RM, Lima M et al. Diffusion-weighted imaging of the breast—a consensus and mission statement from the EUSOBI International Breast Diffusion-Weighted Imaging working group. *Eur Radiol* 2020; 30 (3): 1436–1450
- [27] Dietzel M, Baltzer PAT. How to use the Kaiser score as a clinical decision rule for diagnosis in multiparametric breast MRI: a pictorial essay. *Insights Imaging* 2018; 9 (3): 325–335
- [28] Tofts PS, Brix G, Buckley DL et al. Estimating kinetic parameters from dynamic contrast-enhanced T(1)-weighted MRI of a diffusible tracer: standardized quantities and symbols. *J Magn Reson Imaging* 1999; 10 (3): 223–232
- [29] Nicolini A, Ferrari P, Duffy MJ. Prognostic and predictive biomarkers in breast cancer: Past, present and future. *Semin Cancer Biol* 2018; 52 (1): 56–73
- [30] Marinovich ML, Macaskill P, Irwig L et al. Agreement between MRI and pathologic breast tumor size after neoadjuvant chemotherapy, and comparison with alternative tests: individual patient data meta-analysis. *BMC Cancer* 2015; 15: 662
- [31] Dietzel M, Schulz-Wendtland R, Ellmann S et al. Automated volumetric radiomic analysis of breast cancer vascularization improves survival prediction in primary breast cancer. *Sci Rep* 2020; 10 (1): 3664
- [32] Baltzer PAT, Krug KB et al. Evidence-Based and Structured Diagnosis in Breast MRI using the Kaiser Score. *Fortschr Röntgenstr* 2022; 194 (11): 1216–1228
- [33] Clauser P, Krug B, Bickel H et al. Diffusion-weighted Imaging Allows for Downgrading MR BI-RADS 4 Lesions in Contrast-enhanced MRI of the Breast to Avoid Unnecessary Biopsy. *Clin Cancer Res* 2021; 27 (7): 1941–1948
- [34] Kasivisvanathan V, Rannikko AS, Borggi M et al. MRI-Targeted or Standard Biopsy for Prostate-Cancer Diagnosis. *N Engl J Med* 2018; 378: 1767–1777
- [35] Rouviere O, Puech P, Renard-Penna R et al. Use of prostate systematic and targeted biopsy on the basis of multiparametric MRI in biopsy-naïve patients (MRI-FIRST): a prospective, multicentre, paired diagnostic study. *Lancet Oncol* 2019; 20: 100–109
- [36] Ahmed HU, El-Shater Bosaily A, Brown LC et al. Diagnostic accuracy of multi-parametric MRI and TRUS biopsy in prostate cancer (PROMIS): a paired validating confirmatory study. *Lancet* 2017; 389: 815–822
- [37] Cooperberg MR, Carroll PR, Klotz L. Active surveillance for prostate cancer: progress and promise. *J Clin Oncol* 2011; 29: 3669–3676
- [38] Hegde JV, Mulkern RV, Panych LP et al. Multiparametric MRI of prostate cancer: an update on state-of-the-art techniques and their performance in detecting and localizing prostate cancer. *J Magn Reson Imaging* 2013; 37: 1035–1054
- [39] Kaneko M, Lenon MSL, Storino Ramacciotti L et al. Multiparametric ultrasound of prostate: role in prostate cancer diagnosis. *Ther Adv Urol* 2022; 14. doi:10.1177/17562872221145625
- [40] Grey ADR, Scott R, Shah B et al. Multiparametric ultrasound versus multiparametric MRI to diagnose prostate cancer (CADMUS): a prospective, multicentre, paired-cohort, confirmatory study. *Lancet Oncol* 2022; 23: 428–438
- [41] Turkbey B, Rosenkrantz AB, Haider MA et al. Prostate Imaging Reporting and Data System Version 2.1: 2019 Update of Prostate Imaging Reporting and Data System Version 2. *Eur Urol* 2019; 76: 340–351

- [42] Caglic I, Sushentsev N, Gnanapragasam VJ et al. MRI-derived PRECISE scores for predicting pathologically-confirmed radiological progression in prostate cancer patients on active surveillance. *Eur Radiol* 2021; 31: 2696–2705
- [43] Knoedler JJ, Karnes RJ, Thompson RH et al. The association of tumor volume with mortality following radical prostatectomy. *Prostate Cancer Prostatic Dis* 2014; 17: 144–148
- [44] Barentsz JO, Richenberg J, Clements R et al. ESUR prostate MR guidelines 2012. *Eur Radiol* 2012; 22: 746–757
- [45] Breit HC, Block TK, Winkel DJ et al. Revisiting DCE-MRI: Classification of Prostate Tissue Using Descriptive Signal Enhancement Features Derived From DCE-MRI Acquisition With High Spatiotemporal Resolution. *Invest Radiol* 2021; 56: 553–562
- [46] Tavakoli AA, Hielscher T, Badura P et al. Contribution of Dynamic Contrast-enhanced and Diffusion MRI to PI-RADS for Detecting Clinically Significant Prostate Cancer. *Radiology* 2023; 306: 186–199
- [47] Panda A, O'Connor G, Lo WC et al. Targeted Biopsy Validation of Peripheral Zone Prostate Cancer Characterization With Magnetic Resonance Fingerprinting and Diffusion Mapping. *Invest Radiol* 2019; 54: 485–493
- [48] Pang Y, Turkbey B, Bernardo M et al. Intravoxel incoherent motion MR imaging for prostate cancer: an evaluation of perfusion fraction and diffusion coefficient derived from different b-value combinations. *Magn Reson Med* 2013; 69: 553–562
- [49] Tavakoli AA, Kuder TA, Tichy D et al. Measured Multipoint Ultra-High b-Value Diffusion MRI in the Assessment of MRI-Detected Prostate Lesions. *Invest Radiol* 2021; 56: 94–102
- [50] Bonekamp D, Kohl S, Wiesenfarth M et al. Radiomic Machine Learning for Characterization of Prostate Lesions with MRI: Comparison to ADC Values. *Radiology* 2018; 289: 128–137
- [51] Zwanenburg A, Vallières M, Abdalah MA et al. The Image Biomarker Standardization Initiative: Standardized Quantitative Radiomics for High-Throughput Image-based Phenotyping. *Radiology* 2020; 295: 328–338
- [52] Zhang KS, Schelb P, Netzer N et al. Pseudoprospective Paraclinical Interaction of Radiology Residents With a Deep Learning System for Prostate Cancer Detection: Experience, Performance, and Identification of the Need for Intermittent Recalibration. *Invest Radiol* 2022; 57: 601–612
- [53] Dietzel M, Clauser P, Kapetas P et al. Images Are Data: A Breast Imaging Perspective on a Contemporary Paradigm. *Fortschr Röntgenstr* 2021; 193 (8): 898–908