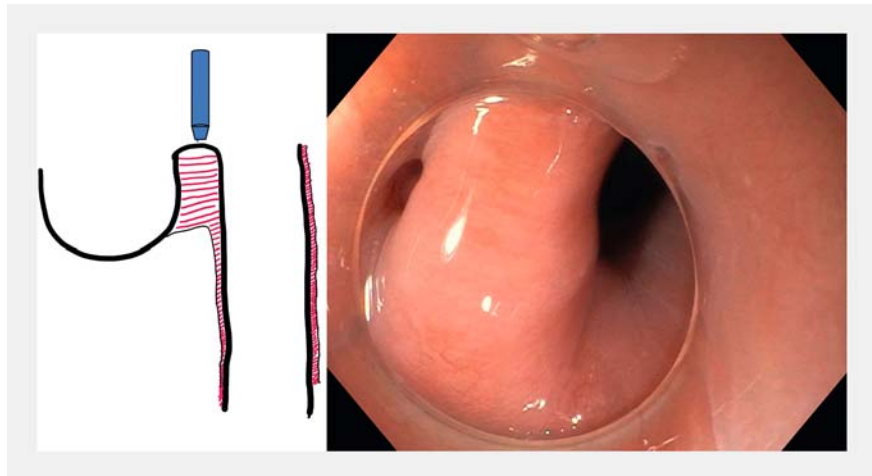


## Peroral endoscopic myotomy for Zenker's diverticulum without tunneling

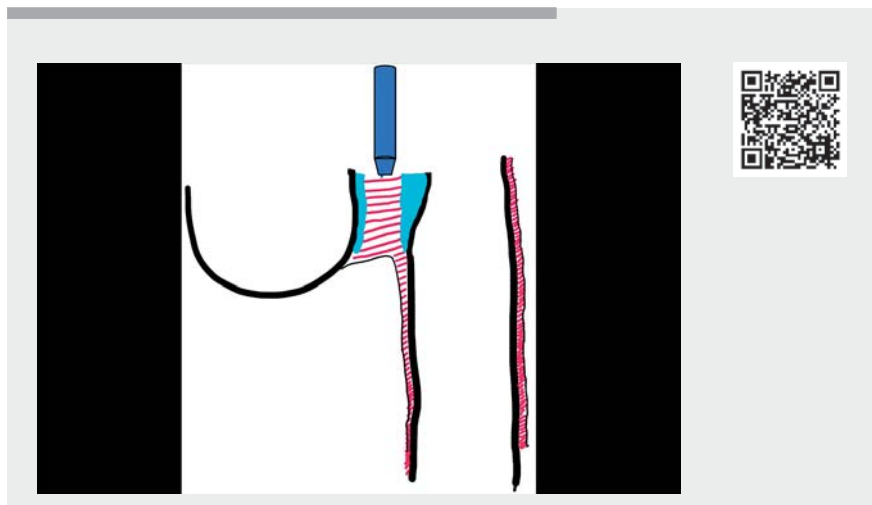


Peroral endoscopic myotomy (POEM) is an increasingly adopted strategy for the treatment of Zenker's diverticulum (► **Fig. 1**). The Z-POEM technique allows for a deep incision of the cricopharyngeal muscle up to its transition to the esophageal muscle layer, and therefore more complete myotomy than direct diverticulotomy. Several modifications of the standard technique have been demonstrated [1–3]. The mucosal incision is most commonly performed over the septum, and two tunnels are created along the cricopharyngeal muscle. Next, the muscle is transected. Recently, we have described a variation of this technique with the creation of a single tunnel instead of two, to shorten the duration of the procedure [3]. However, we have now shifted to a novel approach that obviates the need for double or single tunneling (► **Video 1**).

After the initial mucosal incision, both submucosal sides of the septum are lifted, with a mixture of hydroxyethyl starch and indigo carmine. Then we proceed to direct myotomy of the septum (► **Fig. 2**). The distended submucosal space on both sides of the septum functions as a protective cushion and prevents mucosal injury. After 1 cm of septotomy, further progression becomes much easier due to the increased space created by the partial myotomy (► **Fig. 3**). Further submucosal injections are provided as needed in order to maintain protective cushions on both sides. Myotomy is extended up to the proximal part, approximately 2 cm, of the esophageal muscle to reduce the risk of recurrence (► **Fig. 4**). Prior to endoscopic closure, it is important to examine for remaining intact muscle fibers at the proximal part of the septum (► **Fig. 5**). In our experience, this modification further shortens the duration of the procedure, with a median duration of 25 minutes, and is helpful where fibrosis is present from previous surgical interventions in the hypopharynx.



► **Fig. 1** Scheme and endoscopic view of a typical Zenker's diverticulum.



► **Video 1** Peroral endoscopic myotomy for Zenker's diverticulum without tunneling.

Endoscopy\_UCTN\_Code\_TTT\_1AO\_2AG

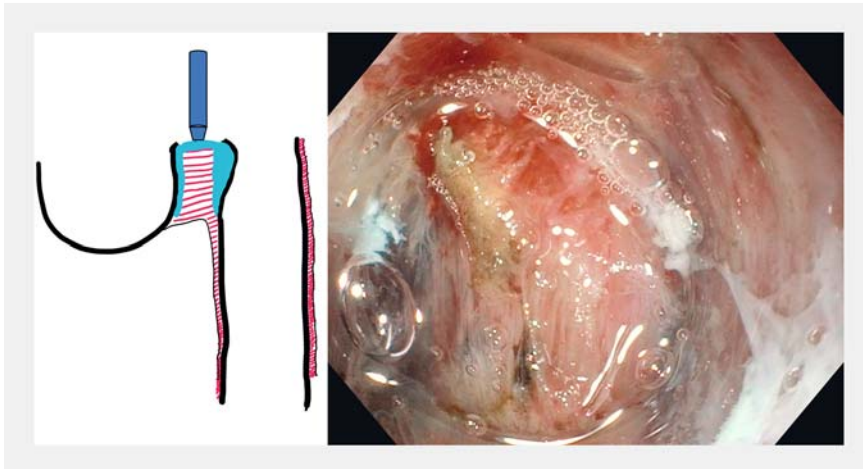
### The authors

Georgios Mavrogenis<sup>1</sup>, Fateh Bazerbachi<sup>2</sup>

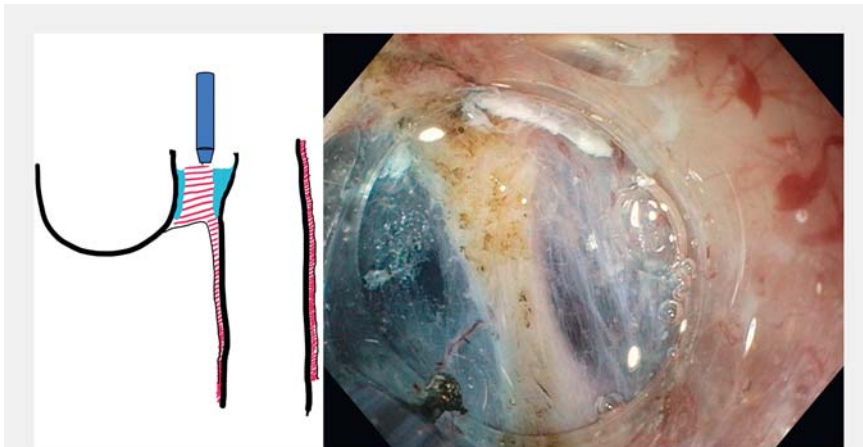
- 1 Unit of Hybrid Interventional Endoscopy, Department of Gastroenterology, Mediterraneo Hospital, Athens, Greece
- 2 CentraCare, Interventional Endoscopy Program, St. Cloud Hospital, St Cloud, Minnesota, USA

### Competing interests

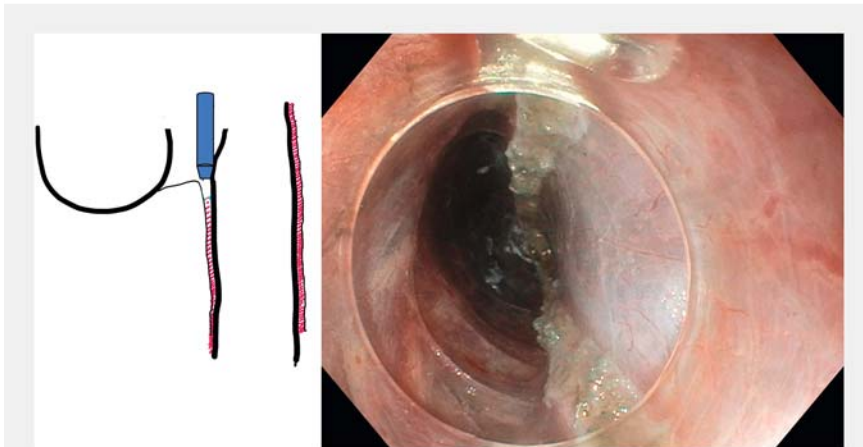
The authors declare that they have no conflict of interest.



► **Fig. 2** After mucosal incision, myotomy is performed. The submucosal space acts as a cushion protecting against mucosal injury.



► **Fig. 3** Myotomy without tunneling.



► **Fig. 4** Myotomy extended up to the level of the upper esophagus.

## Corresponding author

**Georgios Mavrogenis, MD**

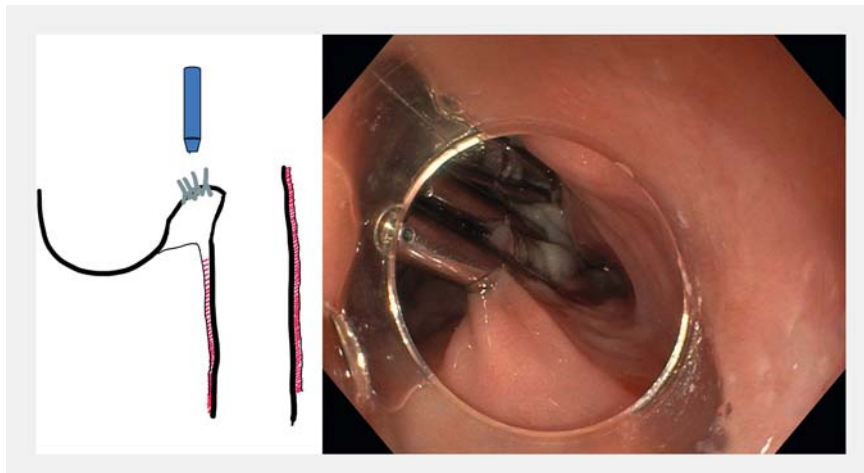
Unit of Hybrid Interventional Endoscopy,  
Department of Gastroenterology,  
Mediterraneo Hospital, Ilias 8-12, Glyfada  
16675, Athens, Greece  
mavrogenis@gmail.com

## References

- [1] Li QL, Chen WF, Zhang XC et al. Submucosal tunneling endoscopic septum division: a novel technique for treating Zenker's diverticulum. *Gastroenterology* 2016; 151: 1071–1074
- [2] Mavrogenis G, Tsevgas I, Zachariadis D et al. Mucosotomy at the top of the septum facilitates tunneling and clipping during peroral endoscopic myotomy for Zenker's diverticulum (Z-POEM). *Ann Gastroenterol* 2020; 33: 101
- [3] Mavrogenis G, Tsevgas I, Zachariadis D et al. Single tunnel Z-POEM. *Endoscopy* 2023; 55: E604–E605

## Citation Format

*Endoscopy* 2023; 55: E946–E948.  
doi: 10.1055/a-2127-7402.



► **Fig. 5** Closure of the mucosotomy.

## Bibliography

Endoscopy 2023; 55: 1148–1150

DOI 10.1055/a-2185-4157

ISSN 0013-726X

© 2023. The Author(s).

This is an open access article published by Thieme under the terms of the Creative Commons Attribution License, permitting unrestricted use, distribution, and reproduction so long as the original work is properly cited.

(<https://creativecommons.org/licenses/by/4.0/>)

Georg Thieme Verlag KG, Rüdigerstraße 14,  
70469 Stuttgart, Germany

