Article published online: 2023-12-21

Endoscopic closure of a refractory urethroanal fistula using an innovative wound closure device

OPEN ACCESS

Gastrointestinal (GI) fistula is a rare chronic disease that affects the quality of life of patients and represents a real therapeutic challenge, with frequent recurrences [1]. Endoscopic management of GI fistulas combines both endoscopic submucosal dissection (ESD) and mechanical closure of the orifice [2]. We recently reported that the strategy of fistula endoscopic submucosal dissection with clip closure (FESDC) is effective and safe for permanent closure of GI fistulas [3], including in the exceptional cases where an aortoesophageal fistula has occurred [4]. In the case of anal fistulas, mechanical closure remains the greatest challenge because of the proximity of the anal sphincter, which does not allow effective closure using standard or over-the-scope clips.

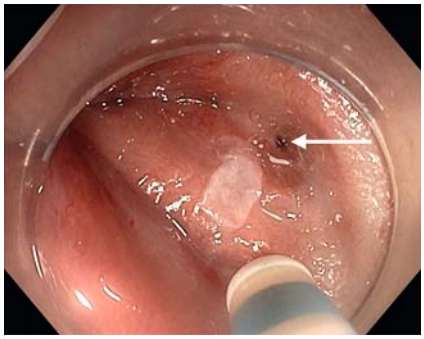

▶ **Fig. 1** Endoscopic view of a urethroanal fistula (arrow).

We herein report the case of a 29-year-old man referred for a refractory urethroanal fistula with an existing intermediate imperforate anus requiring multiple surgical and endoscopic procedures. We first performed the endoscopic examination without anesthetic. The fistula was visualized on the posterior wall of the anal verge during micturition by the patient, the bladder having first been filled with blue dye using a urinary catheter (▶ **Fig. 1**). After ESD of the internal orifice of the fistula, we decided to use the new Sutuart flexible needle holder (Olympus, Tokyo, Japan) [5] with a barbed suture (Medtronic, USA) to suture together the edges of the dissected fistula tract (▶ **Fig. 2**, ▶ **Video 1**). This novel device allowed us to suture under endoscopic control in a tight area using barbed suture (▶ **Fig. 3**). Technical success was achieved, defined by tight sealing of the orifice confirmed by opacification at the end of the procedure without any urine leakage (▶ **Fig. 4**). No adverse event was

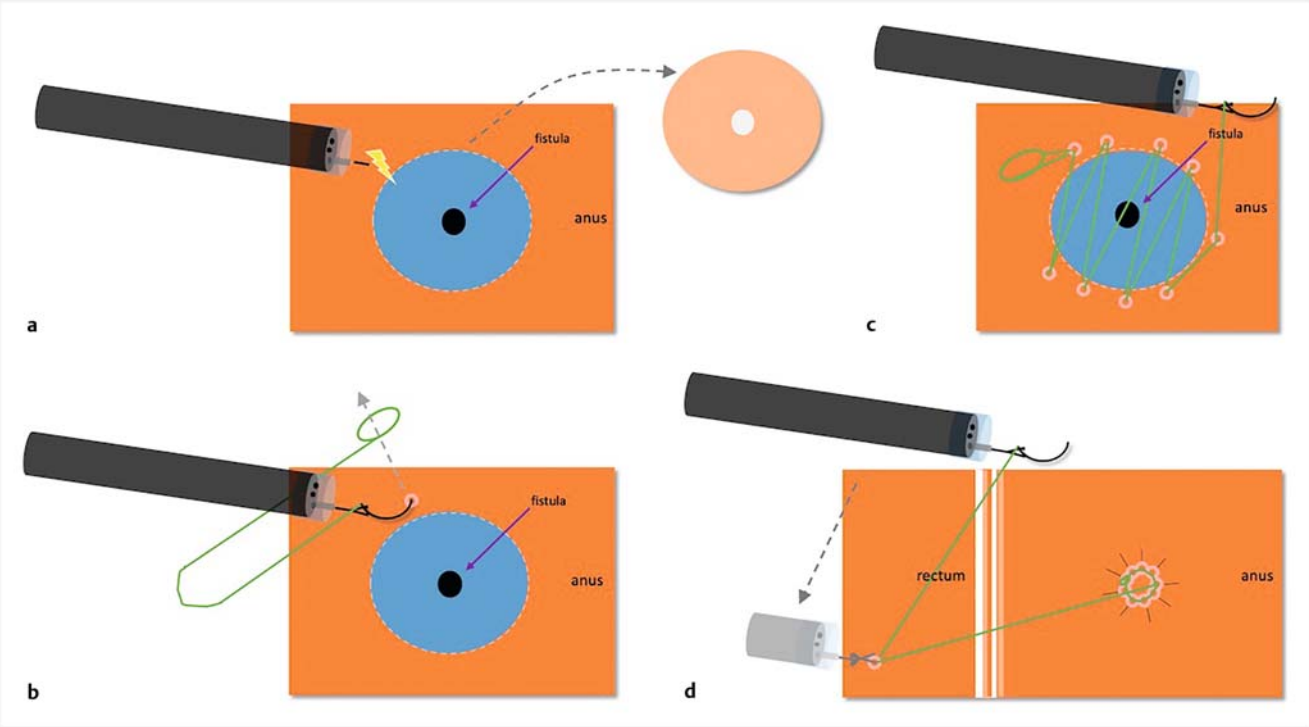

▶ **Fig. 2** Schematic of endoscopic closure of the refractory urethroanal fistula using an innovative wound closure device (view from above). **a** The mucosal flap is completely dissected. **b** The needle is passed through the preformed anchored loop to begin apposition of the edges of the fistula orifice. **c** The edges of the fistula orifice are further approximated using a continuous suture path. **d** The device is anchored in the rectum and the suture finally cut.



▶ **Fig. 3** **a** Sutuart needle holder in the open position. **b** V-Loc wound closure device with dual-angle cut and barbing pattern, in position in the needle holder.

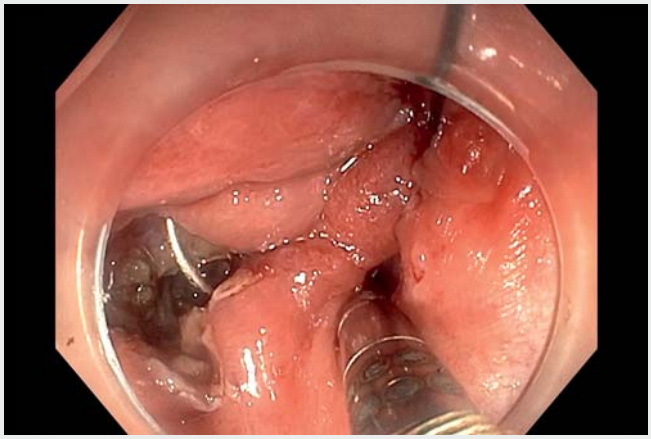

Video 1 Endoscopic closure of a refractory urethroanal fistula using an innovative wound closure device.

reported. Suturing techniques with this new needle holder could be added to the range of existing closure methods after ESD of gastrointestinal fistulas.

Endoscopy_UCTN_Code_TTT_1AQ_2AG

Competing interests

The authors declare that they have no conflict of interest.

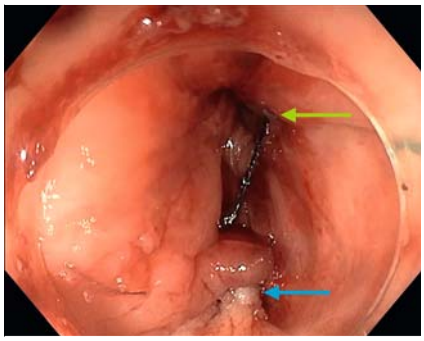

▶ **Fig. 4** Endoscopic view of the closed fistula after the procedure: the edges of the dissected fistula orifice have been apposed (blue arrow) and anchored in the rectum (green arrow) – endoscopic view.

The authors

Pierre Lafeuille[1], Jérôme Rivory[1], Alexandru Lupu[1], Elena de Cristofaro[2], Jean-Christophe Saurin[1], Florian Rostain[1], Mathieu Pioche[1]

1 Department of Endoscopy and Hepatogastroenterology, Pavillon L, Edouard Herriot Hospital, Lyon, France
2 Department of Systems Medicine, Gastroenterology and Endoscopy Unit, Tor Vergata University of Rome, Rome, Italy

Corresponding author

Pierre Lafeuille, MD
Endoscopy Unit, Digestive Diseases Department, Edouard Herriot Hospital Pavillon L, 5 Place d'Arsonval, 69437 Lyon Cedex, France
pierre.lafeuille@chu-lyon.fr

References

[1] Willingham FF, Buscaglia JM. Endoscopic management of gastrointestinal leaks and fistulae. Clin Gastroenterol Hepatol 2015; 13: 1714–1721. doi:10.1016/j.cgh.2015.02.010
[2] Bertrand G, Jacques J, Rivory J et al. Deep endoscopic submucosal dissection of a refractory tracheoesophageal fistula using clip-and-line traction: a successful closure. Endoscopy 2017; 49: 1278–1280. doi:10.1055/s-0043-119348
[3] Lafeuille P, Wallenhorst T, Lupu A et al. Endoscopic submucosal dissection combined with clip closure is effective for closure of gastrointestinal fistulas including those refractory to previous therapy. Endoscopy 2022; 54: 700–705. doi:10.1055/a-1641-7938

[4] Lafeuille P, Poincloux L, Rouquette O et al. Refractory aortoesophageal fistulas after aortic stenting successfully closed using endoscopic submucosal dissection with clip closure. Endoscopy 2023; 55: E292–E293. doi:10.1055/a-1974-9737
[5] Goto O, Sasaki M, Akimoto T et al. Endoscopic hand-suturing for defect closure after gastric endoscopic submucosal dissection: a pilot study in animals and in humans. Endoscopy 2017; 49: 792–797. doi:10.1055/s-0043-110668

Citation Format

Endoscopy 2023; 55: E1105–E1107, DOI 10.1055/a-2177-3695.

Bibliography

Endoscopy 2024; 56: 75–77
DOI 10.1055/a-2194-0305
ISSN 0013-726X
© 2023. The Author(s).

This is an open access article published by Thieme under the terms of the Creative Commons Attribution License, permitting unrestricted use, distribution, and reproduction so long as the original work is properly cited.
(https://creativecommons.org/licenses/by/4.0/)
Georg Thieme Verlag KG, Rüdigerstraße 14, 70469 Stuttgart, Germany