Thieme

Radial incision and cutting for post-esophageal endoscopic submucosal dissection stricture with prior perforation during dilation

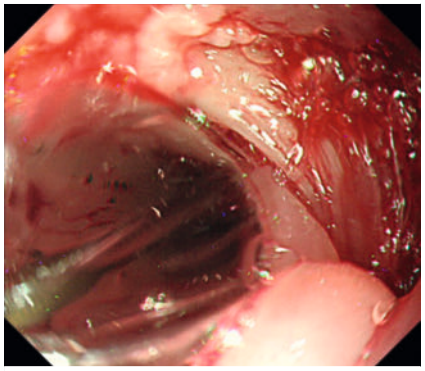

▶ **Fig. 1** Endoscopic image of the perforation during endoscopic balloon dilation.

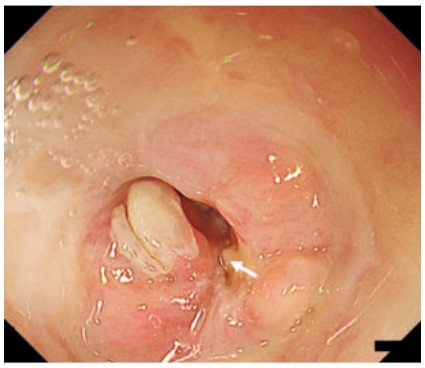

▶ **Fig. 2** Endoscopic image of the post-endoscopic submucosal dissection stricture before radial incision and cutting. The previous perforation site was identified at the 4 o'clock position near the edge of the mouth (arrow).

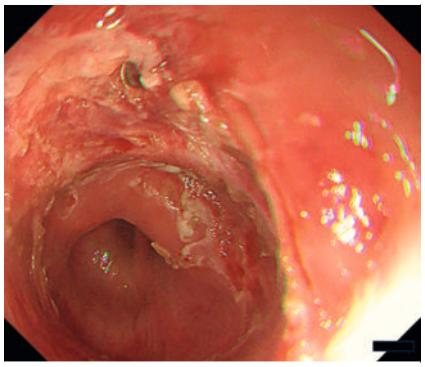

▶ **Fig. 3** Endoscopic image after radial incision and cutting reveals the head of a buried closing clip at the site of the prior perforation.

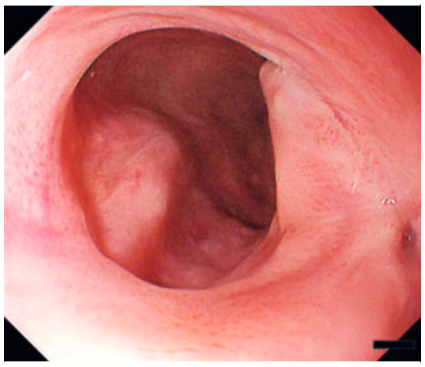

▶ **Fig. 4** Endoscopic image after 2 months of incision and cutting, displaying a scarred treated region with no signs of restenosis.

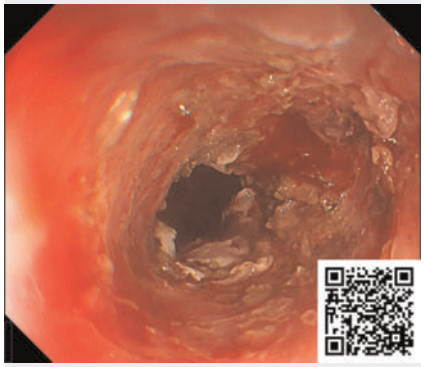

▶ **Video 1** Radial incision and cutting of refractory strictures with a prior perforation during balloon dilation after esophageal endoscopic submucosal dissection.

Extensive mucosal resection by esophageal endoscopic submucosal dissection (ESD) can lead to strictures [1]. Oral or locoregional steroid injections are used to prevent stenosis, but they are not effective in all cases [2, 3]. Endoscopic balloon dilation is the primary option for treating post-ESD strictures [4]; however, its applicability in previously perforated areas is challenging because of the risk of reperforation. Herein, we present a valuable case of radial incision and cutting for managing a post-ESD esophageal stricture with a prior perforation during endoscopic balloon dilation.

A 76-year-old man with widespread superficial esophageal squamous cell carcinoma underwent ESD, with resection extending over 80 % of the esophagus. Despite locoregional steroid injection, a stricture developed. A perforation occurred during endoscopic balloon dilation for stricture management (▶ **Fig. 1**). Following clip closure and fastening, the perforation healed, but restenosis ensued. Considering the risk of re-perforation, endoscopic balloon dilation was deemed unsuitable; therefore, we decided to perform radial incision and cutting to avoid surgical intervention.

The previous perforation site was at the 4 o'clock position near the mouth side edge (▶ **Fig. 2**); therefore, the incision was made from different directions using an electrosurgical knife (Dual-Knife J, KD-655Q; Olympus Optical Co., Tokyo, Japan). A cut was carefully made to avoid exposing the muscle layer. A fibrous tissue was removed and the lumen was enlarged until the anal edge of the stricture could be observed, allowing visualization of the direction for safe incision. The incision was advanced in a safe direction viewed from the anal side edge of the stricture to further enlarge the lumen. Finally, the stricture was sufficiently dilated to facilitate easy passage of the scope (▶ **Fig. 3**, ▶ **Video 1**). Additional oral and locoregional steroid injections were administered. After 2 months, a scarred radial incision and cutting region without restenosis was observed (▶ **Fig. 4**).

Endoscopy_UCTN_Code_TTT_1AO_2AH

Acknowledgement

We would like to thank Editage (www.editage.jp) for English language editing.

Conflict of Interest

The authors declare that they have no conflict of interest.

The authors

Jun Takada[1], Yukari Uno[1], Kentaro Kojima[1], Sachiyo Onishi[1], Masaya Kubota[1], Takashi Ibuka[1], Masahito Shimizu[1]

1 Department of Gastroenterology, Gifu University Graduate School of Medicine, Gifu, Japan

Corresponding author

Jun Takada, MD, PhD
Department of Gastroenterology, Gifu University Graduate School of Medicine, Yanagido 1-1, 501-1194 Gifu, Japan
takada.jun.h7@f.gifu-u.ac.jp

References

[1] Tsujii Y, Nishida T, Nishiyama O et al. Clinical outcomes of endoscopic submucosal dissection for superficial esophageal neoplasms: a multicenter retrospective cohort study. Endoscopy 2015; 47: 775–783. doi:10.1055/s-0034-1391844

[2] Hanaoka N, Ishihara R, Uedo N et al. Refractory strictures despite steroid injection after esophageal endoscopic resection. Endosc Int Open 2016; 4: E354–E359. doi:10.1055/s-0042-100903

[3] Zhou G, Yuan F, Cai J et al. Efficacy of prednisone for prevention of esophageal stricture after endoscopic submucosal dissection for superficial esophageal squamous cell carcinoma. Thorac Cancer 2017; 8: 489–494. doi:10.1111/1759-7714.12473

[4] Yamamoto Y, Kikuchi D, Nagami Y et al. Management of adverse events related to endoscopic resection of upper gastrointestinal neoplasms: Review of the literature and recommendations from experts. Dig Endosc 2019; 31: 4–20. doi:10.1111/den.13388

Bibliography

Endoscopy 2023; 55: E1238–E1239
DOI 10.1055/a-2208-5744
ISSN 0013-726X

Georg Thieme Verlag KG, Rüdigerstraße 14, 70469 Stuttgart, Germany