

# The value of AI-based analysis of fractional flow reserve of volume computed tomographically detected coronary artery stenosis with regard to their hemodynamic relevance

## Die Bedeutung KI-basierter Analyse fraktioneller Flussreserven computertomografisch nachgewiesener Coronararterienstenosen im Hinblick auf deren hämodynamische Relevanz

### Authors

Hans-Jürgen Noblé<sup>1</sup>, Nadine Mühlbauer<sup>1</sup>, Josef Ehling<sup>1</sup>, Paul Martin Bansmann<sup>2</sup>

### Affiliations

- 1 Department of Radiology, German Air Force Center of Aerospace Medicine, Cologne, Germany
- 2 Institute for Diagnostic and Interventional Radiology, Hospital Porz am Rhein, Cologne, Germany

### Keywords

hemodynamics/flow dynamics, angiocardiology, heart

received 27.9.2023

accepted 13.2.2024

published online 17.4.2024

### Bibliography

Fortschr Röntgenstr 2024; 196: 1253–1261

DOI 10.1055/a-2271-0887

ISSN 1438-9029

© 2024, Thieme. All rights reserved.

Georg Thieme Verlag KG, Rüdigerstraße 14, 70469 Stuttgart, Germany

### Correspondence

Dr. Nadine Mühlbauer

Department of Radiology, German Air Force Center of Aerospace Medicine, Flughafenstraße 1, 51447 Cologne, Germany

Tel.: +49/17 73 78 02 79

nadine.muehlbauer@gmail.com

### ABSTRACT

**Purpose** The aim of our work was to demonstrate the importance of artificial intelligence-based analysis of fractional flow reserves of computed tomographically detected coronary artery stenosis with regard to their hemodynamic relevance in patients with unclear chest pain and suspected stable coronary heart disease with a low to medium pre-test probability.

**Material and Methods** The collective of our retrospective analysis includes 63 patients in whom coronary artery stenosis was detected by volume computed tomographic examination in “one beat, whole heart” mode in the period from March to October 2022. In these patients, the fractional flow reserve

was also determined by computed tomography, which was modulated by the use of artificial intelligence.

**Results** The calculated values of the fractional flow reserve and the degrees of stenosis determined by computed tomography showed a moderate and significant negative correlation for all three coronary vascular territories (LAD/CX/RCA) (correlation coefficient  $\rho = 0.54/0.54/0.6$ ;  $p < 0.01$  respectively). In just over a third (37.6%) of all stenoses classified as high-grade by computed tomography, the assessment of hemodynamic relevance by calculating the fractional flow reserve deviated from the severity of the stenosis diagnosed by computed tomography, while the results in the peripheral areas “no stenosis/vascular occlusion” were 100% consistent in each case.

**Conclusion** The present results of this work illustrate that the calculation of the fractional flow reserve based on artificial intelligence as a supplement to volume computed tomography of the heart can make a decisive contribution to further therapy planning by increasing the specificity of the purely morphological method by the physiological aspect.

### Key Points

- Calculation of fractional flow reserve is a useful addition to computed tomography of the heart.
- It provides possibility to dispense with unnecessary further diagnostics by increasing specificity.
- The combination of both procedures leads to therapy optimization for patients.

### Citation Format

- Noblé H, Mühlbauer N, Ehling J et al. The value of AI-based analysis of fractional flow reserve of volume computed tomographically detected coronary artery stenosis with regard to their hemodynamic relevance. Fortschr Röntgenstr 2024; 196: 1253–1261

### ZUSAMMENFASSUNG

**Ziel** Ziel unserer Arbeit war der Nachweis der Bedeutung auf künstlicher Intelligenz basierender Analyse fraktioneller Flussreserven computertomografisch nachgewiesener Coronararterienstenosen im Hinblick auf deren hämodynamische Re-

levanz bei Patienten mit unklaren Brustschmerzen und dem Verdacht auf eine stabile koronare Herzerkrankung bei niedriger bis mittlerer Vortestwahrscheinlichkeit.

**Material und Methoden** Das Kollektiv unserer retrospektiven Analyse umfasst 63 Patienten, bei denen im Zeitraum von März bis Oktober 2022 mittels volumencomputertomografischer Untersuchung im „one beat, whole heart“-Modus eine Koronararterienstenose nachgewiesen wurde. Bei diesen Patienten erfolgte zudem eine computertomografisch gestützte Bestimmung der fraktionellen Flussreserve, die durch den Einsatz künstlicher Intelligenz moduliert wurde.

**Ergebnis** Die berechneten Werte der fraktionellen Flussreserve und die computertomografisch bestimmten Stenosegrade wiesen für alle drei koronaren Gefäßterritorien (LAD/CX/RCA) eine mittelstarke und signifikante negative Korrelation auf (Korrelationskoeffizient  $\rho = 0,54/0,54/0,6$ ;  $p < 0,01$  respektive). In über einem Drittel (37,6%) aller computertomografisch als hochgradig eingestuft Stenosen wich die Beurteilung der hämodynamischen Relevanz durch Berech-

nung der fraktionellen Flussreserve vom Schweregrad der computertomografisch diagnostizierten Stenose ab, während die Ergebnisse in den Randbereichen „keine Stenose/Gefäßverschluss“ jeweils zu 100% übereinstimmten.

**Schlussfolgerung** Die vorliegenden Ergebnisse dieser Arbeit veranschaulichen, dass die auf künstlicher Intelligenz basierende Berechnung der fraktionellen Flussreserve als Ergänzung zur Volumen-Computertomografie des Herzens durch Erhöhung der Spezifität des rein morphologischen Verfahrens um den physiologischen Aspekt einen entscheidenden Beitrag zur weiteren Therapieplanung leisten kann.

### Kernaussagen

- Die Berechnung fraktioneller Flussreserve ist eine sinnvolle Ergänzung der Computertomografien des Herzens.
- Sie ermöglicht Verzicht auf unnötige weiterführende Diagnostik durch Erhöhung der Spezifität.
- Die Kombination beider Verfahren führt zur Therapieoptimierung für die Patienten.

## Introduction

Coronary heart disease (CHD) is one of the most common causes of death among the group of cardiovascular deaths; in 2020, it was the most common cause of death in Germany [1, 2]. The technical development of cardiac computed tomography [3–5], particularly in the last 10 years, has led, given the appropriate findings, to its replacing invasive left heart catheterization, which entails increased health risks for patients [6–8], as the recognized gold standard for evaluating existing coronary artery stenoses; furthermore, in the current guidelines, computed tomography is now given a class 1 recommendation in patients with unclear chest pain and suspected stable CHD according to the pre-test probability (15–50%) of stenosing CHD [9]. Although cCTA, as a morphological procedure, has a high negative predictive value of 97–99% [10], there are limitations in the assessment of the physiological aspect, i. e., whether the coronary artery stenosis whose morphology is captured on CT is actually of clinical relevance – in other words, whether it has led to ischemia, and, if so, to what extent. The method of determining fractional flow reserves (FFR) can be used to better assess the functional relevance of the stenoses visualized graphically on CT, and thus to better plan further treatment, taking into account all of the restrictions and burdens this may entail for the patient as well as the resulting cost. This can now also be done as an AI-based non-invasive procedure (FFRCT) [11]. This procedure enables greater specificity than can be achieved with cCTA alone. In combination with the clinical aspects and the anatomical and morphological findings from cCTA, it makes a critical contribution to evaluating the relevance of stenoses, i. e., whether there is actual ischemia, and thus to determining the appropriate treatment [12]. Omitting an initial cardiac catheterization in favor of cCTA does not result in an increased risk of MACE (major adverse cardiac events); at the same time, it lowers the risk of major procedural complications [13]. Studies to this

effect have already been conducted in America; consequently, FFRCT is already part of American guidelines [14], and is at least mentioned in the ESC guidelines [15].

The objective of this study was to use retrospective AI-based analysis of fractional flow reserve based on volume computed tomography of the heart to investigate the possibility of assessing the hemodynamic relevance of coronary artery stenoses confirmed morphologically on CT in patients with stable CHD and stenosis ranging in degree from 40–90% using FFRCT, and, based on this analysis, the possibility of avoiding additional direct (invasive) examinations and adapting and optimizing the subsequent therapeutic procedure.

## Materials and Methods

### Patient Cohort

The patient cohort in our retrospective analysis comprises pseudonymized data from 63 patients at our hospital in Cologne, including 13 women (20.6%) and 50 men (79.4%) who underwent FFRCT between March and October 2022. The indication for this was established in accordance with the class 2a recommendation of the American guidelines (2021 AHA/ACC Chest Pain Guideline [9]) for patients in whom, in the context of diagnostic confirmation of unclear chest pain and suspicion of stable CHD, moderate to higher-grade (40–90%) stenosis had been detected by means of cCTA in at least one of the three major coronary arteries, LAD, CX, or RCA; for this purpose we classified the degree of stenosis according to the classification recommendation of the AHA as 0 = no stenosis (< 25%), 1 = mild stenosis (25–50%), 2 = moderate stenosis (50–75%), 3 = severe stenosis (75–90% and > 90%), and 4 = complete vessel occlusion (100%). Patients who presented with unstable angina or acute coronary syndrome were excluded from the study and received further treatment in accordance with

the guidelines relating to their clinical picture [9]. As FFRCT and cardiac CT are not (yet) covered by health insurance in the context of diagnosing stable CHD, our patient cohort only includes direct payers and private patients.

## The Computed Tomography Scanner

The cCTA datasets were reconstructed according to routine clinical practice using DLIR (TrueFidelity from GE Healthcare) at high (DLIR-H) levels (using HD kernels). The scanning parameters were as follows: 100 kVp tube voltage, a noise index of 37.8, 256 × 0.625 mm detector collimation with dynamic focal spot imaging, and a gantry rotation time of 230 ms. The protocol for CM administration was carried out as follows: 70 mL of CM at a flow rate of 6 mL/s, followed by 40 mL of NaCl at a flow rate of 3.5 mL/s.

## The Software

The technology for obtaining FFRCT was provided by HeartFlow, a company based in Mountain View, California that uses state-of-the-art AI technology in the field of image analysis. With reference to the multicenter study by Nørgaard et al. from 2014 [12] in which FFRCT calculations obtained from cCTA, called FFRCT, were compared to the invasive FFRCT used as the reference standard, the manufacturer indicates an accuracy of 86 % for its FFRCT calculations [11]. The procedure is standardized. Previously described algorithms are used to create an individual digital model of the coronary arteries of the respective patient; this is then checked and, if necessary, revised by appropriately trained analysts. The final result is a color digital 3D model of the coronary arteries, which is used to visualize the relevance of stenoses by restricting blood flow.

According to studies, an FFR value of <0.75 reliably indicates hemodynamically relevant stenosis, while a value >0.8 excludes relevant stenosis [16]. A cut-off value of 0.8 has been established. This applies to both the invasive measurement and the AI-based analysis: with the same reference values, the pressure is measured 2 cm distal to the previously described lesion, using AI-based technology which allows the physiological aspect and thus the coronary blood flow in the vessels to be simulated from cCTA [17].

## Statistical Procedures

Statistical analyses were carried out using IBM SPSS software version 29.0. Categorical variables were presented as relative and absolute frequencies, and ordinal and non-normally distributed nu-

merical variables were presented as quartiles. The independent subgroups of these variables were compared using the Mann-Whitney-U test. In order to illustrate the relationships between ordinal and metric variables, the calculation was performed using the Spearman non-parametric correlation. Normally distributed metric variables were reported as the mean value ± standard deviation. Using a t-test for independent samples, 2 groups of interval-scaled variables were each tested for mean value differences. Pearson's correlation was used to investigate the relationships between metric variables. A p-value < 5 % (0.05) is considered significant, and a p-value of 1 % (0.01) or less is considered highly significant.

## Results

We investigated 63 patients, consisting of 13 women (20.6 %) and 50 men (79.4 %). The mean age of the patients was 70 years, with a standard deviation of 8.8 years. At a mean age of 70.5 years (63–77), the men were descriptively younger than the women, whose mean age was 76 years (63.5–78.0). With a median BMI of 26.3 (24.1–27.8), the male patients were significantly heavier ( $p < 0.001$ ), and the analysis of the calcium score also showed significance in terms of gender distribution. The calcium score was significantly higher in men ( $p = 0.041$ ). The demographic data are summarized in ► **Table 1**.

Men were descriptively more likely than women to have at least moderate stenosis ( $\geq 50$  %) in all three vessels. The degrees of coronary artery stenosis found on cCTA and the maximum degree in gender comparison are illustrated in ► **Table 2** using the chi-squared test.

The stenosis of the LAD and Cx, determined on cCTA, was descriptively but not significantly higher in men than in women.

The fractional flow reserve in FFRCT was also higher on average in the female patients, as shown by the Mann-Whitney U test. Here, a significant difference was found not only in the Cx ( $p = 0.002$ ), but also in the LAD ( $p = 0.005$ ), as well as in MinFFRCT ( $p = 0.021$ ), see ► **Table 3**.

Furthermore, the Spearman non-parametric correlation showed a highly significant positive correlation between the degree of stenosis and the respective calcium score (► **Table 4**).

The correlation coefficients showed a moderately to highly significant negative correlation between the FFRCT values and the respective degrees of stenosis on cCTA, which means that FFRCT reflects the results of cCTA well in general (► **Table 5**).

► **Table 1** Patients demographics and risk factors.

	m (n = 50)	w (n = 13)	total (n = 63)
Age	70.5 [63.0–77.0]	76.0 [63.5–78.0]	71 [63–77]
BMI	26.8 [25.3–28.1]	22.7 [22.4–24.9]	26.3 [24.1–27.8]
Calcium score	440 [163–982]	130 [65–521]	389 [108–827]

► **Table 2** Degrees of stenosis in the cCTA broken down by gender.

Degree of stenosis cCTA		w	m	total
LAD				
	0 (< 25 %)	0 (0 %)	3 (6.0 %)	3 (4.8 %)
	1 (25–50 %)	4 (30.8 %)	15 (30.0 %)	19 (30.2 %)
	2 (50–75 %)	8 (61.5 %)	15 (30.0 %)	23 (36.5 %)
	3 (75–90 % and > 90 %)	1 (7.7 %)	16 (32.0 %)	17 (27.0 %)
	4 (100 %)	0 (0 %)	1 (2.0 %)	1 (1.6 %)
CX				
	0 (< 25 %)	7 (46.2 %)	14 (29.2 %)	20 (32.8 %)
	1 (25–50 %)	6 (46.2 %)	13 (27.1 %)	19 (31.1 %)
	2 (50–75 %)	1 (7.7 %)	13 (27.1 %)	14 (23.0 %)
	3 (75–90 % and > 90 %)	0 (%)	8 (16.7 %)	8 (13.1 %)
	4 (100 %)	0 (0 %)	0 (0 %)	0 (0 %)
RCA				
	0 (< 25 %)	8 (61.5 %)	18 (36.0 %)	26 (41.3 %)
	1 (25–50 %)	0 (0 %)	11 (22.0 %)	11 (17.5 %)
	2 (50–75 %)	4 (30.8 %)	16 (32.0 %)	20 (31.7 %)
	3 (75–90 % and > 90 %)	1 (7.7 %)	5 (10.0 %)	6 (9.5 %)
	4 (100 %)	0 (0 %)	0 (0 %)	0 (0 %)
MaxCoro				
	0 (< 25 %)	0 (0 %)	2 (4.0 %)	2 (3.2 %)
	1 (25–50 %)	3 (23.1 %)	8 (16.0 %)	11 (17.5 %)
	2 (50–75 %)	8 (61.5 %)	19 (38.0 %)	27 (42.9 %)
	3 (75–90 % and > 90 %)	2 (15.4 %)	20 (40.0 %)	22 (34.9 %)
	4 (100 %)	0 (0 %)	1 (2.0 %)	1 (1.6 %)

► **Table 3** Mean flow reserve in coronary vessels in gender comparison.

Arteries	Sex	N	Average	SD
LAD (FFR CT)	w	13	0.84	0.07
	m	50	0.76	0.14
CX (FFR CT)	w	13	0.92	0.06
	m	50	0.85	0.09
RCA (FFR CT)	w	13	0.89	0.07
	m	49	0.88	0.09
MinFFR	w	13	0.82	0.07
	m	50	0.75	0.14

The degrees of stenosis found on cCTA showed the following hemodynamic relevance for individual coronary vessels on FFRCT (► **Table 6**):

In the LAD, 65.2 % of the moderate-grade stenoses (grade 2) described on cCTA were not hemodynamically relevant on FFRCT,

compared to 29.4 % of the stenoses described as high-grade (grade 3) (► **Fig. 1**). ► **Fig. 1–3** illustrate the proportion of stenoses classified as hemodynamically relevant or non-relevant according to FFRCT for the respective stenosis grades according to cCTA.

► **Table 4** Relationship between degree of stenosis and calcium score in the Spearman correlation.

CT calcium score	LAD (CTA)	CX (CTA)	RCA (CTA)	MaxCoro (CTA)
Correlation coefficient $\rho$	0.348**	0.599**	0.566**	0.388**
Sig. (2-sided)	0.005	0.000	0.000	0.002

\*\* significant at the level of 1 %.

► **Table 5** Relationship between cCTA and FFR<sub>CT</sub>.

		LAD (FFR CT)	CX (FFR CT)	RCA (FFR CT)	MinFFR (minimum of FFR-CT results)
LAD (CoroCT)	Correlation coefficient	-0.542**	-0.394**	-0.394**	-0.540**
	Sig. (2-sided)	0.000	0.001	0.002	0.000
CX (CoroCT)	Correlation coefficient	-0.399**	-0.540**	-0.511**	-0.572**
	Sig. (2-sided)	0.001	0.000	0.000	0.000
RCA (CoroCT)	Correlation coefficient	-0.102	-0.274*	-0.604**	-0.344**
	Sig. (2-sided)	0.428	0.030	0.000	0.006
MaxCoro (maximum of CoroCT results)	Correlation coefficient	-0.433**	-0.530**	-0.615**	-0.596**
	Sig. (2-sided)	0.000	0.000	0.000	0.000

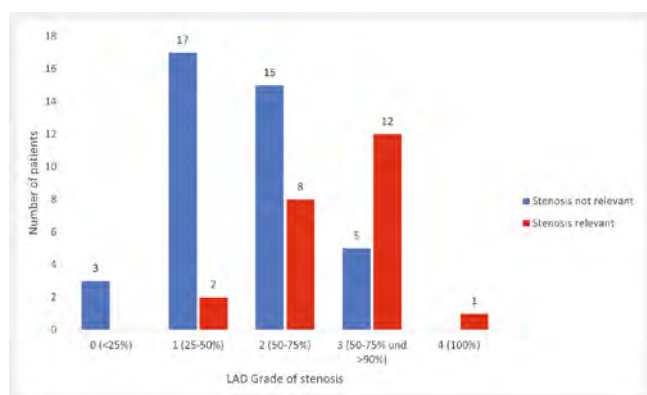
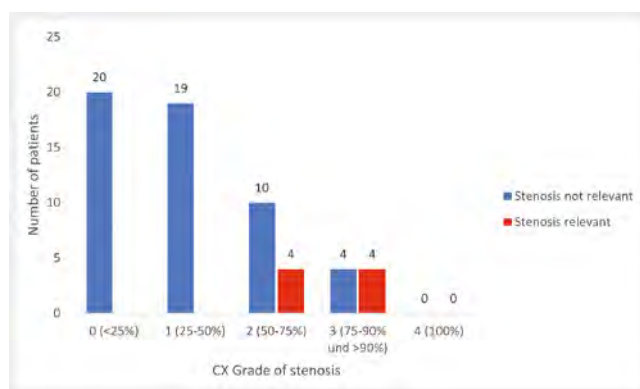
\*\* significant at the level of 1 %.

► **Table 6** Hemodynamic relevance of stenosis degrees according to cCTA per coronary vessel.

Degree of stenosis cCTA		FFR <sub>CT</sub> > 0.8 (hemodynamically non- relevant)	FFR <sub>CT</sub> ≤ 0.8 (hemodynamically relevant)
LAD			
	0 (< 25 %)	3 (100 %)	0 (0 %)
	1 (25–50 %)	17 (89.5 %)	2 (10.5 %)
	2 (50–75 %)	15 (65.2 %)	8 (34.8 %)
	3 (75–90 % und > 90 %)	5 (29.4 %)	12 (70.6 %)
	4 (100 %)	0 (0 %)	1 (100 %)
CX			
	0 (< 25 %)	20 (100 %)	0 (0 %)
	1 (25–50 %)	19 (100 %)	0 (0 %)
	2 (50–75 %)	10 (71.4 %)	4 (28.6 %)
	3 (75–90 and > 90 %)	4 (50.0 %)	4 (50.0 %)
	4 (100 %)	0 (0 %)	0 (0 %)

► **Table 6** (Continuation)

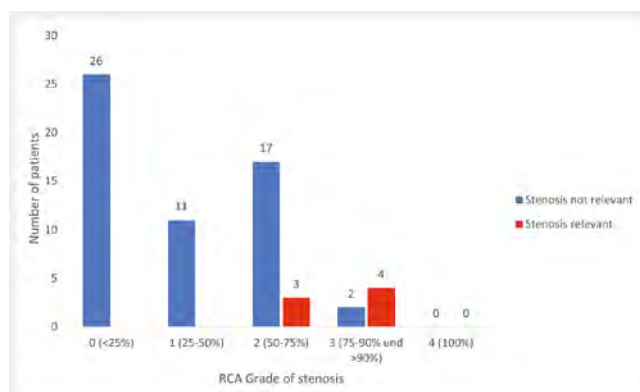
Degree of stenosis cCTA		FFR <sub>ct</sub> > 0.8 (hemodynamically non- relevant)	FFR <sub>ct</sub> ≤ 0.8 (hemodynamically relevant)
RCA			
	0 (<25 %)	26 (100 %)	0 (0 %)
	1 (25–50 %)	11 (100 %)	0 (0 %)
	2 (50–75 %)	17 (85.0 %)	3 (15.0 %)
	3 (75–90 % and > 90 %)	2 (33.3 %)	4 (66.7 %)
	4 (100 %)	0 (0 %)	0 (0 %)

► **Fig. 1** Degrees of stenosis and hemodynamic relevance of fractional flow reserve in the Ramus interventricularis anterior (left anterior descending, LAD).► **Fig. 2** Degrees of stenosis and hemodynamic relevance of fractional flow reserve in the Ramus circumflexus (CX).

In the Cx, hemodynamic relevance was found in 28.6 % of patients with moderate stenosis, and was excluded in 71.4 %. Of the high-grade stenoses, 50 % were found to be hemodynamically relevant; in the other 50 %, hemodynamic relevance could be ruled out (► **Fig. 2**).

The assessment of the stenosis grades 0 (no stenosis) and 1 (mild stenosis) determined on cCTA was also consistent for the RCA, and hemodynamic relevance was excluded in each case. FFRCT showed that 85 % of the moderate stenoses were not hemodynamically relevant, while 15 % were. In the case of severe stenosis, absence of hemodynamic relevance was found in 33.3 % of cases (► **Fig. 3**).

As an example, invasive confirmation in the case of undetected stenosis is shown in ► **Fig. 4** and detected stenosis in ► **Fig. 5**.

► **Fig. 3** Degrees of stenosis and hemodynamic relevance of fractional flow reserve in the Arteria coronaria dextra (right coronary artery, RCA).

## Conclusion

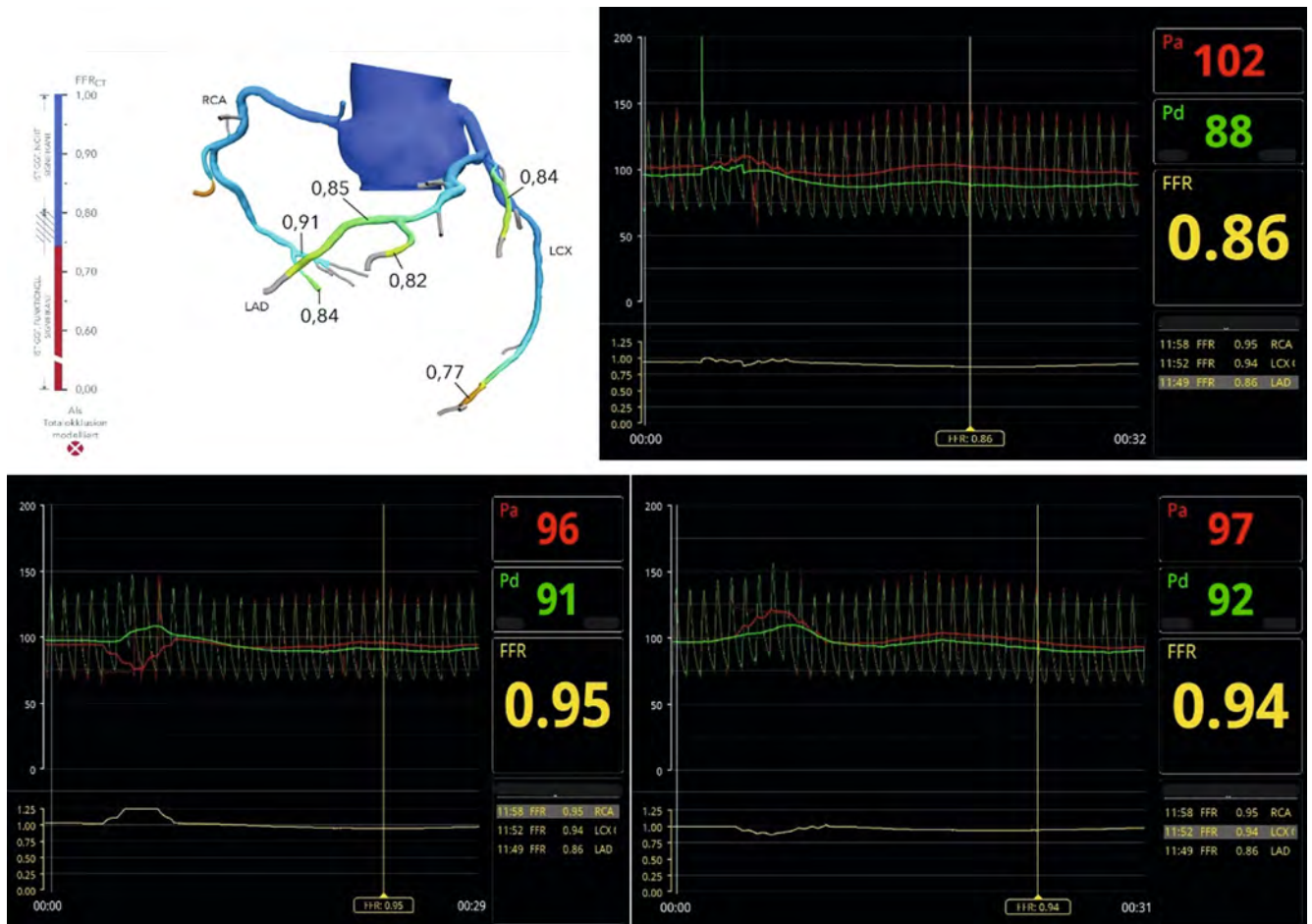
Our study showed that the FFRCT values correlate to the cCTA values to a highly significant degree, i. e., FFRCT generally reflects the results of cCTA.

Furthermore, it was shown that the assessment of hemodynamic relevance by FFRCT differed from the severity of the stenosis diagnosed by cCTA in a good third of all stenoses described as high-grade on computed tomography. The discrepancies were

greatest for all 3 vessels in the range of moderate to high-grade stenosis, while results in the marginal range “no stenosis/vascular occlusion” were 100 % consistent in each case.

The available data illustrate that FFRCT, which is regarded as a validated method in the literature [13, 18, 19], used as a supplement to cCTA in accordance with national and international





► **Fig. 4** Invasive confirmation of the result of FFRct by invasive FFR using the example of non-relevant coronary artery stenosis.

guidelines on the treatment of CHD, can make a decisive contribution to the planning of further treatment.

## Discussion

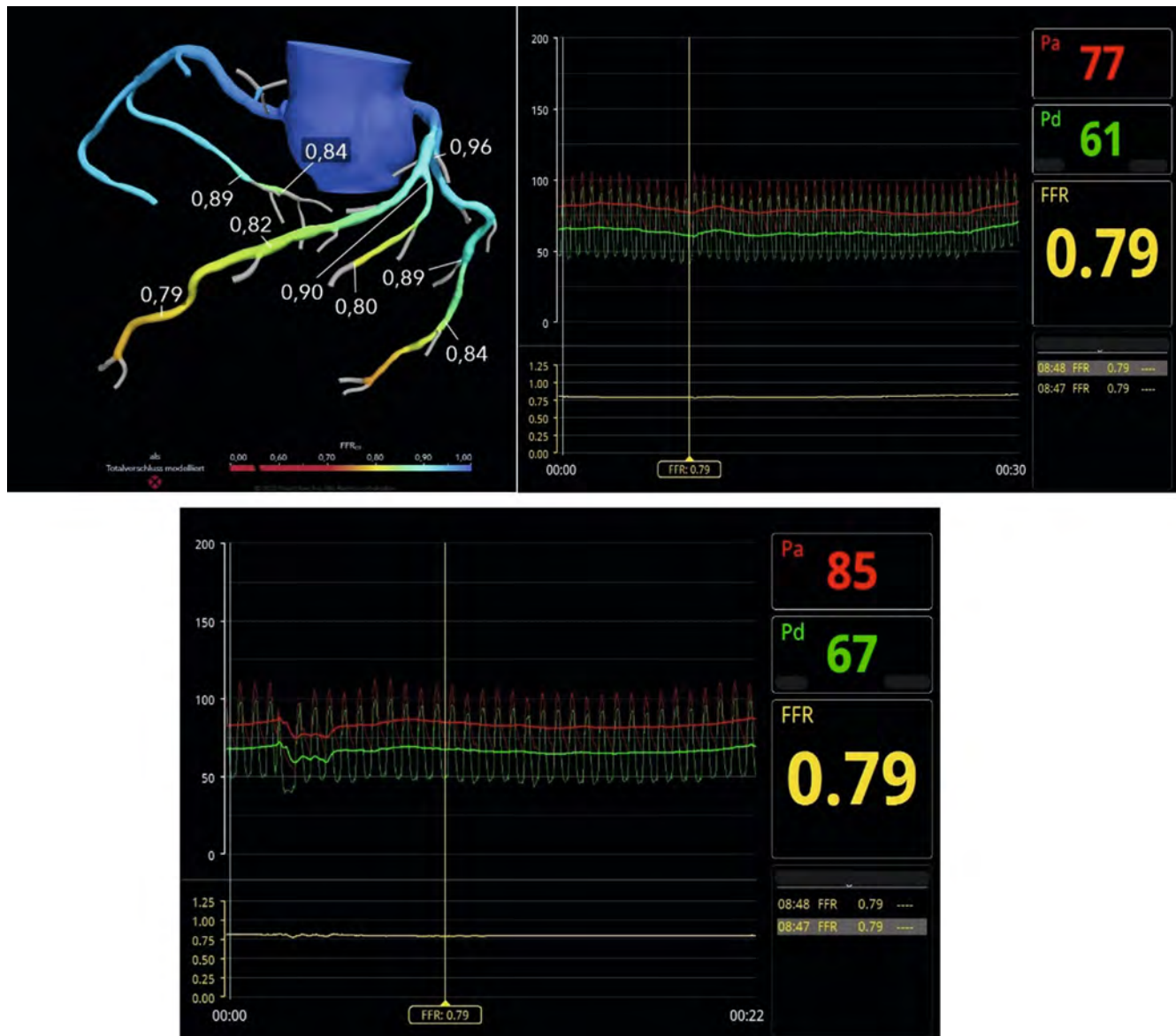
The rapid technical developments, particularly over the last 10–15 years, have necessitated a fundamental rethink, especially in the diagnosis of CHD. As the advent of volume computed tomography has opened up new possibilities [20], the recommendations in the guidelines have also changed over time, both nationally and internationally [9, 14, 15]. Based on study results with appropriate data, there has been a slow but steady change in the recommendations on the diagnosis of patients with unclear chest pain and suspected stable CHD and with a low to moderate pre-test probability. With a sensitivity of 93 % and specificity of 86 % [21], cardiac CT has developed as a true alternative to cardiac catheterization, also due to the increasingly lower radiation exposure [4]. However, as a purely morphological procedure, it lacks the physiological aspect, i. e., the assessment of the actual hemodynamic relevance of a detected stenosis. Here, FFRCT has become increasingly important as a non-invasive method for AI-based determination of hemodynamic relevance. By calculating the fractional flow reserve from the collected cardiac CT data, this technique

can model the hemodynamic relevance of stenosis, thus making a decisive contribution to further treatment planning in accordance with the recommendations set out in the guidelines.

Even though the former gold standard, cardiac catheterization, is only recommended as an invasive procedure in the National Care Guideline for Chronic CHC [5], and is no longer used for diagnostic purposes, to date only cardiac catheterization is covered by health insurance. Cardiac CT is not. Nevertheless, there is a broad consensus at the medical and professional level concerning the usefulness of this technology, and both access to high-end equipment and the guarantee of the necessary professional expertise by radiologists and cardiologists qualified in this specialty are now ensured throughout Germany [22].

A wide range of studies [13, 18, 19] has ultimately led to FFRCT already receiving a class 2a recommendation in the 2021 American guidelines on the diagnosis of patients with unclear chest pain and suspected stable CHD, and is already mentioned in the 2019 European guidelines. There is no recommendation (yet) in the 2022 German National Healthcare Guideline [9, 14, 15].

Against the backdrop of the current body of study data [13, 18, 19] and the recommendations in the respective guidelines [9, 14, 15], our study shows the benefit of combining cCTA and FFRCT so as to optimize the findings by supplementing the morphological data with the physiological aspect; this makes it possible to avoid



► **Fig. 5** Invasive confirmation of the result of FFRct by invasive FFR using the example of a relevant coronary artery stenosis.

unnecessary invasive, risky, and costly procedures in the diagnosis of unclear chest pain and suspected stable CHD in patients with a pretest probability of 15–50%, while still managing to achieve high sensitivity and specificity with no demonstrable increased risk for patients [13, 23–25].

The final assessment of these findings, obtained at the highest quality level, is the responsibility of qualified specialists from the fields of radiology and cardiology who determine the further procedure for each patient individually in the context of interdisciplinary consensus.

#### CLINICAL RELEVANCE OF THE STUDY

- Cardiac CT is becoming increasingly relevant due to ongoing technical developments; the morphological assessment it provides can be supplemented using FFRCT which

provides the physiological aspect, namely the hemodynamic relevance of the detected stenosis.

- By increasing the specificity of cardiac CT through AI-based calculation of the hemodynamic relevance of stenosis, FFRCT makes it possible to avoid unnecessary invasive, risky, and costly procedures, with no demonstrable increased risk for patients.
- The results of this study may help to ensure that in future FFRCT will at least be mentioned in the National Healthcare Guidelines in addition to cardiac CT, in line with the 2021 American guidelines and the 2019 European guidelines.

#### Conflict of Interest

The authors declare that they have no conflict of interest.



## References

- [1] Deutsche Herzstiftung 33. Deutscher Herzbericht 2021. <https://www.herzstiftung.de/service-und-aktuelles/publikationen-und-medien/herzbericht> Zugriff am 01.03.2023
- [2] DESTATIS Todesursachenstatistik 2021. [https://www.destatis.de/DE/Themen/Gesellschaft-Umwelt/Gesundheit/Todesursachen/\\_inhalt.html](https://www.destatis.de/DE/Themen/Gesellschaft-Umwelt/Gesundheit/Todesursachen/_inhalt.html) Zugriff am 27.02.2023
- [3] Busch U. Dreidimensionale Körperwelten- 50 Jahre Computertomografie. <https://www.drg.de/de-DE/10046/50-jahre-ct-teil-2/> Zugriff am 01.03.2023
- [4] Schlosser T. CT-Koronarangiografien. In: Thelen M, Erbel R, Kreitner K, et al. Hrsg. Bildgebende Kardiagnostik. 1. Auflage Stuttgart: Thieme; 2010
- [5] GE Healthcare. TrueFidelity™ – Computertomografie mit KI. <http://www.gehealthcare.de/products/computed-tomography/truefidelity> Zugriff am 30.04.2023
- [6] Nasser TK, Mohler ER 3<sup>rd</sup>, Wilensky RL et al. Peripheral vascular complications following coronary interventional procedures. *Clin Cardiol* 1995; 18 (11): 609–614
- [7] Davis C, VanRiper S, Longstreet J et al. Vascular complications of coronary interventions. *Heart Lung* 1997; 26 (2): 118–127
- [8] Deutsche Herzstiftung. Herzkatheteruntersuchung bei der koronaren Herzkrankheit. <http://www.herzstiftung.de/infos-zu-herzerkrankungen/koronare-herzkrankheit/herzkatheteruntersuchung> Zugriff am 09.03.2023
- [9] Bundesärztekammer (BÄK), Kassenärztliche Bundesvereinigung (KBV), Arbeitsgemeinschaft der Wissenschaftlichen Medizinischen Fachgesellschaften (AWMF). Nationale VersorgungsLeitlinie Chronische KHK- Leitlinienreport, Version 6.0. 2022 [cited: 2023-02-27]. doi:10.6101/AZQ/000490. [www.leitlinien.de/khk](http://www.leitlinien.de/khk)
- [10] Baumann S, Overhoff D, Tesche C et al. Morphologische und funktionelle Diagnostik der koronaren Herzkrankheit mittels Computertomografie. *Herz* 2023; 48: 39–47
- [11] HeartFlow FFR<sub>ct</sub> Analysis. <https://www.heartflow.com/heartflow-ffrct-analysis/article/our-technology-core/> Zugriff am 13.03.2023
- [12] Nørgaard BL, Leipsic J, Gaur S et al. Diagnostic performance of noninvasive fractional flow reserve derived from coronary computed tomography angiography in suspected coronary artery disease: the NXT trial (Analysis of Coronary Blood Flow Using CT Angiography: Next Steps). *Int J Cardiol* 2014; 63 (12): 1145–1155
- [13] Maurovich-Horvat P, Bossert M, Kofoed KF. The DISCHARGE Trial Group et al. CT or Invasive Coronary Angiography in Stable Chest Pain. *N Engl J Med* 2022; 386: 1591–1602
- [14] 2021 AHA/ACC/AASE/CHEST/SAEM/SCCT/SCMR Guideline for the Evaluation and Diagnosis of Chest Pain: A Report of the American College of Cardiology/American Heart Association Joint Committee on Clinical Practice Guidelines. *J Am Coll Cardiol* 2021; 78 (22): e187–e285
- [15] Knuuti J, Wijns W, Saraste A et al. 2019 ESC Guidelines for the diagnosis and management of chronic coronary syndromes. *Eur Heart J* 2020; 41 (44): 4242
- [16] Klauss V. Fraktionelle Flussreserve: Chancen und Grenzen des Verfahrens. *Dtsch Arztebl* 2016; 113 (12): 30
- [17] Rajiah P, Cummings KW, Williamson E et al. CT Fractional Flow Reserve: A Practical Guide to Application, Interpretation, and Problem Solving. *Radiographics* 2022; 42 (2): 340–358
- [18] Koo BK, Erglis A, Doh J-H et al. Diagnosis of Ischemia Causing Coronary Stenoses by Noninvasive Fractional Flow Reserve Computed From Coronary Computed Tomographic Angiograms: Results From the Prospective Multi-center DISCOVER-FLOW (Diagnosis of Ischemia-Causing Stenoses Obtained Via Noninvasive Fractional Flow Reserve) Study. *J Am Coll Cardiol* 2011; 58 (19): 1989–1997
- [19] Patel MR, Nørgaard BL, Fairbairn TA et al. 1-Year Impact on Medical Practice and Clinical Outcomes of FFR<sub>ct</sub>: The ADVANCE Registry. *J Am Coll Cardiol Img* 2020; 13 (1\_Part\_1): 97–105
- [20] Ballmoos MW, Haring B, Juillerat P et al. Meta-analysis: diagnostic performance of low-radiation-dose coronary computed tomography angiography. *Ann Intern Med* 2011; 154 (6): 413–420
- [21] Li S, Ni Q, Wu H et al. Diagnostic accuracy of 320-slice computed tomography angiography for detection of coronary artery stenosis: meta-analysis. *Int J Cardiol* 2013; 168 (3): 2699–2697
- [22] Sieren MM, Maintz D, Gutberlet M et al. Current Status of Cardiovascular Imaging in Germany: Structured Data from the National Certification Program, ESCR Registry, and Survey among Radiologists. *Fortschr Röntgenstr* 2022; 194 (2): 181–191
- [23] Zimmermann FM, Ferrara A, Johnson NP et al. Deferral vs. performance of percutaneous coronary intervention of functionally non-significant coronary stenosis. 15-year follow-up of the DEFER trial. *European Heart Journal* 2015; 36 (45): 3182–3188
- [24] Patel MR, Peterson ED, Dai D et al. Low Diagnostic Yield of Elective Coronary Angiography. *N Engl J Med* 2010; 362 (10): 886–895
- [25] Maron DJ, Hochman JS, Reynolds HR et al. Initial Invasive or Conservative Strategy for Stable Coronary Disease. *N Engl J Med* 2020; 382: 1395–1407