

Outcomes predictors in endoscopic ultrasound-guided choledochoduodenostomy with lumen-apposing metal stent: Systematic review and meta-analysis

OPEN
ACCESS

Authors

Alessandro Fugazza¹, Kareem Khalaf², Marco Spadaccini¹, Antonio Facciorusso³, Matteo Colombo¹, Marta Andreozzi¹, Silvia Carrara¹, Cecilia Binda⁴, Carlo Fabbri⁴, Andrea Anderloni⁵, Cesare Hassan^{1,6}, Todd Baron⁷, Alessandro Repici^{1,6}

Institutions

- 1 Division of Gastroenterology and Digestive Endoscopy, Department of Gastroenterology, IRCCS Humanitas Research Hospital, Rozzano (MI), Italy
- 2 Division of Gastroenterology, St Michael's Hospital, Toronto, Canada
- 3 Gastroenterology, University of Foggia, Foggia, Italy
- 4 Gastroenterology and Digestive Endoscopy Unit, Forlì-Cesena Hospitals, Ausl Romagna, Forlì-Cesena, Italy
- 5 Gastroenterology and Digestive Endoscopy Unit, Fondazione IRCCS Policlinico San Matteo, Pavia, Italy
- 6 Department of Biomedical Sciences, Humanitas University, Milan, Italy
- 7 Gastroenterology & Hepatology, University of North Carolina, Chapel Hill, United States

Keywords

Pancreatobiliary (ERCP/PTCD), Biliary tract, Endoscopic ultrasonography, Intervention EUS

received 24.10.2023

accepted after revision 11.1.2024

accepted manuscript online 19.02.2024

Bibliography

Endosc Int Open 2024; 12: E456–E462

DOI 10.1055/a-2271-2145

ISSN 2364-3722

© 2024. The Author(s).

This is an open access article published by Thieme under the terms of the Creative Commons Attribution-NonDerivative-NonCommercial License, permitting copying and reproduction so long as the original work is given appropriate credit. Contents may not be used for commercial purposes, or adapted, remixed, transformed or built upon. (<https://creativecommons.org/licenses/by-nc-nd/4.0/>)

Georg Thieme Verlag KG, Rüdigerstraße 14,
70469 Stuttgart, Germany

Corresponding author

Dr. Alessandro Fugazza, Division of Gastroenterology and Digestive Endoscopy, Department of Gastroenterology, IRCCS Humanitas Research Hospital, Via Manzoni 56, 20089 Rozzano (MI), Italy
alessandro.fugazza@humanitas.it

Supplementary Material is available at
<https://doi.org/10.1055/a-2271-2145>

ABSTRACT

Background and study aims EUS-guided choledochoduodenostomy (EUS-CDS) is a minimally invasive procedure used to treat malignant biliary obstruction (MBO) by transduodenal placement of a lumen-apposing metal stent (LAMS) into the extrahepatic bile duct. To identify factors that contribute to safe and effective EUS-CDS using LAMS, we performed a systematic review of the literature and meta-analysis.

Methods The methodology of our analysis was based on PRISMA recommendations. Electronic databases (Medline, Scopus, EMBASE) were searched up to November 2022. Full articles that included patients with distal malignant biliary obstruction who underwent EUS-CDS using LAMS after failed endoscopic retrograde cholangiopancreatography were eligible. Random-effect meta-analysis was performed reporting pooled rates of technical success, clinical success, and adverse events (AEs) by means of a random model. Multivariate meta-regression and subgroup analysis were performed to assess possible associations between the outcomes and selected variables to assess the correlation between outcomes and different variables. Results were also stratified according to stent size.

Results Twelve studies with 845 patients were included in the meta-analysis. Pooled technical and clinical success rates were 96% (95% confidence interval [CI] 94%-98%; $I^2 = 52.29\%$) and 96% (95%CI 95%-98%), respectively, with no significant association with baseline characteristics, such as sex, age, common bile duct diameter, or stent size. The pooled AE rate was 12% (95%CI: 8%-16%; $I^2 = 71.62\%$). The AE rate was significantly lower when using an 8 × 8 mm stent as compared with a 6 × 8 mm LAMS (odds ratio 0.59, 0.35–0.99; $P = 0.04$), with no evidence of heterogeneity ($I^2 = 0\%$).

Conclusions EUS-CDS with LAMS is a safe and effective option for relief of MBO. Selecting an appropriate stent size is crucial for achieving optimal safety outcomes.

Introduction

Management of malignant biliary obstruction (MBO) is of paramount importance because obstructive jaundice dramatically decreases the ability to administer systemic chemotherapy to patients with unresectable disease. MBO reduces quality of life and increases the risk of morbidity and mortality [1]. Currently, endoscopic retrograde cholangiopancreatography (ERCP) with transpapillary placement of self-expanding metal stents is considered the gold-standard technique to achieve biliary drainage in distal MBO [2, 3], enabling a high success rate, ranging from 86% to 99% when considering all indications, and with an acceptable safety profile. However, in the setting of malignant disease, a lower rate of success might be expected, with a higher need for advanced cannulation techniques (i. e., needle knife pre-cut) with their associated adverse events (AEs) [4, 5, 6, 7].

In case of ERCP failure, a percutaneous approach is traditionally considered the main secondary option. However, since first reported by Giovannini et al. [8], interventional endoscopic ultrasonography (EUS) has been demonstrated to be a viable option for palliation of MBO. In particular, EUS-guided choledochoduodenostomy (EUS-CDS) has emerged as an alternative treatment modality by providing internal biliary drainage in patients with distal common bile duct (CBD) obstruction and upstream biliary system dilation. Furthermore, the development of a lumen-apposing metal stent (LAMS) with cautery-enhanced delivery system allows simple one-step puncture and stent delivery, greatly shortening procedure duration. This rapidly spreading approach, initially performed only as an alternative to percutaneous drainage for cases of ERCP failure, is now challenging ERCP as the primary approach for relief of MBO [9, 10, 11, 12]. Despite promising data, the major concern is mainly related to the long experience with ERCP, which has allowed recognition of factors that affect the risk of technical/clinical success, and development of AEs.

Initial experience with EUS-CDS proved its feasibility, efficacy, and safety and more recently the volume of published data has grown exponentially, offering us the opportunity for a deeper insight with this approach.

The primary objective of this meta-analysis was to quantitatively assess patient- and procedure-related factors potentially influencing the outcomes of EUS-CDS using LAMS in the management of distal MBO.

Methods

The methods for our analysis and inclusion criteria were based on Preferred Reporting Items for Systematic Reviews and Meta-Analyses recommendations [13]. Data sources and search strategy, selection process, data extraction, and quality assessment are reported in Appendix 1.

Selection criteria

For the purpose of this systematic review, we considered all clinical studies that included patients with distal MBO who underwent EUS-CDS using LAMS after failed ERCP. Small case series including < 10 patients, non-endoscopic studies, review ar-

ticles, and animal models were excluded. Data where EUS-CDS was performed as primary therapy rather than ERCP were also excluded.

Outcomes assessed

The primary outcome was clinical success. We followed the definitions of clinical success as defined by individual studies (Supplementary Table 1). Secondary outcomes were technical success, defined as successful LAMS deployment under EUS guidance with consequent biliary drainage, and AE rate. AEs were defined as any procedural/stent-related event including abdominal pain, fever, perforation, bleeding, bile leak, jaundice, stent obstruction and cholangitis. Severity of AEs was graded according to the American Society for Gastrointestinal Endoscopy lexicon [14]. AEs were grouped into three categories: immediate, early, and late, based on the timing of their onset and considered as per individual study definitions.

Statistical analysis

Study outcomes were pooled through a random-effects model based on DerSimonian and Laird test [15], and results were expressed as rates and 95% confidence intervals (CIs). Comparisons between different LAMS diameters, namely 8 × 8 mm vs 6 × 8 mm, were based on a random-effects model and results were expressed as odds ratios (ORs) and 95% CIs.

The presence of heterogeneity was calculated through I^2 tests; values of 0% to 40%, 30% to 60%, 50% to 90%, and 75% to 100% were indicated as low, moderate, substantial, and considerable heterogeneity, respectively [16]. Any potential publication bias was verified through visual assessment of funnel plots.

Multivariate meta-regression was performed to analyze the correlation between baseline age, sex, and CBD diameter and clinical success rate.

A sensitivity analysis based on the timing of AE occurrence (immediate, early, or late) was performed.

All statistical analyses were conducted using RevMan (version 5.0 for Windows; the Cochrane Collaboration, Oxford, UK), Jamovi 1.6, R 4.0 software, and R 3.0.2 (R Foundation for Statistical Computing, Vienna, Austria).

For all calculations, $P < 0.05$ was considered statistically significant.

Results

Studies

As shown in ► **Fig. 1**, 2788 studies were initially identified. After exclusion of articles not fulfilling the inclusion criteria, 12 studies [17, 18, 19, 20, 21, 22, 23, 24, 25, 26, 27, 28] with 845 patients were included in the meta-analysis, of which 10 were non-comparative, single-cohort, retrospective studies. Study characteristics are reported in ► **Table 1**.

We used the Newcastle-Ottawa Scale for nonrandomized studies [29] to assess methodology quality, which gave a mean score of 4.8 (range 4–5) (Supplementary Table 2, Appendix 1).

Technical success

The pooled technical success rate was 96% (95%CI 94%-98%), with moderate evidence of heterogeneity ($I^2 = 52.29\%$; ► **Fig. 2**). No evidence of publication bias was detected through visual inspection of the funnel plot (Supplementary Fig. 1, Appendix 1).

Comparison rates for technical success using 8×8 mm vs 6×8 mm stents are reported in Supplementary Fig. 2, Appendix 1. Based on four studies, no difference in terms of technical success rates was observed between the two diameters (OR 1.21, 95%CI 0.51–2.85), with no evidence of heterogeneity ($I^2 = 0\%$).

Clinical success

As depicted in ► **Fig. 2**, the pooled clinical success rate was 96% (95%CI 95%-98%), with evidence of mild heterogeneity ($I^2 = 23.78\%$). No evidence of publication bias was detected through visual inspection of the funnel plot (Supplementary Fig. 3, Appendix 1).

Meta-regression analysis did not find a significant association between some baseline characteristics—namely sex, age, and CBD diameter—and clinical success rate ($P = 0.45$, $P = 0.20$, and $P = 0.53$, respectively; Supplementary Fig. 4, Appendix 1). Moreover, no difference between 8×8 mm and 6×8 mm stents was observed in terms of clinical success (OR 1.42, 95%CI 0.58–3.46), with mild evidence of heterogeneity ($I^2 = 7\%$; Supplementary Fig. 5, Appendix 1)

AE rate

As reported in ► **Fig. 3**, the pooled overall AE rate was 12% (95%CI 8%-16%), with evidence of substantial heterogeneity ($I^2 = 71.62\%$). No evidence of publication bias was detected based on the funnel plot (Supplementary Fig. 6, Appendix 1). Specifically, early, immediate, and late AE rates were 3% (95%CI 1%-4%), 2% (95%CI 1%-2%), and 4% (95%CI 2%-7%), respectively (Supplementary Fig. 7, Appendix 1). This sensitivity analysis based on timing of AEs occurrence led to a consistent decrease in heterogeneity of the estimates ($I^2 = 56\%$, 0%, and 74%; respectively).

Based on four studies, the AE rate was significantly lower with 8×8 mm as compared with 6×8 mm stents (OR 0.59, 95%CI 0.35–0.99), with no evidence of heterogeneity ($I^2 = 0\%$;

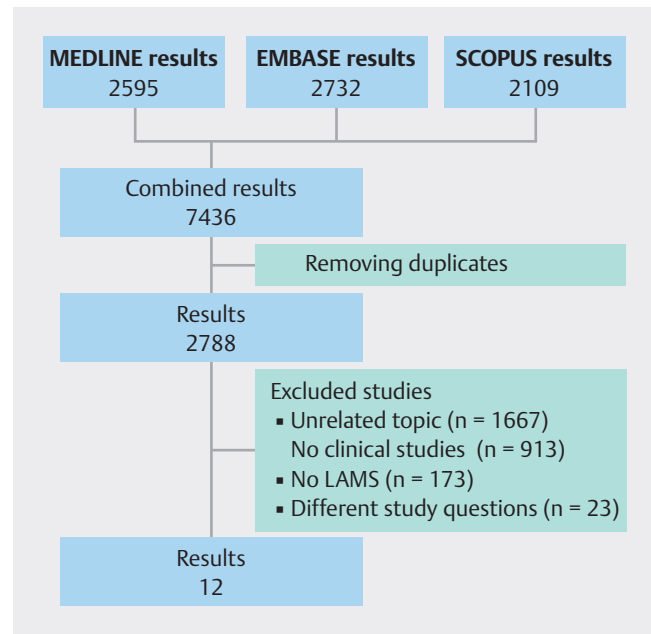
► **Fig. 4**).

The detailed list of AEs observed in the included studies is reported in Supplementary Table 2, Appendix 1.

Discussion

According to our analysis EUS-CDS with LAMS is confirmed as a feasible option for the management of distal MBO, with a favorable benefit/risk ratio due to a very high rate of technical and clinical success (96%), assessed in almost 1000 procedures, and relatively low rate of AEs (12%). Stent size was shown to be the main factor affecting the risk of AEs.

Data from this meta-analysis may have a significant impact on clinical practice because of the ongoing questions related to EUS-guided strategies for biliary drainage. In this regard, the most concerning aspect is safety, especially considering



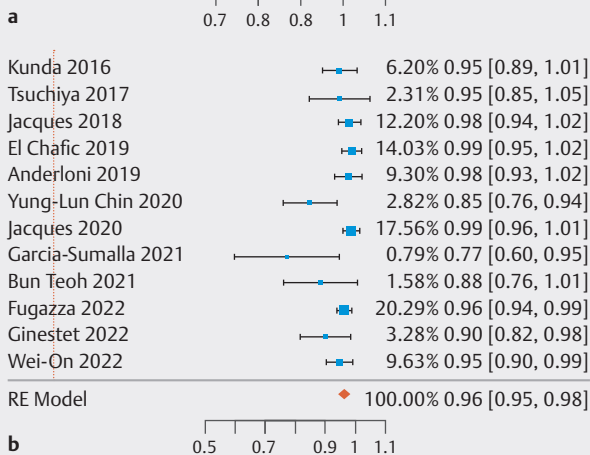
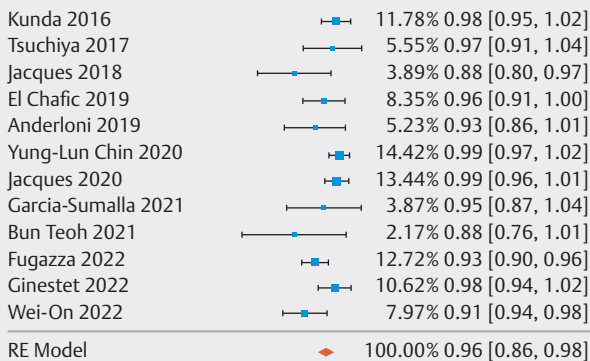
► **Fig. 1** PRISMA flow chart. *Shamseer L, Moher D, Clarke M et al. Preferred reporting items for systematic review and meta-analysis protocols (prisma-p) 2015: Elaboration and explanation. BMJ 2015.*

the relatively limited experience with EUS-CDS using small-diameter LAMS (< 10 mm), especially when compared with the experience of ERCP for MBO. We herein showed that EUS-CDS is associated with an adequate safety profile, with no reported fatal events. In fact, the 12% AE rate seems comparable to the 5% to 15% AE rate reported for ERCP [3, 4, 5, 6, 7, 8, 9, 10, 11, 12, 13, 14, 15, 17, 18, 19, 20, 21, 22, 23, 24, 25, 26, 27, 28, 29, 30].

The impact of stent size on procedure outcome, even if not unexpected, was not obvious. While a larger stent diameter theoretically provides better bile flow and a decreased risk of stent occlusion, it may also theoretically allow food and debris to enter with a resultant increased risk of cholangitis. From a technical point of view, placement of a 6×8 mm LAMS might lead to a reduced risk of stent misdeployment because the minimum space required for deployment is lower than the 8×8 mm LAMS. However, the greater radial force of the 8×8 mm stent may decrease the risk of stent dislodgement. The lower AE rate reported with the 8×8 mm LAMS over the 6-mm LAMS for CDS is an important finding which has not been previously recognized, and only pooling data from individual studies allowed us to reach the statistical power to show such association.

This is even more relevant considering that we were able to exclude the possible confounding influence of CBD size. As a matter of fact, a more dilated CBD is considered an easier target for biliary tract access, and in light of the more frequent choice of an 8×8 mm LAMS in such cases, this could have biased our results. In our analysis, CBD size did not influence technical or clinical success or risk of AEs, highlighting the role of stent size as an independent factor. This suggests it is prefer-

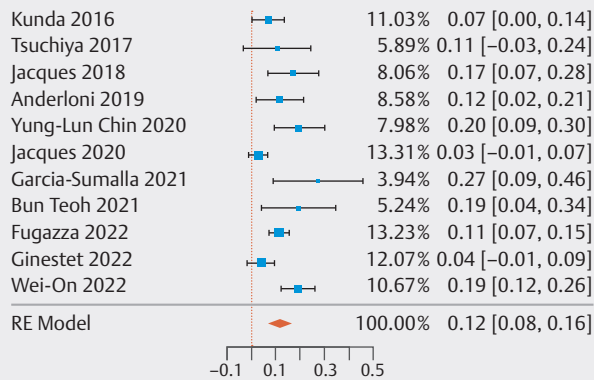
▶ Table 1 Study characteristics.												
Study	Location and Year	No. centers involved	Study design	LAMS delivery system	Total patients (no.)	Gender, Male %	Age (median; range/mean \pm SD)	CBD diameter (median; range/mean \pm SD)	Technical success %	Clinical success %	Study	Location and Year
Kunda	Denmark, 2016	7	Retrospective study	Cold & Hot Axios, Boston Scientific Corp.	57	54.4	73;49–93	17.9; 8–35	98.2	94.7	Kunda	Denmark, 2016
Tsuchiya	Japan and Hong Kong, 2017	5	Prospective Cohort study	Hot Axios, Boston Scientific Corp.	19	63.2	70.6 \pm 13.9	17.3 \pm 5.5	100.0	94.7	Tsuchiya	Japan and Hong Kong, 2017
Jacques	France, 2018	10	Retrospective study	Hot Axios, Boston Scientific Corp.	52	48.1	78;61–92	Not Reported	88.5	98.1	Jacques	France, 2018
ElChafic	USA, 2019	6	Retrospective study	Hot Axios, Boston Scientific Corp.	67	55.2	68.8 \pm 11.8	17.6 \pm 3.6	95.5	100.0	ElChafic	USA, 2019
Anderloni	Italy, 2019	1	Retrospective study	Hot Axios, Boston Scientific Corp.	46	52.2	73.1 \pm 12.6	17.26 \pm 3.34	93.5	97.7	Anderloni	Italy, 2019
Yung-Lun Chin	New Zealand, 2020	1	Retrospective study	Hot Axios, Boston Scientific Corp.	60	56.7	76;52–90	17 \pm 10	100.0	85.0	Yung-Lun Chin	New Zealand, 2020
Jacques	France, 2020	7	Retrospective study	Hot Axios, Boston Scientific Corp.	70	54.3	75 \pm 11	17.7 \pm 5	98.6	98.6	Jacques	France, 2020
Garcia-Su-malla	Spain, 2021	3	Retrospective study	Hot Axios, Boston Scientific Corp.	22	24.4	75.3 \pm 12.1	17.5; 9–27	95.5	77.3	Garcia-Su-malla	Spain, 2021
Bun Teoh	Korea, China, Thailand, Hong Kong, 2021	5	Prospective cohort study	S-LAMS (Niti-5 Spaux, Taewoong Medical, Gyeonggi-do, Korea)	26	46.2	64.1 \pm 13.2	Not reported	88.5	88.5	Bun Teoh	Korea, China, Thailand, Hong Kong, 2021
Fugazza	Italy, 2022	23	Retrospective study	Hot Axios, Boston Scientific Corp. and Nagi Stent	256	55.1	73.9 \pm 12.6	17.3 \pm 3.9	93.4	96.2	Fugazza	Italy, 2022
Ginestet	France, 2022	1	Retrospective study	Hot Axios, Boston Scientific Corp.	50	60.0	76.5 \pm 0	Not reported	98.0	90.0	Ginestet	France, 2022



► Fig. 2 a Technical and b clinical success rates. Forest plot.

able to use the 8 × 8 mm LAMS as opposed to the 6 × 8 LAMS when ductal diameter allows.

The second main result of our analysis is the efficacy profile, with a very high rate of technical and clinical success (96%). If the definition of technical success is homogeneous across the included studies, it can be argued that different definitions of clinical success might affect the results. However, the various definitions of clinical success remained consistent with the definitions suggested by the European Society of Gastrointestinal

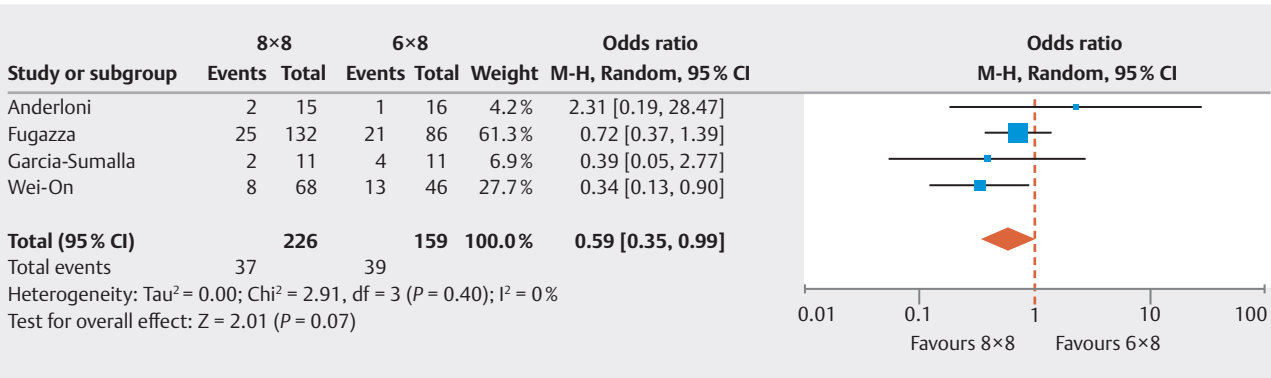


► Fig. 3 Adverse event rate. Forest plot.

Endoscopy [2], and the only moderate heterogeneity of our analysis downgraded this risk.

One of the main strengths of our analysis is the clinical setting of the included studies. As a matter of fact, we only included data from EUS-CDS when used for demanding cases of ERCP failure. Such a high rate of technical success, theoretically achievable during the same ERCP session, gives the endoscopist the opportunity to successfully relieve distal MBO in nearly 100% of cases during one endoscopic session. This prevents the need for rescheduling procedures, allowing rapid improvement of quality of life and institution of systemic chemotherapy [1]. We believe that procedural informed consent for EUS-CDS (or EUS-guided biliary drainage) should be obtained at the time of consent for ERCP in cases of distal MBO [2, 31, 32].

Our analysis has some limitations. First, the majority of the studies included are retrospective, and this may introduce an element of selection bias. This, along with the paucity of comparative studies available, demands some caution in interpretation of the results. Second, considering that all the included patients had failed ERCP before EUS-guided CDS was attempted, we cannot exclude some carryover effect causing an overestimation of the AE risk. This means there may be a lower AE rate



► Fig. 4 Adverse event and stent size.

than seen in this analysis. Despite the lack of head-to-head comparison with ERCP, our study may be informative for designing comparative trials. Third, other important technical points such as drainage technique (i. e. free-hand vs. wire-guided techniques), or the possible use of larger stents (i. e. 10 × 10 mm) have not been homogeneously reported across the included studies, and we are not able to make any evidence-based suggestion about such technical points. Finally, the moderate-to-substantial level of heterogeneity found in several analysis, coupled with differences across the included studies in term of design, center numbers, and sample size may have affected the interpretability of the results. Furthermore, we performed different analyses specifically to investigate the reasons why heterogeneity (i. e. meta-regressions, subgroup analysis) partially mitigated the issue. However, the extremely high rate of both technical and clinical success and the paucity of failure events may have down-powered our meta-regression analysis and a future analysis will be needed to highlight any relevant factors affecting efficacy outcomes. On the other hand, the low level of heterogeneity found in the subgroup analysis based on stent size ($I^2 = 0\%$) provides reassurance about the reliability of data for safety outcomes.

Conclusions

In conclusion, our analysis confirmed that EUS-CDS is a safe and effective option for patients with distal MBO in whom ERCP has failed. The selection of appropriate stent size seems important for achieving optimal outcomes.

Conflict of Interest

Alessandro Fugazza: Consulting fees for Boston Scientific, Cecilia Binda Lecturer for Steris, Q3 Medical, and Boston Scientific, Carlo Fabbri Lecturer for Steris, Q3 Medical, Fuji, and Boston Scientific, Andrea Anderloni: Consulting fees for Olympus and Boston Scientific, Cesare Hassan: Consulting fees for Fuji, and Medtronic, Todd H Baron: Consultant and speaker for Boston Scientific, Cook Endoscopy, Olympus, W.L. Gore, Medtronic, ConMed, Alessandro Repici: Consulting fees for Fuji, Olympus, and Medtronic and receiving research grant and speaker fees from Boston Scientific, ERBE, Alfasiigma, Norgine. Other authors have no conflict of interests.

References

- [1] Stark A, Hines OJ. Endoscopic and operative palliation strategies for pancreatic ductal adenocarcinoma. *Semin Oncol* 2015; 42: 163–176
- [2] Van Der Merwe SW, Van Wanrooij RLJ, Bronswijk M et al. Therapeutic endoscopic ultrasound: European Society of Gastrointestinal Endoscopy (ESGE) Guideline. *Endoscopy* 2022; 54: 185–205
- [3] Dumonceau J-M, Tringali A, Papanikolaou IS et al. Endoscopic biliary stenting: indications, choice of stents, and results: European Society of Gastrointestinal Endoscopy (ESGE) Clinical Guideline - Updated October 2017. *Endoscopy* 2018; 50: 910–930
- [4] van der Gaag NA, Rauws EAJ, van Eijck CHJ et al. Preoperative biliary drainage for cancer of the head of the pancreas. *N Engl J Med* 2010; 362: 129–137
- [5] Wang P, Li Z-S, Liu F et al. Risk factors for ERCP-related complications: a prospective multicenter study. *Am J Gastroenterol* 2009; 104: 31–40
- [6] Enochsson L, Swahn F, Arnelo U et al. Nationwide, population-based data from 11,074 ERCP procedures from the Swedish Registry for Gallstone Surgery and ERCP. *Gastrointest Endosc* 2010; 72: 1175–1184
- [7] Fugazza A, Troncone E, Amato A et al. Difficult biliary cannulation in patients with distal malignant biliary obstruction: An underestimated problem? *Digest Liver Dis* 2022; 54: 529–536
- [8] Giovannini M, Moutardier V, Pesenti C et al. Endoscopic ultrasound-guided bilioduodenal anastomosis: a new technique for biliary drainage. *Endoscopy* 2001; 33: 898–900
- [9] Teoh AYW, Dhir V, Kida M et al. Consensus guidelines on the optimal management in interventional EUS procedures: results from the Asian EUS group RAND/UCLA expert panel. *Gut* 2018; 67: 1209–1228
- [10] Bang JY, Navaneethan U, Hasan M et al. Stent placement by EUS or ERCP for primary biliary decompression in pancreatic cancer: a randomized trial (with videos). *United States. Gastrointest Endosc* 2018; 88: 9–17
- [11] Paik WH, Lee TH, Park DH et al. EUS-guided biliary drainage versus ERCP for the primary palliation of malignant biliary obstruction: a multicenter randomized clinical trial. *Am J Gastroenterol* 2018; 113: 987–997
- [12] Park JK, Woo YS, Noh DH et al. Efficacy of EUS-guided and ERCP-guided biliary drainage for malignant biliary obstruction: prospective randomized controlled study. *Gastrointest Endosc* 2018; 88: 277–282
- [13] Shamseer L, Moher D, Clarke M et al. Preferred reporting items for systematic review and meta-analysis protocols (PRISMA-P) 2015: elaboration and explanation. *BMJ* 2015; 350: g7647
- [14] Cotton PB, Eisen GM, Aabakken L et al. A lexicon for endoscopic adverse events: report of an ASGE workshop. *Gastrointest Endosc* 2010; 71: 446–454
- [15] DerSimonian R, Laird N. Meta-analysis in clinical trials. *Control Clin Trials* 1986; 7: 177–188
- [16] Deeks J. Chapter 9: analyzing data and undertaking meta-analyses. In: *Cochrane handbook for systematic reviews of interventions*. 2008
- [17] Kunda R, Pérez-Miranda M, Will U et al. EUS-guided choledochoduodenostomy for malignant distal biliary obstruction using a lumen-apposing fully covered metal stent after failed ERCP. *Surg Endosc* 2016; 30: 5002–5008
- [18] Tsuchiya T, Teoh AYW, Itoi T et al. Long-term outcomes of EUS-guided choledochoduodenostomy using a lumen-apposing metal stent for malignant distal biliary obstruction: a prospective multicenter study. *Gastrointest Endosc* 2018; 87: 1138–1146
- [19] Jacques J, Privat J, Pinard F et al. Endoscopic ultrasound-guided choledochoduodenostomy with electrocautery-enhanced lumen-apposing stents: a retrospective analysis. *Endoscopy* 2019; 51: 540–547
- [20] El Chafic AH, Shah JN, Hamerski C et al. EUS-guided choledochoduodenostomy for distal malignant biliary obstruction using electrocautery-enhanced lumen-apposing metal stents: First US, Multicenter Experience. *Dig Dis Sci* 2019; 64: 3321–3327
- [21] Anderloni A, Fugazza A, Troncone E et al. Single-stage EUS-guided choledochoduodenostomy using a lumen-apposing metal stent for malignant distal biliary obstruction. *Gastrointest Endosc* 2019; 89: 69–76
- [22] Chin JY-L, Seleq S, Weilert F. Safety and outcomes of endoscopic ultrasound-guided drainage for malignant biliary obstruction using cautery-enabled lumen-apposing metal stent. *Endosc Int Open* 2020; 8: E1633–E1638

- [23] Ginestet C, Sanglier F, Hummel V et al. EUS-guided biliary drainage with electrocautery-enhanced lumen-apposing metal stent placement should replace PTBD after ERCP failure in patients with distal tumoral biliary obstruction: a large real-life study. *Surg Endosc* 2022; 36: 3365–3373
- [24] Jacques J, Privat J, Pinard F et al. EUS-guided choledochoduodenostomy by use of electrocautery-enhanced lumen-apposing metal stents: a French multicenter study after implementation of the technique (with video). *Gastrointest Endosc* 2020; 92: 134–141
- [25] Garcia-Sumalla A, Loras C, Guarner-Argente C et al. Is a coaxial plastic stent within a lumen-apposing metal stent useful for the management of distal malignant biliary obstruction? *Surg Endosc* 2021; 35: 4873–4881
- [26] Teoh AYB, Kongkam P, Bapaye A et al. Use of a novel lumen apposing metallic stent for drainage of the bile duct and gallbladder: Long term outcomes of a prospective international trial. *Dig Endosc* 2021; 33: 1139–1145
- [27] Fugazza A, Fabbri C, Di Mitri R et al. EUS-guided choledochoduodenostomy for malignant distal biliary obstruction after failed ERCP: a retrospective nationwide analysis. *Gastrointest Endosc* 2022; 95: 896–904.e1
- [28] On W, Paranandi B, Smith AM et al. EUS-guided choledochoduodenostomy with electrocautery-enhanced lumen-apposing metal stents in patients with malignant distal biliary obstruction: multicenter collaboration from the United Kingdom and Ireland. *Gastrointest Endosc* 2022; 95: 432–442
- [29] Wells GA, Shea B, O'Connell D et al. The Newcastle-Ottawa Scale (NOS) for assessing the quality of nonrandomised studies in meta-analyses.
- [30] Dumonceau J-M, Kapral C, Aabakken L et al. ERCP-related adverse events: European Society of Gastrointestinal Endoscopy (ESGE) guideline. *Endoscopy* 2020; 52: 127–149
- [31] Binda C, Spadaccini M, Cugia L et al. EUS and ERCP partnership. *Endosc Ultrasound* 2022; 11: 426–427
- [32] Spadaccini M, Binda C, Fugazza A et al. Informed consent for endoscopic biliary drainage: time for a new paradigm. In: *Medicina (Kaunas)*. 2022; 58