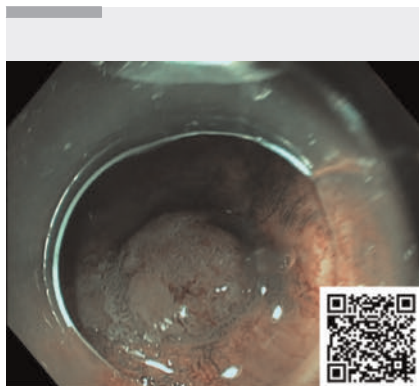


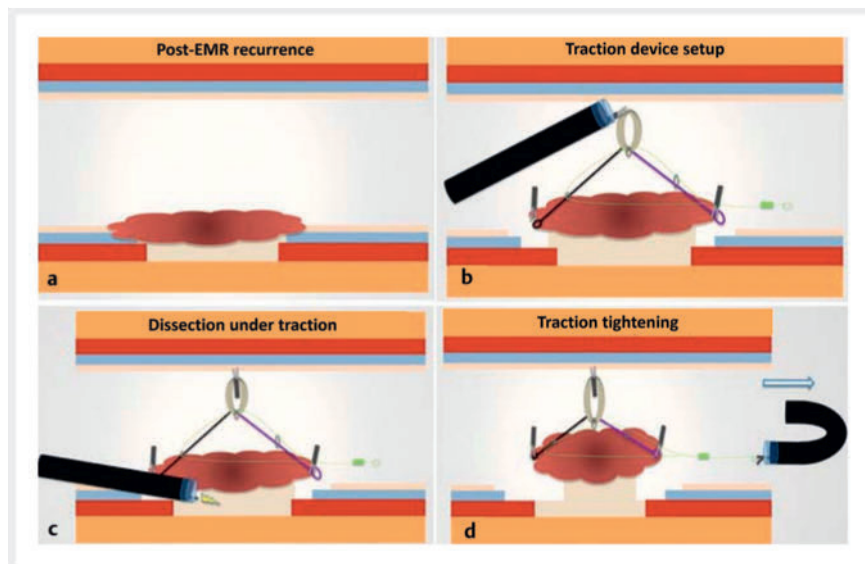
Endoscopic submucosal dissection for residual gastric lesion made easier thanks to use of adaptative traction device

OPEN
ACCESS



▶ Video 1 Adaptive traction device makes endoscopic submucosal dissection for residual gastric lesion easier.

European guidelines recommend endoscopic submucosal dissection (ESD) for gastric dysplastic lesions to ensure en bloc resection and for a lower risk of recurrence than endoscopic mucosal resection (EMR) [1]. However, this procedure is considered technically challenging especially for residual lesions in which the fibrosis after previous treatments can be found in the submucosal space and EMR is still performed with a local risk of recurrence. Herein, we report the case of a 66-year-old woman assessed for ESD of a residual dysplastic gastric lesion at the site of previous piecemeal EMR resection (posterior wall of antrum) (▶ **Video 1**). Several techniques, such as traction strategies, have already been described to facilitate these technically challenging procedures. In previous cases we reported the benefits of using a new adaptative multipolar traction system (A-TRACT) in different challenging resections. This device facilitates the dissection phase through exposing the submucosa and accelerating the procedure [2–5]. After circumferential incision with large margins and submucosal trimming, an adaptative traction device (A-TRACT 2) was used to improve submucosal exposure (▶ **Fig. 1**). The two loops were fixed



▶ Fig. 1 Schematic view after piecemeal endoscopic mucosal resection (EMR). **a** EMR recurrence. **b** Traction device setup. **c** Dissection under traction. **d** Device tightening to improve traction.

by clips at the edges of the lesion. The rubber band was fixed to the opposite wall to achieve 90° of traction and the dissection was started with traction. The device was tightened when exposure was poor, and the procedure was completed after 35 minutes with good submucosal exposure and no adverse events. Resection was R0 and the histopathology revealed an adenoma with low-grade dysplasia.

We can assume that this adaptative traction device can make ESD procedures feasible and faster, especially in selected cases like residual lesions, allowing curative endoscopic treatment.

Endoscopy_UCTN_Code_TTT_1AO_2AG_3AD

Conflict of Interest

Jérôme Rivory, Louis-Jean Masgnaux, Jean Grimaldi, Mathieu Pioche are co-founders of the ATRACT devices and co. Nothing to declare for the other authors

The authors

Elena De Cristofaro¹, Pierre Lafeuille², Jérôme Rivory², Jean Grimaldi², Louis Jean Masgnaux², Alexandru Lupu², Mathieu Pioche²

- 1 Gastroenterology Unit, University of Rome Tor Vergata, Rome, Italy
- 2 Gastroenterology and Endoscopy Unit, Edouard Herriot Hospital, Hospices Civils de Lyon, Lyon, France

Corresponding author

Mathieu Pioche, MD

Endoscopy Unit, Department of Digestive Diseases, Pavillon L – Edouard Herriot Hospital, Place Arsonval 5, 69437 Lyon Cedex, France
Mathieu.pioche@chu-lyon.fr

References

- [1] Pimentel-Nunes P, Libânio D, Bastiaansen BAJ et al. Endoscopic submucosal dissection for superficial gastrointestinal lesions: European Society of Gastrointestinal Endoscopy (ESGE) Guideline – Update 2022. *Endoscopy* 2022; 54: 591–622
- [2] Grimaldi J, Masgnaux L-J, Rivory J et al. Multipolar traction with adjustable force increases procedure speed during endoscopic submucosal dissection: the A-TRACT-4 traction device. *Endoscopy* 2022; 54: E1013–E1014
- [3] Masgnaux L-J, Grimaldi J, Rivory J et al. Endoscopic resection using adaptive traction for a large recurrence after a full-thickness transanal endoscopic microsurgery: improving exposure is a key point for complete removal. *Endoscopy* 2023; 55: E613–E614
- [4] De Cristofaro E, Rivory J, Masgnaux L-J et al. Multipolar traction with an eight-point adaptive traction device allowed comfortable resection of a challenging giant rectal lesion in ulcerative colitis. *Endoscopy* 2023; 55: E1029–E1030
- [5] De Cristofaro E, Masgnaux L-J, Saurin J-C et al. Multipolar adaptive traction makes endoscopic submucosal dissection feasible for large neoplastic area of the fundus in patient with familial adenomatous polyposis. *Endoscopy* 2023; 55: E963–E964

Bibliography

Endoscopy 2024; 56: E301–E302
 DOI 10.1055/a-2286-5543
 ISSN 0013-726X
 © 2024. The Author(s).

This is an open access article published by Thieme under the terms of the Creative Commons Attribution License, permitting unrestricted use, distribution, and reproduction so long as the original work is properly cited.

(<https://creativecommons.org/licenses/by/4.0/>)

Georg Thieme Verlag KG, Rüdigerstraße 14,
 70469 Stuttgart, Germany



ENDOSCOPY E-VIDEOS

<https://eref.thieme.de/e-videos>



E-Videos is an open access online section of the journal *Endoscopy*, reporting on interesting cases

and new techniques in gastroenterological endoscopy. All papers include a high-quality video and are published with a Creative Commons CC-BY license. *Endoscopy E-Videos* qualify for HINARI discounts and waivers and eligibility is automatically checked during the submission process. We grant 100% waivers to articles whose corresponding authors are based in Group A countries and 50% waivers to those who are based in Group B countries as classified by Research4Life (see: <https://www.research4life.org/access/eligibility/>).

This section has its own submission website at

<https://mc.manuscriptcentral.com/e-videos>