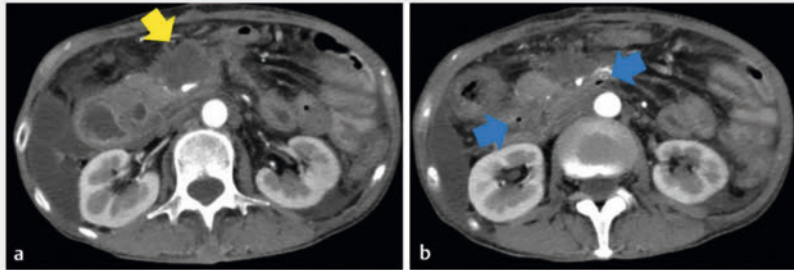
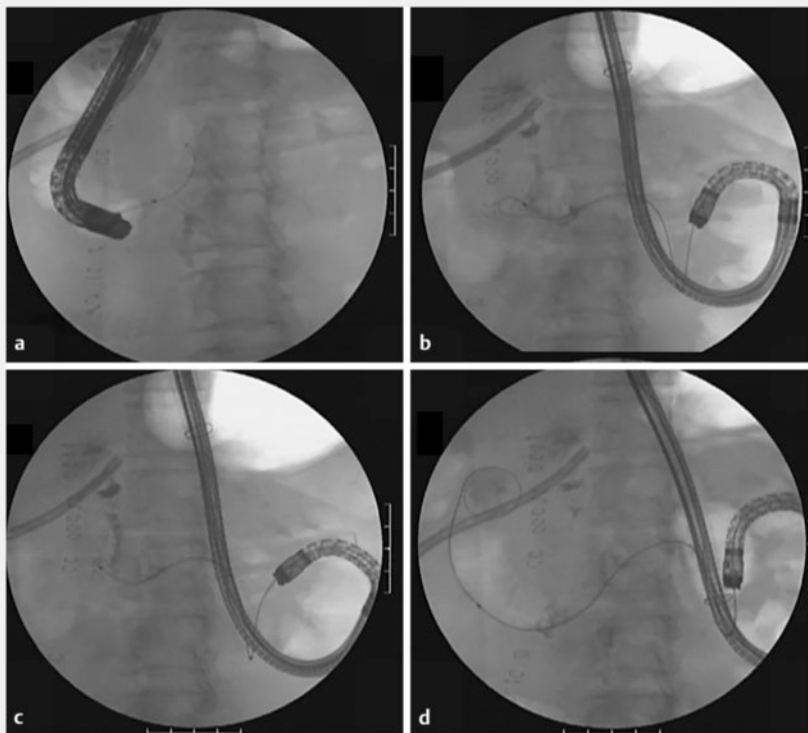


## Novel rendezvous technique for covered metal stent placement using balloon-assisted endoscope in duodenal perforation



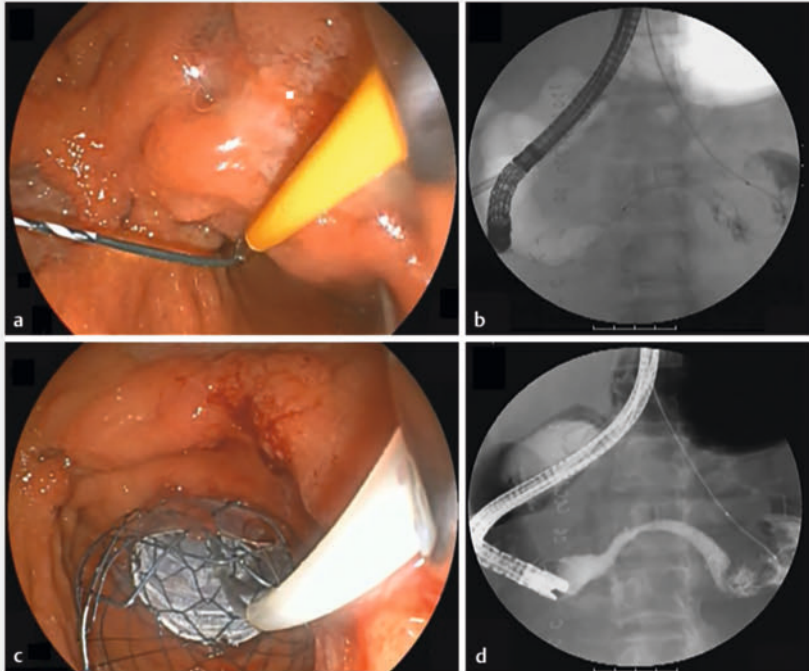
► **Fig. 1** Fluid collection (yellow arrow) and free air (blue arrow) were seen around the horizontal part of the duodenum.



► **Fig. 2** **a** The stenosis was so severe that the guidewire could not pass through. **b, c** We approached from the anorectal side through the gastrojejunal bypass. **d** The guidewire was passed through the stenosis using balloon-assisted endoscopy.

Duodenal perforations pose a significant medical challenge. While endoscopic closure can be attempted [1,2], these cases often necessitate surgical intervention [3]. In situations where surgery carries high risks, placing a covered metal stent offers a viable alternative [4,5]. This report describes the novel use of a covered metal stent, applied using the rendezvous technique, in treating a patient with duodenal perforation post-gastrojejunostomy (► **Video 1**).

A 62-year-old woman receiving chemotherapy for ascending colon cancer experienced deteriorating symptoms of gastrointestinal obstruction caused by duodenal stenosis and ascending colon stricture. Following a gastrojejunal bypass and ileo-transverse colon bypass, she was urgently admitted for perforation in the horizontal part of the duodenum (► **Fig. 1 a, b**). Initial attempts at surgical repair were challenging due to the perforation resulting from direct invasion by colon cancer and the inability to locate the perforation site because of severe adhesions. Consequently, closure of the perforation was attempted using a covered metal duodenal stent. However, endoscopic stenting from the oral side was difficult because the severe stenosis prevented passage of the guidewire, and the guidewire could easily exit into the abdominal cavity from the perforation site (► **Fig. 2 a**). Therefore, a balloon-assisted endoscope was used to enter via the anorectal route through the gastrojejunal bypass. This approach allowed the guidewire to pass through the stenosis (► **Fig. 2 b, c, d**). The guidewire was then grasped from the duodenal horn side and pulled out through the forceps channel (► **Fig. 3 a**). A covered Nitinol duodenal stent



► **Fig. 3** **a** The guidewire was grasped from the duodenal horn side. **b, c** A covered Nitinol duodenal stent was placed from the jejunum to the duodenal horn in a rendezvous technique. **d** No contrast medium flowed out of the gastrointestinal tract into the abdominal cavity.

(Taewoong Medical, Seoul, Korea) was subsequently positioned from the jejunum to the duodenal horn using the rendezvous technique (► **Fig. 3 b, c**). The procedure concluded after confirming the absence of leakage from the digestive tract into the abdominal cavity via contrast imaging (► **Fig. 3 d**). This case underscores the significance of advanced endoscopic techniques in managing patients for whom traditional surgical options are unsuitable.

Endoscopy\_UCTN\_Code\_TTT\_1AO\_2AI

### Conflict of Interest

Hirofumi Kogure received the honoraria from Gedelius Medical. All remaining authors declare that they have no conflict of interest.

### The authors

**Kei Saito<sup>1</sup>, Yoshitomo Ishikawa<sup>1</sup>, Mai Kitahara<sup>1</sup>, Shuzo Nomura<sup>1</sup>, Mariko Fujisawa<sup>1</sup>, Hirofumi Kogure<sup>1</sup>**

1 Division of Gastroenterology and Hepatology, Department of Internal Medicine, Nihon University School of Medicine, Tokyo, Japan

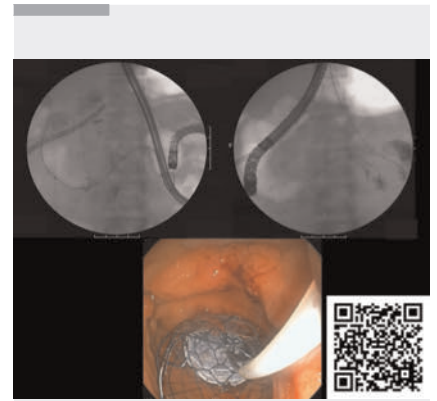
### Corresponding author

**Hirofumi Kogure, MD**

Division of Gastroenterology and Hepatology, Department of Internal Medicine, Nihon University School of Medicine, 30-1 Oyaguchi-Kamicho, Itabashi-ku, Tokyo 173-8610, Japan  
kogure.hirofumi@nihon-u.ac.jp

### References

- [1] Nakagawa Y, Nagai T, Soma W et al. Endoscopic closure of a large ERCP-related lateral duodenal perforation by using endoloops



► **Video 1** Covered metal duodenal stent placement using the rendezvous technique was performed for duodenal perforation in a patient with gastrojejunostomy.

and endoclips. *Gastrointest Endosc* 2010; 72: 216–217

- [2] Hayat M, Kadkhodayan K, Arain MA et al. Successful management of a duodenal perforation using a through-the-scope suturing device after failed attempt at closure with an over-the-scope clip. *VideoGIE* 2022; 8: 78–80
- [3] Ansari D, Torén W, Lindberg S et al. Diagnosis and management of duodenal perforations: a narrative review. *Scand J Gastroenterol* 2019; 54: 939–944
- [4] Bergström M, Arroyo Vázquez JA et al. Self-expandable metal stents as a new treatment option for perforated duodenal ulcer. *Endoscopy* 2013; 45: 222–225
- [5] Arroyo Vázquez JA, Khodakaram K, Bergström M et al. Stent treatment or surgical closure for perforated duodenal ulcers: a prospective randomized study. *Surg Endosc* 2021; 35: 7183–7190

### Bibliography

*Endoscopy* 2024; 56: E420–E421

DOI 10.1055/a-2313-3265

ISSN 0013-726X

© 2024. The Author(s).

This is an open access article published by Thieme under the terms of the Creative Commons Attribution License, permitting unrestricted use, distribution, and reproduction so long as the original work is properly cited.

(<https://creativecommons.org/licenses/by/4.0/>)

Georg Thieme Verlag KG, Rüdigerstraße 14, 70469 Stuttgart, Germany

