Thieme

Endoscopic ultrasound-guided gastroenterostomy to treat obstructive gastric twist after laparoscopic sleeve gastrectomy

Video 1 Endoscopic ultrasound-guided gastroenterostomy using wireless endoscopic simplified technique with oroenteric drain to treat gastric outlet obstruction due to gastric twist after sleeve gastrectomy.

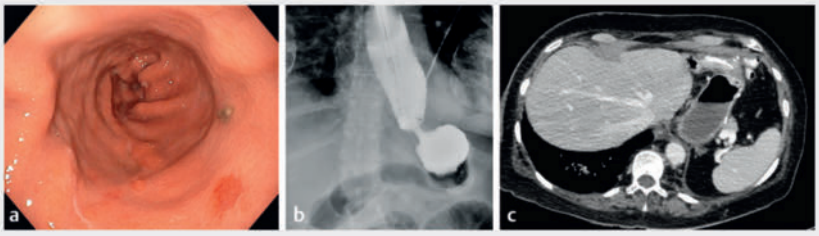

Fig. 1 Diagnosis of the gastric twist after sleeve gastrectomy. **a** Twist of the stapling line. **b** Esophageal dilation and distal gastric obstruction confirmed with endoscopic contrast injection. **c** Gastric outlet obstruction due to the gastric twist.

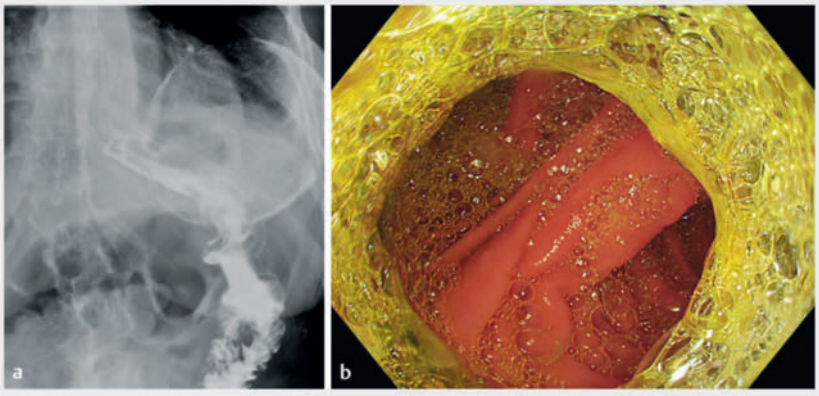

Fig. 2 Endoscopic and radiological imaging 3 months after endoscopic ultrasound-guided gastroenterostomy. **a** Contrast injection bypassing the gastric twist. **b** End-to-side gastroenterostomy with lumen-apposing metal stent.

Sleeve gastrectomy is the number one bariatric surgical intervention worldwide to treat morbid obesity. The rate of gastric stenosis after sleeve gastrectomy is around 2 to 4% [1,2]. A gastric twist represents a functional gastric stenosis. Endoscopic management with pneumatic dilation or stent is proposed as first-line therapy [1–3]. In case of failure, a surgical conversion to Roux-en-Y gastric bypass (RYGB) is performed. Endoscopic ultrasound-guided gastroenterostomy (EUS-GE) using an oroenteric catheter is a new approach to treat a benign gastric outlet obstruction (GOO) [4,5]. We report the case of a patient with a gastric twist after laparoscopic sleeve gastrectomy successfully treated with EUS-GE after failure of repeat endoscopic dilatation.

A 69-year old woman underwent sleeve gastrectomy. One month later, she presented symptoms of GOO with a gastric outlet obstruction scoring system (GOOSS) score of 1. Endoscopy showed peptic esophagitis associated with a mid-gastric twist (**Fig. 1 a, b**) confirmed by computed tomography scan (**Fig. 1 c**). Three sessions of endoscopic dilatation were performed without clinical improvement. An EUS-GE was proposed to "bypass" the mid-gastric twist (**Video 1**). An oroenteric catheter was placed over a guidewire to fill the jejunal lumen. Next, the target jejunal limb was identified by EUS and punctured with the electrocautery-enhanced lumen-apposing metal stent (LAMS) in pure cut mode. The LAMS was deployed connecting the gastric and jejunal lumen without adverse events. Clinical improvement with a GOOSS score of 3 was reported and confirmed by radiology and endoscopy at 1 and 3 months (**Fig. 2 a, b**).

The management of a gastric twist with clinical implications after sleeve gastrectomy is challenging. The improved technical and clinical success of EUS-GE has allowed it to be used in case of a benign GOO due to gastric twist. Moreover, EUS-GE avoided surgical conversion to RYGB. Future studies are needed to define what to do with the LAMS in case of benign gastric outlet obstruction: remove it, replace it, or leave it.

Endoscopy_UCTN_Code_TTT_1AS_2AK

Conflict of Interest

LM is consultant for Prion Medical and Braun Medical and received speaker's fees from Olympus Belgium and Olympus Europe. PHD is consultant for Boston Scientific TGM received speaker's fees from Olympus Belgium and Olympus Europe. Others authors declare that they have no conflict of interest.

The authors

Laurent Monino[1], Yannick Deswysen[2], Maximilien Thoma[2], Pierre H. Deprez[1], Tom Moreels[1]

1 Department of Gastroenterology & Hepatology, Cliniques universitaires Saint-Luc, Université catholique de Louvain, Brussels, Belgium

2 Department of Digestive Surgery, Cliniques universitaires Saint-Luc, Université catholique de Louvain, Brussels, Belgium

Corresponding author

Laurent Monino, MD
Department of Hepatogastroenterology, Université catholique de Louvain, Cliniques universitaires Saint-Luc, Avenue Hippocrate 10, 1200 Brussels, Belgium
laurent.monino@saintluc.uclouvain.be

References

[1] Rebibo L, Hakim S, Dhahri A et al. Gastric stenosis after laparoscopic sleeve gastrectomy: diagnosis and management. Obes Surg 2016; 26: 995–1001. doi:10.1007/S11695-015-1883-4

[2] Hassan MI, Khalifa MS, Elsayed MA et al. Role of endoscopic stent insertion on management of gastric twist after sleeve gastrectomy. Obes Surg 2020; 30: 2877–2882. doi:10.1007/S11695-020-04641-X

[3] Spota A, Cereatti F, Granieri S et al. Endoscopic management of bariatric surgery complications according to a standardized algorithm. Obes Surg 2021; 31: 4327–4337. doi:10.1007/S11695-021-05577-6

[4] Nguyen NQ, Hamerski CM, Nett A et al. Endoscopic ultrasound-guided gastroenterostomy using an oroenteric catheter-assisted technique: a retrospective analysis. Endoscopy 2021; 53: 1246–1249. doi:10.1055/A-1392-0904

[5] Monino L, Perez-Cuadrado-Robles E, Gonzalez JM et al. Endoscopic ultrasound-guided gastroenterostomy with lumen-apposing metal stents: A retrospective multicentric comparison of wireless and over-the-wire techniques. Endoscopy 2022; 55: 991–999. doi:10.1055/a-2119-7529

Bibliography

Endoscopy 2024; 56: E591–E592
DOI 10.1055/a-2333-9183
ISSN 0013-726X

Georg Thieme Verlag KG, Rüdigerstraße 14, 70469 Stuttgart, Germany