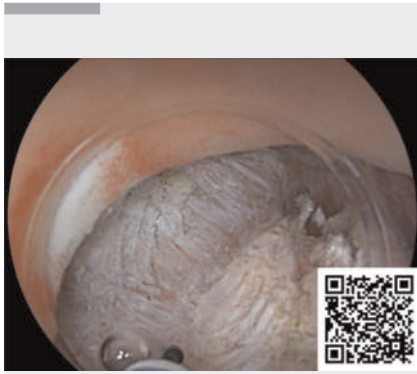
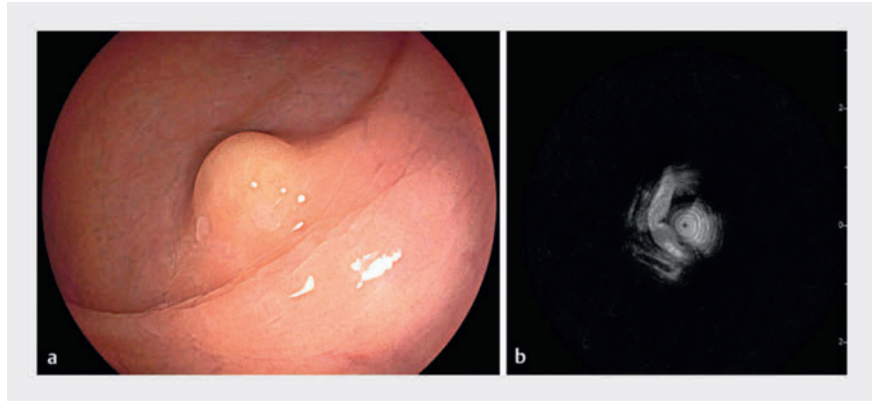


Efficacy of underwater endoscopic intermuscular dissection in the management of a rectal neuroendocrine tumor



▶ Video 1 The effectiveness of underwater endoscopic intermuscular dissection in the management of rectal neuroendocrine tumors.



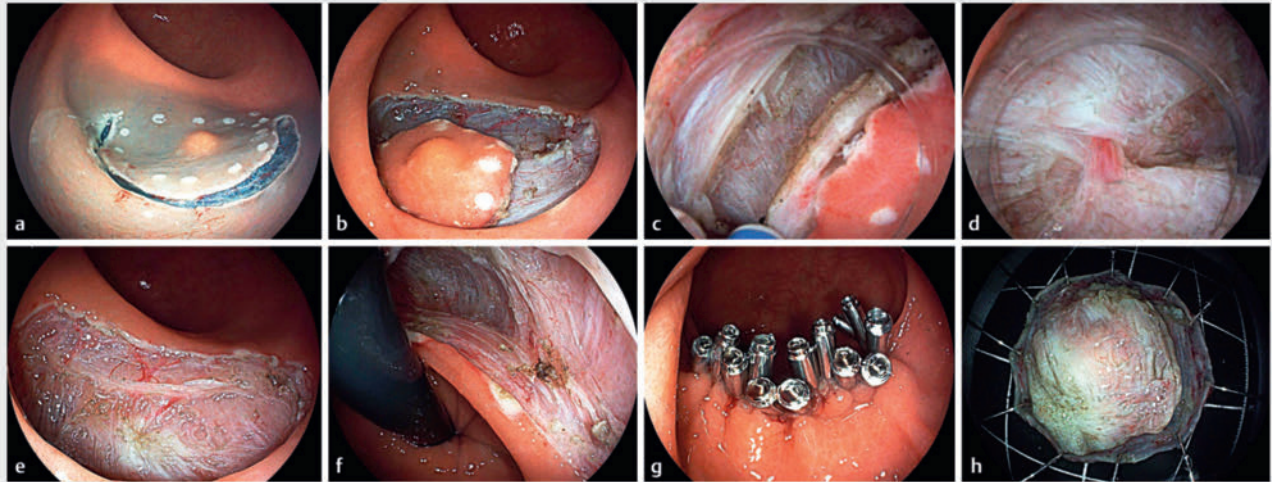
▶ Fig. 1 A subepithelial lesion in the rectum, measuring approximately 7 mm in diameter. **a** On endoscopy, the lesion had a yellowish appearance. **b** Endoscopic ultrasound indicated the lesion's location in the deep mucosal and submucosal layers, adjacent to the muscularis propria.

Endoscopic intermuscular dissection (EID), which is emerging as a therapeutic modality, has garnered recent attention for its efficacy in reducing positive vertical margins, particularly in the management of neuroendocrine tumors (NETs) [1–3]. EID procedures are intricate, requiring precise differentiation of the intermuscular space. Herein, we endeavor to employ underwater EID (U-EID) techniques to enhance procedural efficacy. A 66-year-old woman presented with a subepithelial lesion in the rectum, measuring approximately 7 mm in diameter with a yellowish appearance (▶ **Fig. 1 a**). Endoscopic ultrasound indicated the lesion's location in the deep mucosal and submucosal layers, adjacent to the muscularis propria (▶ **Fig. 1 b**). Consequently, U-EID was chosen as the preferred therapeutic approach (▶ **Fig. 2**, ▶ **Video 1**). The patient underwent endotracheal intubation under general anesthesia. Mark-

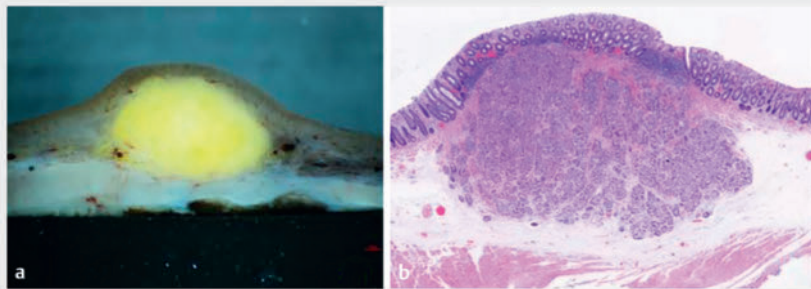
ing, submucosal injection, and mucosal incision procedures were performed similarly to endoscopic submucosal dissection (ESD). Following exposure of the muscularis propria, an ST-Hood (DH-33GR; Fujifilm, Tokyo, Japan) was attached to the tip of the endoscope. Subsequently, the circular muscle was incised circumferentially with a 2-mm knife (ORISE ProKnife; Boston Scientific, Marlborough, Massachusetts, USA) under saline solution immersion, thereby unveiling the intermuscular space. Dissection within the intermuscular space was performed until the tumor was completely dissected. Postoperative histopathologic examination revealed a well-differentiated NET (grade 1), with negative horizontal and vertical margins (▶ **Fig. 3**). The patient was discharged after 72 hours, with no adverse events. Underwater ESD has been documented in the literature [4, 5]. Employing water

methodologies during EID procedure unveils distinct advantages. The intrinsic buoyancy of water, combined with its magnifying properties, enhances the differentiation of the intermuscular spaces. This heightened clarity facilitates the seamless and expeditious dissection of muscular layers, enabling precise visualization of pulsatile vasculature, thereby facilitating timely interventions to mitigate hemorrhagic complications. The duration of the surgery was 40 minutes. To the best of our knowledge, this case represents the first reported instance of a rectal NET treated with U-EID, thereby substantiating the efficacy and safety of implementing U-EID in the management of rectal diseases.

Endoscopy_UCTN_Code_TTT_1AQ_2AD_3AD



► **Fig. 2** The process of underwater endoscopic intermuscular dissection. **a** Circumferential electrocoagulation was used to mark the edges of the lesion, followed by submucosal injection with normal saline and indigo carmine. **b** Circumferential incision was performed outside the markers, until the muscle layer was exposed. **c** Muscle fibers of the circular part of the muscle layer were cut off to gain access to the intermuscular space under water immersion. **d** Blood vessels were distinctly observable under water immersion. **e, f** Postoperative defect showing longitudinal muscle with no perforations and absence of circular muscle. **g** Closure of the defect with metal clips. **h** The resected tumor exhibited distinctly discernible muscular layers.



► **Fig. 3** The tumor specimen. **a** The excised tumor after 24 hours of fixation. It presented a yellowish hue, with intrinsic muscular layers visible underneath when viewed from the side. **b** A well-differentiated neuroendocrine tumor (grade 1), with negative horizontal and vertical margins.

- 2 Department of Nephrology and Rheumatology, Shenzhen Hospital of Integrated Traditional Chinese and Western Medicine, Shenzhen, China
- 3 Department of Anesthesiology, South China Hospital, Medical School, Shenzhen University, Shenzhen, China

Corresponding author

Silin Huang, MD

Department of Gastroenterology, South China Hospital, Medical School, Shenzhen University, No. 1 Fuxin Road, Longgang Distric, Shenzhen, China 518116
silinhuang@szu.edu.cn

Funding Information

Guangdong Province Clinical Teaching Base Teaching Reform Research Project 2021JD086

National Natural Science Foundation of China
82341019

Conflict of Interest

The authors declare that they have no conflict of interest.

The authors

Suhuan Liao¹, Silin Huang¹, Guang Yang¹, Bo Li¹, Huizhao Deng², Yi Tan³, Guifa He¹

- 1 Department of Gastroenterology, South China Hospital, Medical School, Shenzhen University, Shenzhen, China

References

- [1] Liao S, Li B, Huang L et al. Endoscopic intermuscular dissection in the management of a rectal neuroendocrine tumor. *Endoscopy* 2023; 55: E977–E979. doi:10.1055/a-2139-4310
- [2] Moons LMG, Bastiaansen BAJ, Richir MC et al. Endoscopic intermuscular dissection for deep submucosal invasive cancer in the rectum: a new endoscopic approach. *Endoscopy* 2022; 54: 993–998. doi:10.1055/a-1748-8573

- [3] De Cristofaro E, Rivory J, Masgnaux JL et al. Repeat endoscopic intermuscular dissection of the visible scar after noncurative endoscopic intermuscular dissection of a rectal neuroendocrine tumor. *Endoscopy* 2024; 56: E205–E206. doi:10.1055/a-2261-7919
- [4] Huang S, Tan L, Liao S et al. Underwater endoscopic submucosal dissection with dental floss traction for the treatment of early pharyngeal cancer. *Endoscopy* 2023; 55: E1184–E1185
- [5] Muramatsu T, Tashima T, Ishikawa T et al. Successful underwater endoscopic submucosal dissection with gel immersion for early gastric cancer in an upside-down stomach. *Endoscopy* 2024; 56: E258–E259

Bibliography

Endoscopy 2024; 56: E524–E526

DOI 10.1055/a-2333-9660

ISSN 0013-726X

© 2024. The Author(s).

This is an open access article published by Thieme under the terms of the Creative Commons Attribution License, permitting unrestricted use, distribution, and reproduction so long as the original work is properly cited.

(<https://creativecommons.org/licenses/by/4.0/>)

Georg Thieme Verlag KG, Rüdigerstraße 14,
70469 Stuttgart, Germany



ENDOSCOPY E-VIDEOS

<https://eref.thieme.de/e-videos>



E-Videos is an open access online section of the journal *Endoscopy*, reporting on interesting cases and new techniques in gastroenterological endoscopy. All papers include a high-quality video and are published with a Creative Commons CC-BY license. Endoscopy E-Videos qualify for HINARI discounts and waivers and eligibility is automatically checked during the submission process. We grant 100% waivers to articles whose corresponding authors are based in Group A countries and 50% waivers to those who are based in Group B countries as classified by Research4Life (see: <https://www.research4life.org/access/eligibility/>).

This section has its own submission website at <https://mc.manuscriptcentral.com/e-videos>