Article published online: 2024-07-22

The impact of V-flow on preoperative diagnosis of thyroid tumors: individually and as part of multimodal sonographic imaging

Die Bedeutung des neuen V-flow Modus bei der präoperativen Diagnostik von soliden Schilddrüsentumoren: allein und als Bestandteil multimodaler Ultraschalldiagnostik

Authors

Moritz Konstantin Brandenstein[1], Liang Zhang[1], Gregor Scharf[1], Sylvia Thurn[1], Matthias Hornung[2], Karin Menhart[3], Stefanie Meiler[1], Christian Stroszczynski[1], Ernst Michael Jung[1]

Affiliations

1 Radiology, University Hospital Regensburg, Regensburg, Germany
2 Surgery, University Hospital Regensburg, Regensburg, Germany
3 Nuclear Medicine, University Hospital Regensburg, Regensburg, Germany

Keywords

thyroid, V-flow, hemodynamics/flow dynamics, multimdodal sonographic imaging, adenocarcinoma, microvascularization

received 25.1.2024
accepted after revision 11.6.2024
published online 22.7.2024

Bibliography

Rofo 2025; 197: 436–446
DOI 10.1055/a-2350-0107
ISSN 1438-9029

Georg Thieme Verlag KG, Oswald-Hesse-Straße 50, 70469 Stuttgart, Germany

Correspondence

Moritz Konstantin Brandenstein
Radiology, University Hospital Regensburg, Regensburg, Germany
moritz.brandenstein@stud.uni-regensburg.de
Moritzbrandenstein@googlemail.com

ABSTRACT

Purpose V-flow is a dynamic ultrasound technique that visualizes perfusion patterns by displaying dynamic arrows that change in response to the flow of erythrocytes. Furthermore, it provides quantitative values for the maximum and mean velocity of blood flow as well as a percentage value for turbulence. The aim was to enhance the preoperative diagnostic accuracy of thyroid lesions by combining V-flow with established ultrasound modes.

Materials and Methods B-mode, CCDS, elastography, CEUS, and V-flow were performed on 101 patients. After the ultrasound examination, every nodule was confirmed as benign or malignant via histopathology. The Kruskal–Wallis test, ROC curve, and binary logistic regression were used for the statistical analysis.

Results 93 benign regressive thyroid nodules and 8 carcinomas were included in this study. The average mean velocity value for benign lesions was measured at 19.5 cm/s and at 10.7 cm/s for malignant lesions ($p = 0.039$). The average turbulence percentage was 26.1 % for benign nodules and 46.7 % for carcinomas ($p = 0.016$). Carcinomas exhibited a slower and more turbulent perfusion pattern compared to benign tumors. A V-flow-centered system achieves a sensitivity of 100.0 % and a specificity of 84.9 % in predicting malignancy. This system could have reduced the number of unnecessary thyroid surgeries for benign lesions in our patient group by 70 %.

Conclusion The capillary perfusion of thyroid nodules represents a significant indicator of its status. By analyzing the velocity and turbulence level of microvascular blood flow, V-flow offers promising prospects for accurately distinguishing between benign and malignant thyroid lesions. When integrated into a comprehensive multimodal sonographic imaging approach, V-flow further enhances diagnostic accuracy.

Key Points

- V-flow allows for qualitative and quantitative analysis of microvascular perfusion
- Malignant tumors are associated with slower and more turbulent microvascular hemodynamics
- Combining V-flow with other ultrasound modes eases the diagnosis of thyroid carcinomas

Citation Format

- Brandenstein MK, Zhang L, Scharf G et al. The impact of V-flow on preoperative diagnosis of thyroid tumors: individually and as part of multimodal sonographic imaging. Rofo 2025; 197: 436–446

ZUSAMMENFASSUNG

Ziel V-flow ist ein neuer dynamischer Ultraschallmodus, der Perfusion auf Kapillarebene darstellen kann. Hierfür werden Vektoren abgebildet, die sich abhängig von der Erythrozytenbewegung ändern. Des Weiteren liefert V-flow quantitative

Werte für die mittlere und maximale Geschwindigkeit des Blutstroms sowie einen Prozentwert für den Grad an Turbulenzen im untersuchten Gebiet. Das Ziel dieser Studie war es, mithilfe dieses neuen Ultraschallmodus die präoperative Diagnostik solider Schilddrüsenknoten zu verbessern.

Material und Methoden 101 Patienten wurden sonografisch umfassend untersucht. Danach wurde jeder Knoten histopathologisch als benigne oder maligne gesichert. Die statistische Analyse erfolgte mithilfe von Kruskal–Wallis Test, ROC-Kurve und binär logistischer Regression.

Ergebnisse 93 gutartige Schilddrüsenknoten und 8 Karzinome wurden in diese Studie aufgenommen. Die durchschnittlich gemessene Geschwindigkeit lag bei 19,5 cm/s für gutartige und bei 10,7 cm/s für bösartige Knoten (p = 0,039). Der durchschnittliche Grad der Turbulenz betrug 26,1 % für gutartige und 46,7 % für bösartige Schilddrüsenläsionen (p = 0,016). Die Karzinome zeigten ein langsameres und turbulenteres Durchblutungsmuster. Durch Kombination verschiedener V-flow-Malignitätskriterien erstellten wir ein System zur Differenzierung zwischen gut- und bösartigen Schilddrüsenknoten (Sensitivität = 100 %; Spezifität = 84,9 %). Die Anwendung dieses Systems hätte die Anzahl nicht notwendiger Schilddrüsenoperationen bei gutartigen Knoten in diesem Kollektiv um 70 % reduziert.

Schlussfolgerung Die Mikrovaskularisation von Schilddrüsenknoten stellt einen wichtigen Indikator für seine Malignität dar. Durch die detaillierte Analyse von Flussgeschwindigkeit und Turbulenzen auf kapillärer Ebene trägt V-flow wesentlich zu präoperativen sonografischen Differenzierung von Schilddrüsenknoten als benigne oder maligne bei. Durch die Kombination bereits etablierter Ultraschallmodi mit dem V-flow kann die diagnostische Treffsicherheit bei der Diagnostik von Schilddrüsentumoren gesteigert werden.

Kernaussagen

- V-flow ermöglicht eine qualitative und quantitative Analyse kapillärer Perfusion.
- Karzinome imponieren durch eine turbulente Mikrovaskularisation mit langsamem Blutfluss.
- Die Kombination von V-flow mit anderen Ultraschallmodi erleichtert die Diagnostik von Schilddrüsenkarzinomen.

Introduction

In recent years the incidence of thyroid carcinoma has been on the rise, reaching up to 10 per 100,000 women and 3 per 100 000 men in 2020 – while its relative share among all malignant tumors has remained relatively stable at approximately 1 percent [1]. Unfortunately, as the number of diagnosed thyroid tumors rises, there is a corresponding increase in the number of thyroid surgeries, resulting in a higher incidence of complications. These complications include recurrent laryngeal nerve damage resulting in dysphonia, post-surgical hypoparathyroidism as well as aesthetic damage due to surgical scars [2]. To reduce these undesired side effects, it is crucial to improve the noninvasive diagnostic workup of thyroid nodules, thereby allowing precise identification of malignant thyroid lesions and ensuring surgical removal is limited exclusively to necessary cases.

Ultrasound imaging of the thyroid gland plays a pivotal role in evaluating thyroid nodules, enabling the differentiation between benign nodules and those with malignant characteristics. Various classification systems, such as the well-known TI-RADS classification, have been established for this purpose [3]. The TI-RADS classification is a five-point classification system using ultrasound criteria to assess thyroid nodules. However, it is worth noting that intranodular perfusion is not currently considered as a criterion within the TI-RADS classification.

Nevertheless, the perfusion or hemodynamic alteration within a tumor serves as an indicator of its status [4, 5]. There are several established sonographic modes showing the blood flow in and around possible malignant lesions: Color-coded Doppler sonography (CCDS) and high-resolution flow (HR Flow) can detect macrovascularization [6]. After injecting a contrast agent, contrast-enhanced ultrasound (CEUS) can depict perfusion patterns including smaller blood vessels [7, 8]. The new V-flow mode goes beyond these techniques by providing dynamic visualization of microvascularization up to capillary perfusion, even showing the movement of single erythrocytes [9, 10, 11, 12]. Despite not being incorporated into the TI-RADS classification, intranodular perfusion holds promise as an additional criterion for enhancing the accuracy of thyroid nodule assessment.

Up to this point vector flow (V-flow) was only utilized to assess large brain-supplying arteries and veins [12]. This study represents the first documented analysis of V-flow in the assessment of solid thyroid tumors. The aim of this study was to investigate whether the new V-flow mode contributes to a more precise preoperative differentiation of thyroid lesions, thereby reducing unnecessary thyroid surgery and fine needle aspiration (FNA) procedures. We reviewed various qualitative and quantitative V-flow findings based on their ability to predict thyroid lesions as benign or malignant.

By combining V-flow with existing ultrasound modes, our aim was to enhance the sensitivity of ACR and EU-TI-RADS from 78–88 % to the level of cytology, which typically ranges from 76–98 % [13, 14, 15].

Materials and Methods

The retrospective study was approved by the local ethics committee.

The inclusion criteria of this study were the same as those used for operative (hemi-)thyroidectomy, which were defined in-house. These criteria comprised lymph node metastases potentially originating from the thyroid gland, symptoms such as breathing and swallowing difficulties, elevated levels of calcitonin tumor marker in the blood count, suspicious preliminary sonographic examina-

▶ **Table 1** Absolute and percentage study inclusion criteria.

Inclusion criteria	Absolute number	Percentage	Notes
Lymph node metastases possibly originating from thyroid	4	4.0 %	3 derived from thyroid cancer
Elevated calcitonin levels in blood count	2	2.0 %	Allowed for the detection of the 3 mm medullary microcarcinoma
TI-RADS IV or V	61	60.4 %	Most frequent inclusion criterion
Cold node on scintigraphy	27	26.7 %	Scintigraphy was only performed on lesions ≥ TI-RADS III
Breathing/swallowing difficulties	12	11.9 %	

tions resulting in a TI-RADS IV or V rating, or lesions appearing as a cold node on scintigraphy. The frequency of these inclusion findings among the 101 patients is displayed in ▶ **Table 1**.

A total of 101 patients with suspicious non-cystic and solid thyroid lesions were consecutively enrolled from Jan. 1, 2023 to Aug. 31, 2023 in this retrospective study. The examinations were conducted using a high-performance ultrasound device (Resona 7/R9; Mindray, Shenzen, China) equipped with a multifrequency matrix linear probe (Mindray L9–3U Linear Array transducer, 3 to 7.0 MHz). The examinations were documented as single pictures or cine-loops, which were saved as digital DICOM files.

The size of each thyroid gland and its nodules was measured in three dimensions. The morphology of the lesion on B-mode was assessed using EU-TI-RADS criteria [3].

V-flow examination technique

V-flow visualizes blood flow patterns with a frequency of 6 to 8 MHz by featuring arrows that differ in number, direction, length, location, and color. Additionally, it provides quantitative data on the degree of turbulence. In V-flow, three main types of arrows or vectors are observed: short green arrows as well as yellow and red vectors indicating flow moves forward from the dotted green arrows in the frame [9]. For each V-flow examination an adjustable window was set on the respective thyroid nodule. The sonomorphological hemodynamics of the lesion in V-flow were assessed by the following predicted malignancy criteria: turbulence (vectors running in opposite directions) both inside and outside the adjustable window as well as lack of red vectors within the V-flow window.

In terms of quantitative data, the study focused on the maximum and mean velocity [cm/s] of blood flow as well as the degree of turbulence [%] at the point of maximum velocity. Both qualitative and quantitative data were reproducible by two separate investigators. Since no prior experience with the application of V-flow for a thyroid gland has been reported, the technical preset of this mode had to be modified for both high-flow arteries and low-flow veins [10, 12]. 23 cm/s was the lowest velocity V-flow was able to measure. Considering that carcinomas tend to exhibit inhomogeneous blood vessels with a chaotic slow flow, we anticipated that the V-flow mode would show more non-directional green and yellow arrows in malignant tumors compared to benign tumors and healthy thyroid tissue [16].

It is important to note that V-flow was always part of a comprehensive multimodal sonographic examination that also included B-mode, CCDS, shear-wave elastography, and CEUS [7]. By combining the new V-flow mode with established sonographic techniques, morphological and hemodynamic alterations of blood vessels can be analyzed more extensively.

Statistical analysis

Statistical analyses were conducted using SPSS 28.0 (SPSS Inc., Chicago, IL, USA). The Kruskal–Wallis test was utilized to compare the measured values between the benign and malignant nodules and to determine statistical significance. Probabilities less than 0.05 were considered to be statistically significant. The ROC curve and the Youden's J statistic were employed to calculate cut-off values with a high sensitivity and specificity for the quantitative V-flow data including: maximum velocity [cm/s], mean velocity [cm/s], and turbulence [%] at the point of maximum velocity. Binary logistic regression was used to determine the diagnostic odds ratio (DOR).

Results

101 patients (38 males, 63 females) with an age range of 27 to 85 years and a mean age of 58 ± 16 years were included in this study. Inter- or postoperative histopathological analysis showed 93 benign thyroid nodules and 8 carcinomas. Among the carcinomas, 6 were identified as papillary and 2 as medullary thyroid carcinomas. All carcinomas were surgically removed via thyroidectomy. The diameters of the benign regressive thyroid nodules ranged from 4 to 104 mm, with a mean diameter of 22 ± 15 mm. On the other hand, the diameter of the carcinomas ranged from 3 to 16 mm, with a mean diameter of 9 ± 4 mm.

Hemodynamic V-flow findings

Turbulence occurred five times more often in carcinomas (87.5 %) than in benign nodules (17.2 %), as shown in ▶ **Table 2**. Furthermore, the carcinomas exhibited a lack of red fast arrows nearly twice as often and turbulence close to them occurred more than twice as frequently when compared to benign nodules. Examples illustrating these findings can be seen in ▶ **Fig. 1**, ▶ **Fig. 2** and ▶ **Fig. 3**.

▶ **Fig. 1** depicts the V-flow and B-mode image of a histopathologically proven thyroid carcinoma. The malignant lesion exhibits

▶ **Table 2** Frequency of malignant V-flow findings in benign and malignant thyroid nodules.

V-flow findings	Benign	Malignant
Turbulence within the lesion	17.2 %	87.5 %
Turbulence near the lesion	29.0 %	75 %
No red arrows within the lesion	39.8 %	75 %

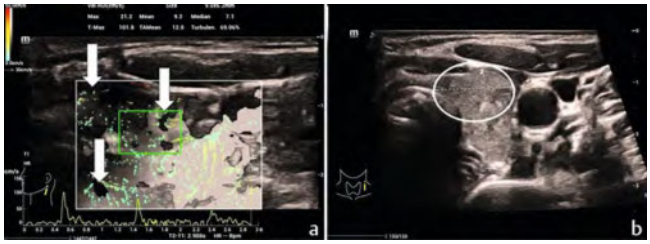

▶ **Fig. 1** V-flow examination of a left thyroid lobe with a TI-RADS V thyroid tumor (papillary thyroid carcinoma): Green and yellow but no red arrows within the lesion. Turbulences in and around the lesion (white arrows) in V-low **a**. The lesion (white circle) shows mixed echogenicity, microcalcifications, and a diffuse edge demarcation in B-mode **b.**

▶ **Fig. 2** V-flow examination of a left thyroid lobe with a TI-RADS III benign thyroid nodule: Green, yellow, and red arrows streaming linearly in the same direction (white arrow). No turbulence inside or outside the examination window in V-flow **a**. The lesion (white circle) presents with hyperechoic edge demarcation but without microcalcifications in B-mode **b.**

characteristic malignant features, including the presence of turbulence. This turbulence is represented by vectors positioned close together, running in different directions both within and outside of the lesion. Furthermore, within the examination window covering the lesion, green and yellow arrows are observed, while red arrows are absent.

▶ **Fig. 2** shows the V-flow and B-mode examination of a histopathologically proven benign regressive thyroid nodule. The blood stream within the benign lesion appears homogeneous, without any significant turbulence within or outside the examination window. All vectors are observed to flow in the same direction. Notably, fast red vectors were observed within the benign nodule.

▶ **Fig. 3** pictures the V-flow examination of a right thyroid lobe without any lesions. No vectors appear within the healthy thyroid tissue.

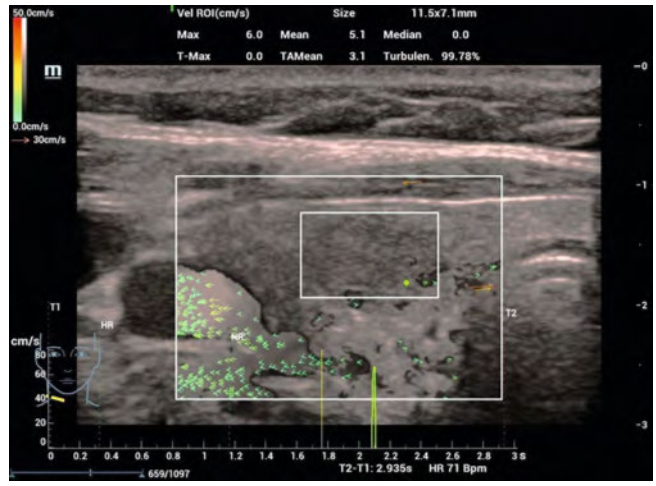

▶ **Fig. 3** V-flow examination of a right thyroid lobe without any lesion or nodule: Vectors only appear along the edges of the thyroid gland or in nearby blood vessels but not within the thyroid gland.

▶ **Table 3** Average absolute velocity [cm/s] and turbulence [%] measurements in benign and malignant thyroid nodules and their *p*-value.

V-flow measurements	Malignant (n ± STD)	Benign (n ± STD)	*p*
Maximum velocity [cm/s]	48.9 ± 46.2	74.9 ± 40.3	0.062
Mean velocity [cm/s]	10.7 ± 3.7	19.5 ± 14.0	0.039
Turbulence [%]	46.7 ± 20.9	26.1 ± 21.7	0.016

Maximum velocity, mean velocity, and turbulence measurements

▶ **Table 3** summarizes the results of the quantitative V-flow measurements including maximum velocity [cm/s], mean velocity [cm/s] of blood flow, and the degree of turbulence [%] at the point of maximum velocity. Benign regressive thyroid nodules exhibit higher maximum and mean velocity, along with lower standard deviations, indicating a faster and more homogeneous blood stream in benign lesions. On the other hand, carcinomas display a higher mean degree of turbulence compared to benign lesions. The highest turbulence value of 94.4 % at the point of maximum velocity was also measured in a thyroid carcinoma. Therefore, carcinomas usually show a slow, inhomogeneous, and turbulent blood flow. Statistical analysis reveals significant differences between the two groups in terms of mean velocity ($p = 0.039$) and turbulence ($p = 0.016$), while the difference in maximum velocity is not statistically significant ($p = 0.062$).

Examples illustrating these findings are provided in ▶ **Fig. 4** and ▶ **Fig. 5**.

▶ **Fig. 4** depicts the V-flow examination of a histopathologically proven medullary thyroid carcinoma. The mean velocity meas-

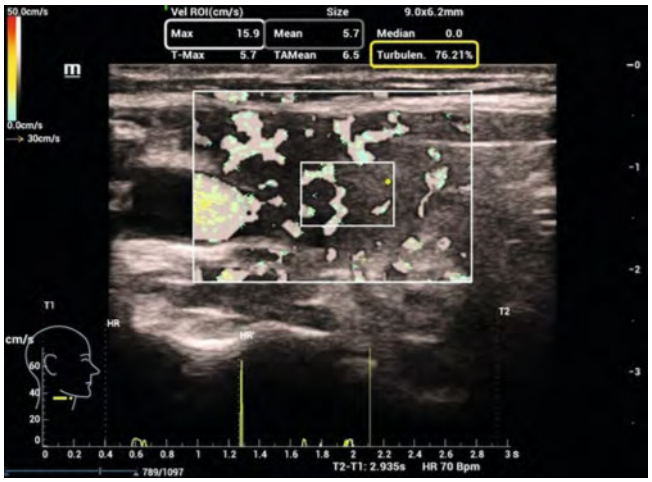

▶ **Fig. 4** V-flow examination of a right thyroid lobe with a TI-RADS V tumor, later identified as medullary thyroid carcinoma: Results of the quantitative measurements, including maximum velocity [cm/s] (white box), mean velocity [cm/s] (grey box), and turbulence [%] (yellow box) displayed above the ultrasound examination window. Mean velocity measurement value: 5.7 cm/s. Maximum velocity measurement: 15.9 cm/s. Degree of turbulence: 76.2 % at the point of maximum velocity.

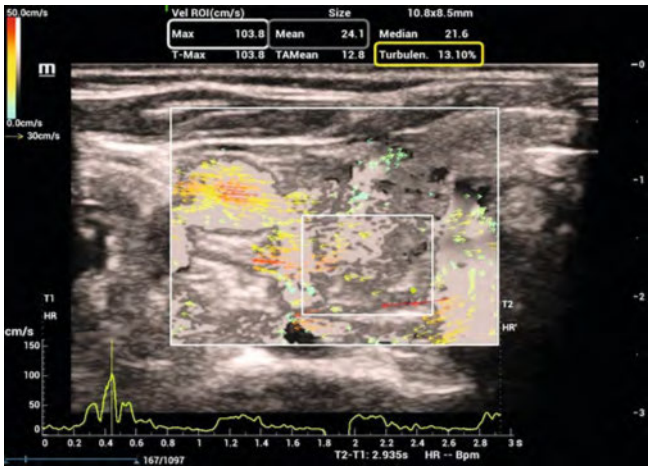

▶ **Fig. 5** V-flow examination of a right thyroid lobe with a benign TI-RADS III thyroid nodule. Results of the quantitative measurements, including maximum velocity [cm/s] (white box), mean velocity [cm/s] (grey box) and turbulence [%] (yellow box) depicted above the ultrasound examination window. Mean velocity value: 24.1 cm/s. Maximum velocity value: 103.8 cm/s. Degree of turbulence: 13.1 % at the point of maximum velocity.

▶ **Table 4** Nominal V-flow findings and cut-off values with their diagnostic accuracy, DOR, sensitivity, and specificity.

V-flow findings		Diagnostic accuracy (%)	Diagnostic Odds Ratio	Sens. (%)	Spec. (%)
Turbulence within the lesion		83.2	33.69	87.5	82.8
Turbulence near the lesion		71.3	17.11	75.0	70.1
Lack of red arrows within the lesion		61.4	4.75	75.0	60.2
Mean velocity [cm/s]	Cut-off: 12.3 cm/s	73.3	0.88	87.5	64.8
Turbulence [%]	Cut-off: 25.9 %	69.3	1.1	87.5	59.2

urement value was found to be 5.7 cm/s, which is below our calculated cut-off value of 12.3 cm/s. However, the carcinoma displays a high degree of turbulence, specifically 76.2 % at the point of maximum velocity, significantly surpassing our calculated cut-off value of 25.9 %.

▶ **Fig. 5** shows the V-flow examination of a histopathologically proven benign regressive thyroid nodule. The nodule reaches a high mean velocity value of 24.1 cm/s which surpasses our calculated cut-off value of 12.3 cm/s. The benign lesion displayed a low degree of turbulence, measuring 13.1 % at the point of maximum velocity, which is below our calculated cut-off value of 25.9 %.

Cut-off values, sensitivity, specificity, diagnostic accuracy, and diagnostic odds ratio

In order to find a more precise demarcation between benign and malignant thyroid nodules in V-flow, cut-off values for mean velocity as well as for turbulence were calculated. Since there was no statistically significant difference in maximum velocity, a cut-off value for this category was not calculated. It is important to note that as the percentage of turbulence increases and the mean velocity decreases, the likelihood of the lesion being classified as malignant also increases.

The diagnostic accuracy, DOR, sensitivity, and specificity for each mentioned V-flow finding and measurement are listed in ▶ **Table 4**. Turbulence within the lesion achieved the highest diagnostic accuracy and DOR. The highest sensitivity value of 87.5 % was achieved by the mean velocity and turbulence cut-off values, as well as the presence of turbulence within the lesion. On the other hand, the presence of turbulence within the lesion exhibited the highest specificity value of 82.8 %.

Representative cases in V-flow and multimodal sonographic imaging

We selected three cases to illustrate representative findings in V-flow imaging: one case depicting a malignant lesion (▶ **Fig. 6**), another demonstrating a benign lesion (▶ **Fig. 7**), and a third presenting an ambiguous lesion (▶ **Fig. 8**). For the final lesion status decision, we considered malignancy criteria of different ultra-

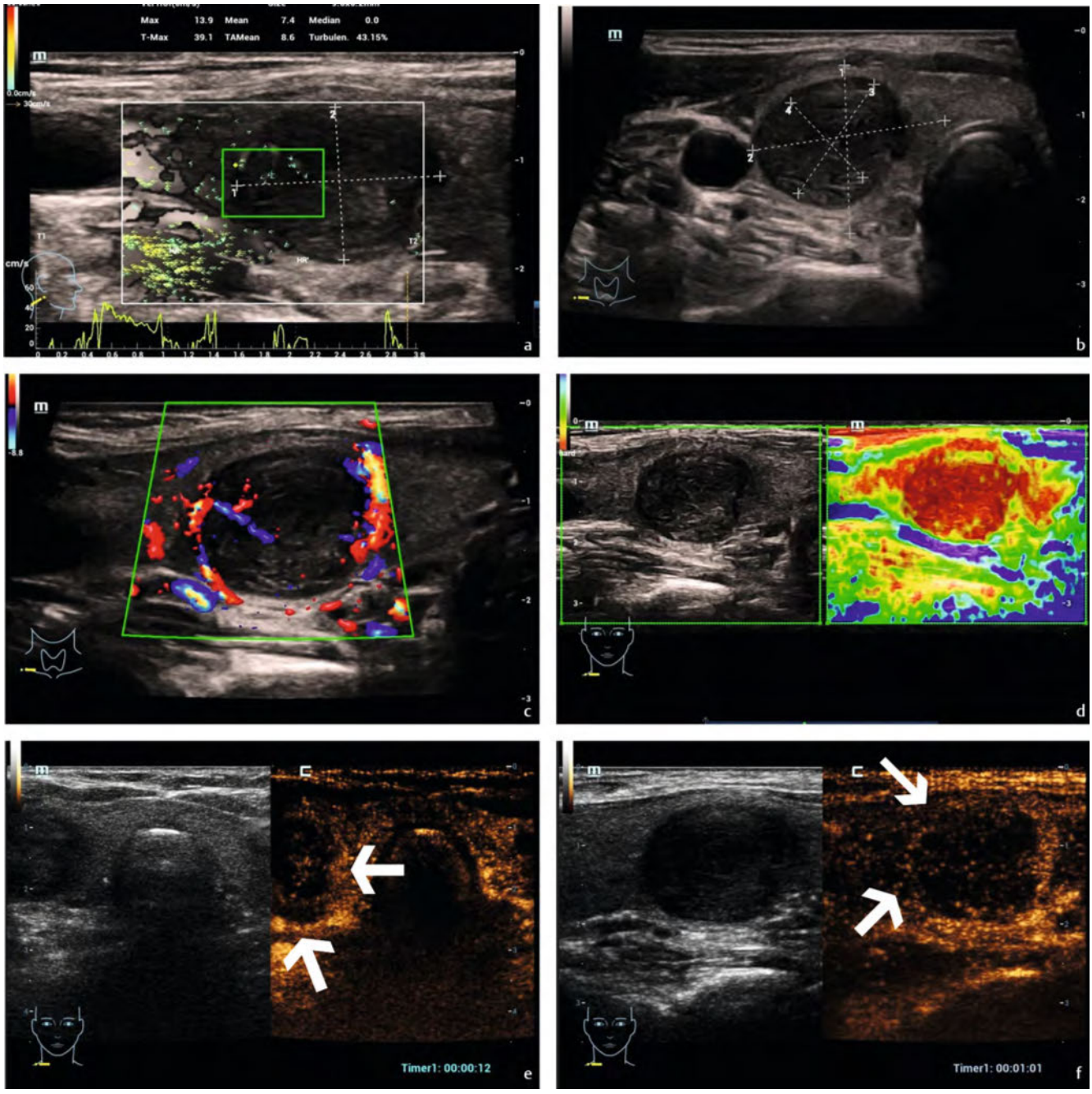

▶ **Fig. 6** Multimodal sonographic examination of a right thyroid lobe with a suspicious TI-RADS V thyroid tumor (papillary thyroid carcinoma): Turbulence and a lack of red arrows in V-flow **a**. Microcalcifications and low echogenicity on B-mode **b**. Inhomogeneous marginal hypervascularization on color-coded Doppler sonography **c**. Central and marginal hard areas on strain elastography **d**. Early marginal wash-in (white arrows) 12 seconds after injection of 20 ml of SonoVue as contrast agent **e** as well as wash-out (white arrows) on contrast-enhanced ultrasound 1 minute and one second after starting the examination **f.**

sound modes: B-mode, CCDS, or high-resolution flow, strain or shear-wave elastography, and CEUS.

Every ultrasound mode in ▶ **Fig. 6** reveals different malignant findings associated with the suspicious lesion, which was rated as TI-RADS V: Turbulence and a lack of red arrows in V-flow; microcalcifications and low echogenicity on B-mode; inhomogeneous marginal hypervascularization on CCDS; central and marginal hard areas on strain elastography; early marginal wash-in as well as a wash-out phenomenon one minute after the injection of the contrast agent on CEUS.

Collectively, these findings strongly indicate the presence of a malignant thyroid tumor. Histopathology confirmed this tumor to be a papillary thyroid carcinoma.

The different ultrasound modes in ▶ **Fig. 7** show several benign findings associated with the suspicious lesion, which was rated as TI-RADS III: Homogenous linear flow with red arrows but without

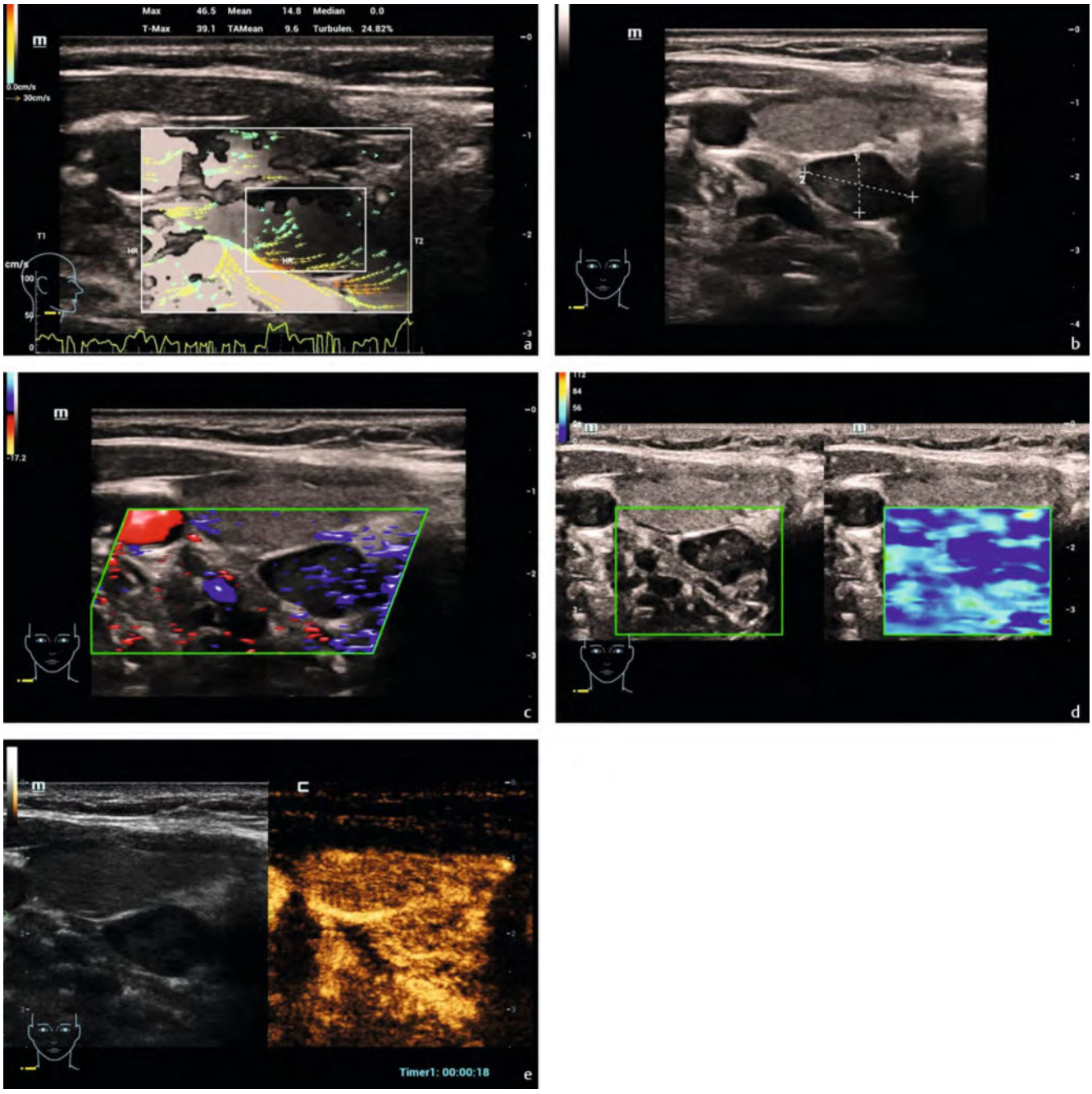

▶ **Fig. 7** Multimodal sonographic examination of a right thyroid lobe with a benign TI-RADS III thyroid tumor: Homogeneous linear flow without turbulence but with red arrows in V-flow **a**. Clear edge demarcation and no microcalcifications on B-mode **b**. Moderate vascularization across the entire lesion in on color-coded Doppler sonography **c**. Rather soft structure on shear-wave elastography **d**. Delayed homogeneous wash-in across the whole lesion **e** 18 seconds after contrast agent injection as well as no wash-out on contrast-enhanced ultrasound.

turbulence in V-flow; clear edge demarcation and no microcalcifications on B-mode; moderate vascularization across the entire lesion on CCDS; a rather soft structure on shear-wave elastography; delayed homogeneous wash-in across the whole lesion as well as no wash-out on CEUS. Taking all of these findings into account, they collectively suggest that the thyroid nodule is benign in nature. Histopathology confirmed this tumor as a benign regressive thyroid nodule.

▶ **Fig. 8** depicts an ambiguous TI-RADS IVa thyroid tumor. Notably, the V-flow and CDDS examination results differ from several other ultrasound modes: V-flow shows a rather linear blood stream with a turbulence measurement of 23.34 %, which is below our calculated cut-off value of 25.0 %. CCDS visualizes vascularization across the whole lesion. These findings would indicate a benign lesion. However, the other ultrasound modes reveal several malignant findings: diffuse edge demarcation and an inhomogeneous sonomorphological structure on B-mode; diffuse hard

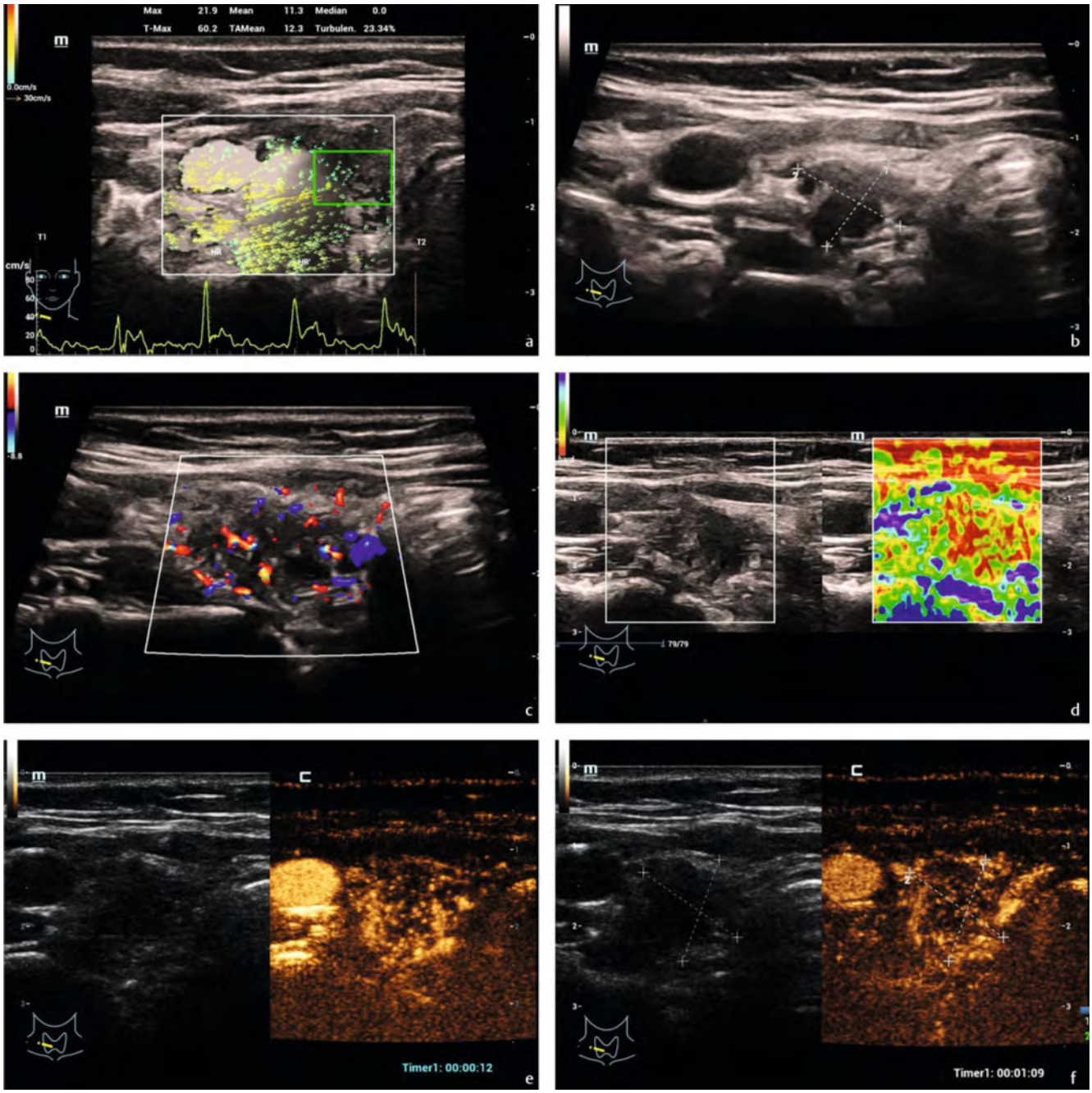

▶ **Fig. 8** Multimodal sonographic examination of a right thyroid lobe with an ambiguous TI-RADS IVa thyroid tumor: Linear blood stream with a turbulence measurement of 23.34 % in V-flow **a**. Diffuse edge demarcation and an inhomogeneous sonomorphological structure on B-mode **b**. Moderate vascularization across the whole lesion on color-coded Doppler sonography **c**. Diffuse hard areas across the whole nodule on strain elastography **d**. Early marginal wash-in 12 seconds after contrast agent injection **e** as well as marginal wash-out 1 minute and 9 seconds after the start of the examination **f** on contrast-enhanced ultrasound. Histopathology identified a papillary thyroid carcinoma.

areas across the whole nodule on strain elastography; early marginal wash-in as well as a marginal wash-out phenomenon one minute and ten seconds after the injection of the contrast agent on CEUS. V-flow and CCDS suggest a benign tumor, whereas B-mode, elastography, and CEUS indicate a malignant thyroid nodule. Histopathology confirmed this tumor as papillary thyroid carcinoma. This case underscores the importance of considering multiple ultrasound modes in the evaluation of suspicious thyroid lesions. In this specific case, CEUS and elastography proved to be more effective in identifying malignancy, despite other modes suggesting a benign lesion. Adopting a comprehensive approach that incorporates various ultrasound modes can significantly improve the accuracy of thyroid nodule assessment and play a pivotal role in guiding appropriate clinical management and treatment decisions.

▶ **Table 5** Sensitivity, specificity, PPV, and NGV of V-flow scoring system for the prediction of malignancy.

V-flow scoring system	Sensitivity	Specificity	PPV	NPV
If ≥4 points are required for predicting malignancy	100.0%	84.9%	0.362	1.0
If 5 points are required for predicting malignancy	87.5%	94.6%	0.582	0.989

V-flow scoring system

We developed a comprehensive scoring system based on the evaluation of our results, which consists of five V-flow malignancy criteria. These criteria include the presence of turbulence within or next to the lesion; a lack of red arrows in the box set across the thyroid lesion; mean velocity below 12.3 cm/s as well as turbulence measurements of the lesion at the point of maximum velocity above 25.9%. Each criterion, when met, contributes one point to the score. Thyroid nodules are assigned a V-flow score based on the number of criteria met. If a thyroid nodule achieves a V-flow score of 4 or 5, it is predicted to be malignant.

The score-based V-flow scheme demonstrates a sensitivity of 100.0%, a specificity of 84.9%, a positive predictive value (PPV) of 0.36, and a negative predictive value (NPV) of 1.0 as presented in ▶ **Table 5**. These values change to 87.5%, 94.6%, 0.58, and 0.99 respectively, if 5 points are required to indicate a high risk of malignancy.

Conclusions

Up to this point the novel ultrasound technique V-flow has only been used for large brain-supplying arteries and veins [10, 12]. However, this study represents the first reported findings on the utilization of V-flow for solid thyroid tumors. Our results demonstrate that V-flow shows promise in distinguishing between benign and malignant thyroid nodules, particularly when used in conjunction with CEUS to assess microvascularization. Malignant lesions exhibit a turbulent and slow flow profile in V-flow, which matches the documented chaotic and turbulent perfusion seen in carcinomas [7, 17, 18]. Moreover, integrating V-flow with established ultrasound modes such as B-mode, elastography, CCDS, and CEUS could enhance their diagnostic capabilities. Consequently, the number of unnecessary thyroid surgeries for benign lesions could potentially be reduced by up to 70%. Furthermore, V-flow could serve as a valuable addition to the TI-RADS classification, which currently relies solely on B-mode. However, it is important to note that further multicenter studies are needed to further validate its efficacy and establish standardized qualitative and quantitative techniques for V-flow examination.

Discussion

The findings of our study demonstrate that malignant thyroid tumors often exhibit turbulent blood flow with reduced blood stream velocity in V-flow. Carcinomas exhibit inhomogeneous microvascularization and chaotic blood vessels especially along their margins as well as shunts where blood cannot flow linearly. Consequently, blood flow becomes turbulent and fails to reach the higher velocity values typically observed in linear directed blood vessels found in benign thyroid nodules [7, 18]. Detecting these perfusion patterns requires the application of dynamic imaging techniques.

If the decision for a (hemi-)thyroidectomy had depended on our newly developed scoring system, the number of patients with benign nodules undergoing surgery would have decreased from 71 out of 93 patients to only 5. This represents a remarkable reduction of 70%. After all, V-flow did not allow for a definitive differentiation between benign and malignant thyroid lesions in all cases. Further sonographic examinations were required to enhance the informative value of V-flow in these cases.

In 5 cases, benign lesions received a V-flow score of 4 or higher, leading to an incorrect classification as malignant. To address this, multimodal sonographic imaging consisting of B-mode, CCDS, elastography, and CEUS was applied to those 5 nodules, which were initially classified as malignant based on the V-flow score. The 5 nodules showed several benignity criteria in multimodal sonographic imaging: 4 of them exhibited well-defined edges and lacked microcalcifications in B-mode, 3 were depicted as rather soft on elastography, 3 displayed homogeneous vascularization throughout the entire nodule and none of them exhibited a fast wash-in or a wash-out phenomenon on CEUS [7]. On the other hand, some of the carcinomas also showed signs of benignity on multimodal sonographic imaging: 2 did not have microcalcifications, 1 had clear edge demarcation, 1 was soft, and 2 did not show any sign of wash-out on CEUS. Consequently, we can draw the following conclusion: Neither V-flow nor any other single sonographic technique should be the sole determining factor in deciding whether a thyroid lesion is benign or malignant. However, V-flow enhances the evaluation of microvascular hemodynamics in thyroid tumors, making it a valuable addition to established ultrasound modes for clarifying thyroid pathologies prior to surgical histopathological examination. To comprehensively assess sonomorphology, density, macro- and microvascularization of a thyroid node, we recommend following our own published study protocol: starting sonography with B-mode considering TI-RADS, followed by strain- and shear-wave elastography as well as CCDS. Subsequently, a dynamic evaluation using a 4-minute CEUS examination should be performed [4, 5, 6]. Based on our own results and the TI-RADS classification, multimodal sonographic imaging is essential for detecting and characterizing thyroid tumors [3, 6]. Particularly, CEUS facilitates further analyzation of TI-RADS IVa and IVb nodules. Strain and shear-wave elastography enable a more detailed differentiation of benign and malignant TI-RADS III and IV lesions, which show mixed echogenicity on B-mode. V-flow

offers new possibilities for visualizing irregular turbulent neovascularization in carcinomas or homogeneous marginal vascularization in benign lesions. Therefore, it contributes to a more precise examination of vascularized nodules, which are classified as TI-RADS III and up. The volume of thyroid lesions could be a relevant factor for malignancy, with carcinomas having a slightly higher average value, which is consistent with small benign lesions showing no signs of neovascularization.

We compared the malignancy and benignity prediction of the V-flow scoring system to TI-RADS, elastography, and CEUS. Our V-flow scoring system reaches a sensitivity of 100.0 % and a specificity of 84.9 %. In our group of patients, elastography shows a sensitivity of 75.2 % and a specificity of 81.2 % and CEUS a sensitivity of 67.4 % and a specificity of 95.0 %. According to multi-center studies, EU-TIRADS achieves values of 75.0 % and 94.1 % [19], elastography 74.2 % and 91.1 % [20], and CEUS 87.0 % and 83.0 % [21]. However, our data was acquired on a preliminary examined group of 101 patients, whereas the values of EU-TIRADS are derived from multicenter studies with more than 1000 patients. Therefore, a direct comparison should not be made yet, as V-flow has to be proven in larger samples in the future.

This study has several potential limitations that should be taken into consideration. Firstly, it employs a retrospective approach which may have inherent biases and limitations in data collection. Additionally, the examination process itself was time-consuming, which could impact the feasibility of implementing it in a clinical setting. Moreover, it is important to note that V-flow is currently only available on high-end devices (such as Mindray Resona 7 and Resona R9) equipped with special probe technology. Furthermore, there is a lack of officially standardized protocols for V-flow procedures [9]. There is also no comparable literature addressing V-flow performed on thyroid nodules. Another constraint is that the V-flow examination box or window can only be adjusted horizontally and vertically but not diagonally. In addition, the examinations conducted in this study were performed by just two experienced sonographers on a preliminary examined group of patients. The number of 101 patients is adequate for a first trial. However, the 8 included carcinomas do not cover the entire range of thyroid carcinomas as follicular, anaplastic, poorly differentiated carcinomas, and metastases are missing. Moreover, one in two medullary carcinomas was only detected because of high calcitonin levels and turned out to be a 3 mm microcarcinoma. In future iterations of V-flow technology, the mode should also be improved to allow tracking of even very low velocity streams, as the current minimal detectable velocity of V-flow is 23 cm/s.

While some studies performed histological diagnostic workup with FNA or ultrasound-guided biopsy [22, 23], our study employed intra- or postoperative histopathological examinations, which are considered equally accurate. It is important to emphasize that while V-flow and multimodal sonographic imaging demonstrate high combined sensitivity and specificity, only postoperative histopathology can consistently and accurately differentiate between benign and malignant thyroid nodules [14, 15].

Clinical relevance

- V-flow visualizes microvascular perfusion, which indicates the status of a tumor
- Malignant tumors are associated with slower and more turbulent microvascular hemodynamics
- By including V-flow in the clinical ultrasound routine, the number of unnecessary thyroid surgeries in cases of benign nodules can be reduced significantly
- Always consider multiple ultrasound modes in the evaluation of suspicious thyroid lesions and never rely on the findings of one sonographic technique
- Adopting a comprehensive approach that incorporates various ultrasound modes can significantly improve the accuracy of thyroid nodule assessment and play a pivotal role in guiding appropriate clinical management and treatment decisions

Conflict of Interest

The authors declare that they have no conflict of interest.

References

[1] Pizzato M, Li M, Vignat J et al. The epidemiological landscape of thyroid cancer worldwide: GLOBOCAN estimates for incidence and mortality rates in 2020. Lancet Diabetes Endocrinol 2022. doi:10.1016/S2213-8587(22)00035-3

[2] Padovano M, Scopetti M, Tomassi R et al. Mapping complications in thyroid surgery: statistical data are useful for medico-legal management of a recurrent safety issue. Updates Surg 2022. doi:10.1007/s13304-022-01357-8

[3] Russ G, Bonnema SJ, Erdogan M et al. European Thyroid Association Guidelines for Ultrasound Malignancy Risk Stratification of Thyroid Nodules in Adults: The EU-TIRADS. Eur Thyroid 2017. doi:10.1159/000478927

[4] Rago T, Vitti P. Risk Stratification of Thyroid Nodules: From Ultrasound Features to TIRADS. Cancers (Basel) 2022. doi:10.3390/cancers14030717

[5] Brito JP, Gionfriddo M, Al Nofal A et al. The accuracy of thyroid nodule ultrasound to predict thyroid cancer: systematic review and meta-analysis. J Clin Endocrinol Metab 2014. doi:10.1210/jc.2013-2928

[6] Jung EM, Thurn S, Brandenstein M et al. High resolution flow (HR Flow) and Glazing Flow in cases of hepatic flow changes: Comparison to color-coded Doppler sonography (CCDS). Clin Hemorheol Microcirc 2021. doi:10.3233/CH-219102

[7] Brandenstein M, Wiesinger I, Künzel J et al. Multiparametric Sonographic Imaging of Thyroid Lesions: Chances of B-Mode, Elastography and CEUS in Relation to Preoperative Histopathology. Cancers (Basel) 2022. doi:10.3390/cancers14194745

[8] Ma X, Zhang B, Ling W et al. Contrast-enhanced sonography for the identification of benign and malignant thyroid nodules: Systematic review and meta-analysis. J Clin Ultrasound 2016. doi:10.1002/jcu.22311

[9] Yigang D, Yingying S. V Flow: a novel visualization of blood flow-210285X6P-20170728, Mindray online portal. 2022. Accessed July 10, 2023 at: https://www.mindraynorthamerica.com/wp-content/uploads/2020/04/WP_V-Flow.pdf

[10] David E, Martinelli O, Pacini P et al. New Technologies in the Assessment of Carotid Stenosis: Beyond the Color-Doppler Ultrasound-High Frame Rate Vector-Flow and 3 D Arterial Analysis Ultrasound. Diagnostics (Basel) 2023. doi:10.3390/diagnostics13081478

[11] You BY, Lai SS, Yu AC. Vector projectile imaging: time-resolved dynamic visualization of complex flow patterns. Ultrasound Med Biol 2014. doi:10.1016/j.ultrasmedbio.2014.03.014

[12] Kammerer S, Stroszczynski C, Jung EM. Functional ultrasound imaging of the venous valve of the great saphenous vein in the area around the crosse using the novel vector flow technique. Clin Hemorheol Microcirc 2020. doi:10.3233/CH-209205

[13] Seifert P, Schenke S, Zimny M et al. Diagnostic Performance of Kwak, EU, ACR, and Korean TIRADS as well as ATA Guidelines for the Ultrasound Risk Stratification of Non-Autonomously Functioning Thyroid Nodules in a Region with Long History of Iodine Deficiency: A German Multicenter Trial. Cancers 2021. doi:10.3390/cancers13174467

[14] Liu Y, Li X, Yan C et al. Comparison of diagnostic accuracy and utility of artificial intelligence-optimized ACR TI-RADS and original ACR TI-RADS: a multi-center validation study based on 2061 thyroid nodules. Eur Radiol 2022. doi:10.1007/s00330-022-08827-y

[15] Seminati D, Capitoli G, Leni D et al. Use of Diagnostic Criteria from ACR and EU-TIRADS Systems to Improve the Performance of Cytology in Thyroid Nodule Triage. Cancers 2021. doi:10.3390/cancers13215439

[16] Yan S, Shou J, Yu J et al. Ultrafast Ultrasound Vector Doppler for Small Vasculature Imaging. IEEE Trans Ultrason Ferroelectr Freq Control 2023. doi:10.1109/TUFFC.2023.3279452

[17] Ulisse S, Baldini E, Lauro A et al. Papillary Thyroid Cancer Prognosis: An Evolving Field. Cancers (Basel) 2021. doi:10.3390/cancers13215567

[18] Bojunga J. Ultrasound of Thyroid Nodules. Ultraschall Med 2018. doi:10.1055/a-0659-2350

[19] Skowrońska A, Milczarek-Banach J, Wiechno W et al. Accuracy of the European Thyroid Imaging Reporting and Data System (EU-TIRADS) in the valuation of thyroid nodule malignancy in reference to the post-surgery histological results. Pol J Radiol 2018. doi:10.5114/pjr.2018.81556

[20] Russ G, Royer B, Bigorgne C et al. Prospective evaluation of thyroid imaging reporting and data system on 4550 nodules with and without elastography. Eur J Endocrinol 2013. doi:10.1530/EJE-12-0936

[21] Zhang J, Zhang X, Meng Y et al. Contrast-enhanced ultrasound for the differential diagnosis of thyroid nodules: An updated meta-analysis with comprehensive heterogeneity analysis. PLoS One 2020. doi:10.1371/journal.pone.0231775

[22] Solbiati L, Osti V, Cova L et al. Ultrasound of thyroid, parathyroid glands and neck lymph nodes. Eur Radiol 2001. doi:10.1007/s00330-001-1163-7

[23] Sidhu PS, Cantisani V, Dietrich CF et al. The EFSUMB Guidelines and Recommendations for the Clinical Practice of Contrast-Enhanced Ultrasound (CEUS) in Non-Hepatic Applications: Update 2017. Ultraschall Med 2018. doi:10.1055/a-0586-1107