

Colonic endoscopic submucosal dissection using a flexible Maryland dissector

Endoscopic resection of T1N0 gastrointestinal malignancies has shown excellent long-term recurrence-free and overall survival rates when tumor-free resection margins are achieved [1,2]. For en bloc resection of lesions larger than 20 mm, piecemeal resection or endoscopic submucosal dissection (ESD) is required [3]. Although many different devices are available, ESD remains technically difficult, time consuming, and associated with perforation rates of up to 10% [1,2,4,5]. The laparoscopic Maryland dissector is a standard surgical instrument used for fine dissection. A flexible version of this instrument that can be passed through a 3.7-mm endoscopic working channel has recently become available (▶ **Video 1**).

We used the endoscopic Maryland dissector (Ethicon Endo-Surgery, Cincinnati, Ohio, USA) to perform colonic ESD in a female domestic pig. Under general anesthesia resection margins were created by marking a circumferential area with superficial mucosal burns. Saline and methylene blue were then injected into the submucosa. A circular mucosal incision was performed using a hook knife (Ethicon Endo-Surgery) and blunt dissection through the submucosal plane was facilitated with the endoscopic Maryland dissector (▶ **Fig. 1**, ▶ **Video 2**).

Time for circumferential precutting was 17 minutes. Time for blunt submucosal dissection was 36 minutes. Complete resection in one piece including all electrocautery markings was achieved. The size of the resection specimen was 2.5 × 2.0 cm. The size of the electrocautery markings was 1.7 × 1.9 cm. No procedure-related complications such as bleeding or perforation occurred.

Video 1

Demonstration of the endoscopic Maryland dissector.

Video 2

Colonic endoscopic submucosal dissection using the endoscopic Maryland dissector.

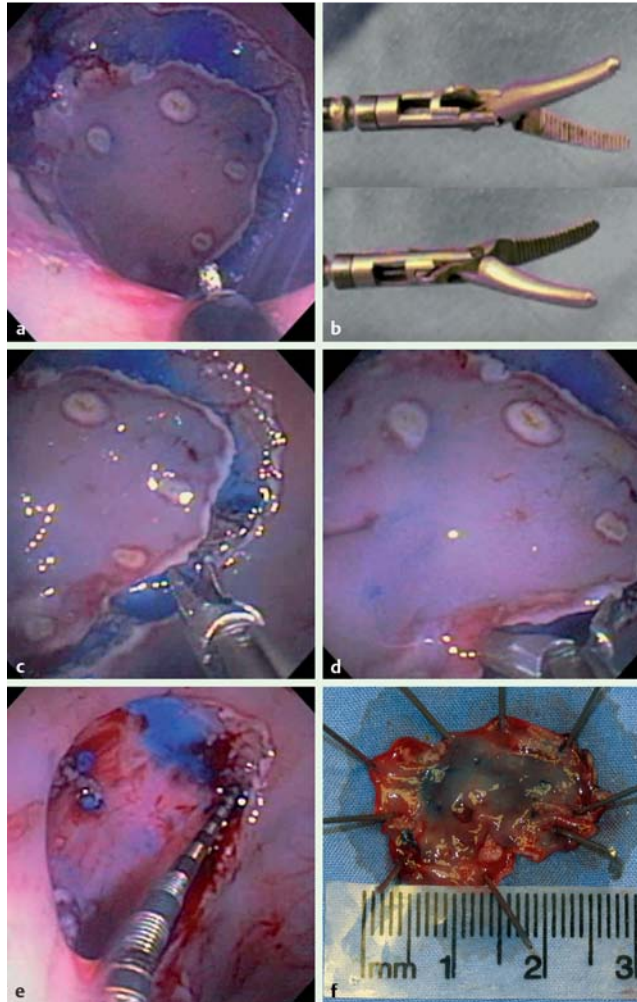


Fig. 1 a After marking a circumferential area with superficial mucosal burns a circular submucosal incision was performed using a hook knife. b–d The novel flexible endoscopic Maryland dissector (b) was used for blunt submucosal dissection (c, d). e Endoscopic view of the resection site with a 3-cm endoscopic ruler in the lesion. f Resected specimen.

The concept and design of the endoscopic Maryland dissector are similar to those of the laparoscopic dissector. Using this novel device, the surgical technique of blunt dissection was successfully translated into an endoscopic model. Blunt submucosal dissection is straightforward, and may be widely applicable for removal of gastrointestinal lesions. Moreover, all used instruments are approved by the Food and Drug Administration. A modified, smaller endoscopic Maryland dissector with the possibility to apply electrocautery might improve the usability of this device for colonic ESD.

Endoscopy_UCTN_Code_TTT_1AQ_2AD

**D. von Renteln¹, H. Pohl¹,
M. C. Vassiliou^{1,2}, R. I. Rothstein¹**

¹ Department of Gastroenterology and Hepatology, Dartmouth-Hitchcock Medical Center, Lebanon, New Hampshire, USA

² Department of Surgery, Dartmouth-Hitchcock Medical Center, Lebanon, New Hampshire, USA

References

- 1 *Kantsevov SV, Adler DG, Conway JD et al.* Endoscopic mucosal resection and endoscopic submucosal dissection. *Gastrointest Endosc* 2008; 68: 11 – 18
- 2 *Das A.* Endoscopic submucosal dissection – cure in one piece. *Endoscopy* 2006; 38: 1044 – 1046
- 3 *Vieth M, Rosch T.* Endoscopic mucosal resection and the risk of lymph-node metastases: indications revisited? *Endoscopy* 2006; 38: 175 – 179
- 4 *Neuhaus H, Wirths K, Schenk M et al.* Randomized controlled study of EMR versus endoscopic submucosal dissection with a water-jet hybrid-knife of esophageal lesions in a porcine model. *Gastrointest Endosc* 2009; 70: 112 – 120
- 5 *Neuhaus H, Costamagna G, Deviere J et al.* Endoscopic submucosal dissection (ESD) of early neoplastic gastric lesions using a new double-channel endoscope (the “R-scope”). *Endoscopy* 2006; 38: 1016 – 1023

Bibliography

DOI 10.1055/s-0029-1215159

Endoscopy 2009; 41: E262 – E263

© Georg Thieme Verlag KG Stuttgart · New York ·
ISSN 0013-726X

Corresponding author

R. I. Rothstein, MD

Department of Gastroenterology and Hepatology
Dartmouth-Hitchcock Medical Center
1 Medical Center Drive
Lebanon
NH 03756
USA
Fax: +1-603-650-5225
richard.rothstein@dartmouth.edu