

Cladosporium macrocarpum brain abscess after endoscopic ultrasound-guided celiac plexus block

A 45-year-old man presented with a 24-hour history of holocranial headache and right-side deviation of the oral commissure. He denied fever and other neurological symptoms. He had undergone endoscopic ultrasound (EUS)-guided celiac plexus neurolysis (CPN) 3 weeks before for the management of refractory epigastric pain caused by alcoholic chronic pancreatitis.

On physical examination, cachexia (due to exocrine pancreatic insufficiency) was evident (body mass index of 16 kg/m²). Temperature was 36.7 °C. Neurologic examination revealed only a right central facial palsy. Blood count and chemistry were normal except for: platelets, 53 000/μL; lymphocytes, 820/μL (492 CD4+/μL); triglyceride level, 68 mg/dL; albumin level, 68 mg/dL; and gamma-glutamyl transferase level, 339 U/dL.

Neuroimaging suggested the diagnosis of a brain abscess (● Fig. 1 and 2).

Lumbar puncture was normal. Chest and abdominal computed tomography scan only revealed calcifications at the pancreatic area with homogeneous splenomegaly and portal thrombosis. A transthoracic echocardiography with contrast injection did not identify an intracardiac right-to-left shunt. HIV and *Toxoplasma gondii* serologies were negative. Blood cultures were sterile and tuberculin test was negative.

Treatment with meropenem (6 g/day) and ampicillin (2 g/4 hours) was started. The patient underwent a stereotactic brain biopsy with evacuation of a purulent abscess. The Gram stain of the abscess showed Gram-positive bacilli. Direct vision with potassium hydroxide showed pigmented fungal structures suggestive of dematiaceae fungi infection. Treatment with voriconazole was initiated (400 mg/day i.v.). The darkly pigmented mold isolated was identified as *Cladosporium macrocarpum*, and the bacteria as *Streptococcus constellatus*. The patient completed 30 days more of treatment with cefotaxime (2 g/6 hours i.v.) and metronidazole (1.5 g/day i.v.). He was discharged from hospital on oral amoxicillin-clavulanic acid (4 g/day) and oral voriconazole (400 mg/day). Cranial scans showed a progressive reduction of the lesions.

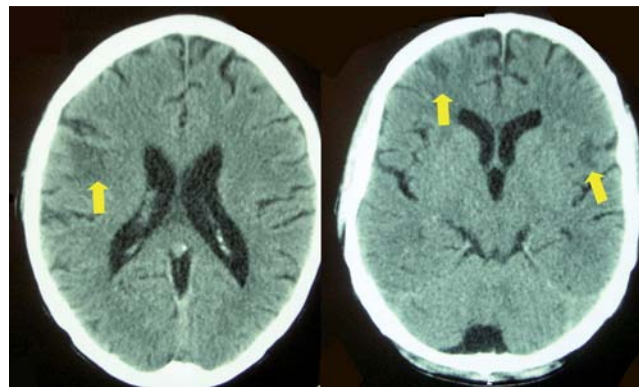


Fig. 1 A computed tomography scan of the brain demonstrated three cortical-subcortical lesions (arrows), two of them involving the right frontal lobe and another one measuring 1.4 cm in the left Sylvian fissure, surrounded by edema.

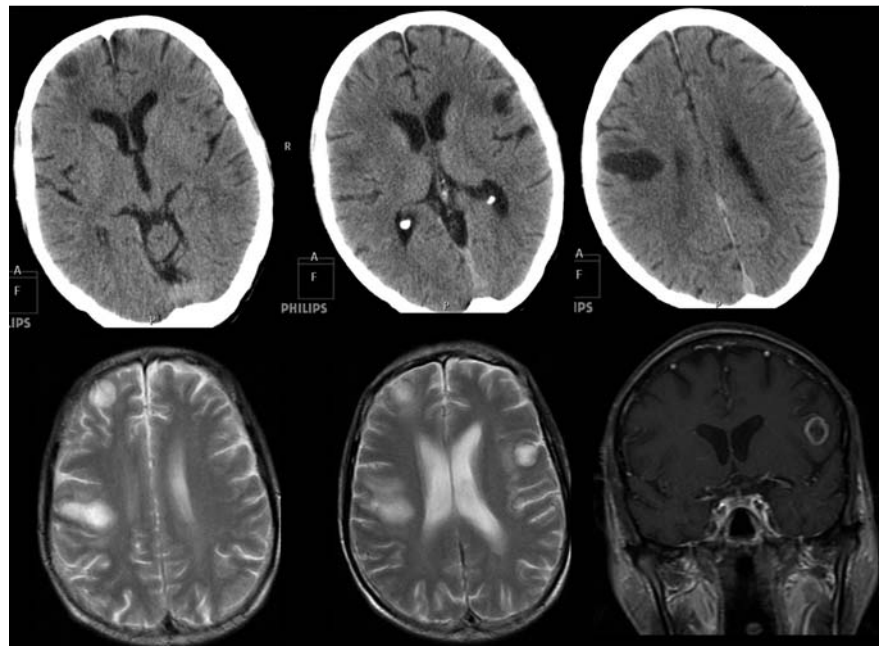


Fig. 2 On gadolinium-enhanced T1-weighted imaging, the lesions showed intense ring enhancing. On diffusion-weighted imaging the lesion had hyperintensity, and apparent diffusion coefficient maps showed hypointensity, consistent with restricted diffusion. These changes strongly suggested the diagnosis of a brain abscess.

Brain abscesses are exceptional after endoscopic procedures [1,2]. This is, to the best of our knowledge, the first case report of a brain abscess after EUS-guided CPN. In our case, the microorganisms could have reached the brain through blood vessels by directly spreading from the upper gastrointestinal tract following CPN. The hematogenous spread, and the resulting brain abscess development was aided by the cellular immunodeficiency (characterized by lymphocytopenia). Dematiaceous fungi comprise a heterogeneous group of fungi that contain melanin in their cell walls. The most severe forms of

phaeohyphomycosis are infections of the central nervous system [3,4]. Brain abscess is a rare and frequently fatal manifestation of phaeohyphomycosis, often in immunocompetent individuals. The most common species responsible is *Cladophialophora bantiana* [3]. The treatment requires both complete excision of the brain abscess and antifungal therapy (itraconazole, voriconazole or amphotericin B) [5]. Therapy should not be stopped until complete radiographic resolution occurs [5]. The mortality is about 100% without treatment, and 65% for those who are treated with surgery and chemotherapy [3,4].

Endoscopy_UCTN_Code_CPL_1AL_2AG

Competing interests: None

**A. Lalueza¹, F. López-Medrano¹,
A. del Palacio², A. Alhambra²,
E. Álvarez³, A. Ramos³, A. Pérez⁴,
M. Lizasoain¹, Y. Meije¹, A. García-
Reyne¹, J. M. Aguado¹**

¹ Infectious Diseases Unit, University Hospital 12 de Octubre, Madrid, Spain

² Department of Microbiology, University Hospital 12 de Octubre, Madrid, Spain

³ Department of Radiodiagnosis, Division of Neuroradiology, University Hospital 12 de Octubre, Madrid, Spain

⁴ Department of Neurosurgery, University Hospital 12 de Octubre, Madrid, Spain

References

- 1 Robert JY, Raoul JL, Bretagne JF et al. Unusual presentation of a case of brain abscess after endoscopic injection sclerotherapy of esophageal varices. *Endoscopy* 1991; 23: 237–238
- 2 Thapar VK, Rajashekaram S, Bapat RD, Kantharia CV. Brain abscess following esophageal dilatation. *Dis Esophagus* 2003; 16: 145–147
- 3 Revankar SG. Dematiaceous fungi. *Mycoses* 2007; 50: 91–101
- 4 Li DM, de Hoog GS. Cerebral phaeohyphomycosis – a cure at what lengths? *Lancet Infect Dis* 2009; 9: 376–383
- 5 Meletiadis J, Meis JF, Mouton JW et al. In vitro activities of new and conventional antifungal agents against clinical *Scedosporium* isolates. *Antimicrob Agents Chemother* 2002; 46: 62–68

Bibliography

DOI 10.1055/s-0030-1255804

Endoscopy 2011; 43: E9–E10

© Georg Thieme Verlag KG Stuttgart · New York · ISSN 0013-726X

Corresponding author

A. Lalueza, MD

Infectious Diseases Unit
University Hospital 12 de Octubre
Av. Córdoba, km 5,400
Madrid 28041
Spain
Fax: +34-91-3908000
lalueza@hotmail.com