

Spontaneous disappearance of a giant colonic lipoma after endoscopic biopsy

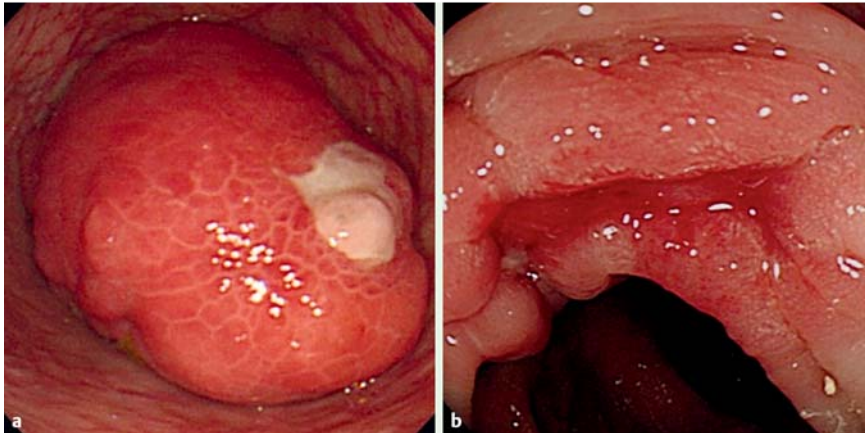


Fig. 1 Endoscopic findings at time of diagnosis and at preoperative evaluation. **a** Colonoscopy revealed a large submucosal tumor with ulceration, but no bleeding (December 2008). **b** Colonoscopy showed that the tumor had disappeared and ulceration remained without any tumor remnant (January 2009).

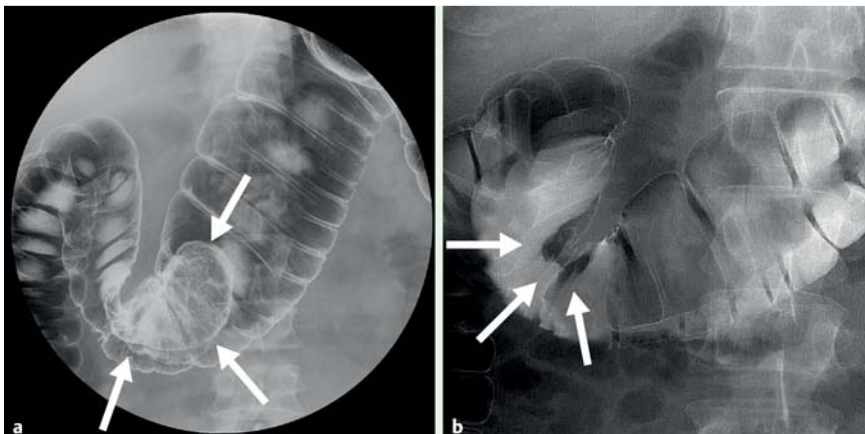


Fig. 2 Barium enema findings at time of diagnosis and at preoperative evaluation. **a** Barium enema showed a large, broad-base mass in the transverse colon (arrows; December 2008). **b** Barium enema showed no mass in the transverse colon (arrows; January 2009).

A giant colonic lipoma was found in a 38-year-old man who presented with hematochezia and intermittent abdominal pain. Colonoscopy revealed a submucosal tumor with ulceration in the transverse colon (● Fig. 1 a).

Abdominal computed tomography (CT) showed a low-density mass consistent with fat. Barium enema revealed a 75 × 45-mm broad-base mass in the transverse colon (● Fig. 2 a).

Following these examinations a diagnosis of giant lipoma causing gastrointestinal bleeding was made. Endoscopic resection was attempted; however it was decided not to proceed because the mass was too

large to allow the definitive visualization of the base of the mass. Biopsy was conducted after the mucosa overlying the tumor had been removed (5-mm diameter) using an electric snare. Histologically, only inflamed colonic mucosa was found.

CT and barium enema were repeated for preoperative evaluation 1 month later; the tumor had disappeared completely (● Fig. 2 b). Colonoscopy revealed ulceration without any tumor (● Fig. 1 b).

Spontaneous disappearance of a gastrointestinal lipoma is an extremely rare phenomenon. Kurahara et al. reported a case of spontaneous disappearance of a gastric lipoma after endoscopic biopsy [1]. The

authors speculated that the lipoma might have disappeared due to damaged mucosa caused by the biopsy: if mucosa overlying the lipoma is damaged, there is some possibility of exposure and enucleation of the tumor. Some cases of spontaneous elimination of gastrointestinal lipomas have been reported [2–4]. Stebbings et al. [4] explained that torsion and necrosis of the pedicle had caused spontaneous expulsion of the lipoma.

We speculate that the lipoma in the present case might have undergone enucleation through the damaged region of the surface mucosa following biopsy or as a result of ulceration. Alternatively, it is possible that spontaneous expulsion of the lipoma occurred as a result of ischemic change and necrosis at the base of the tumor.

Endoscopy_UCTN_Code_CCL_1AD_2AJ

Competing interests: None

S. Ishiyama, Y. Tashiro, K. Nagayasu, K. Niwa, S. Ono, K. Sugimoto, M. Hata, H. Kamiyama, H. Komiyama, M. Takahashi, Y. Yaginuma, Y. Kojima, M. Goto, M. Tanaka, H. Sengoku, A. Okuzawa, Y. Tomiki, K. Sakamoto

Department of Coloproctological Surgery, Juntendo University, Tokyo, Japan

References

- 1 Kurahara K, Aoyagi K, Hizawa K et al. Spontaneous disappearance of a gastric lipoma after endoscopic biopsy: report of an unusual case. *Endoscopy* 1999; 31: S31
- 2 Robertson DAF, Saweirs W, Low-Beer TS. Spontaneous expulsion of a large colonic tumor. *Br Med J* 1982; 285: 1084
- 3 Zamboni WA, Fleisher H, Zander JD, Folse JR. Spontaneous expulsion of lipoma per rectum occurring with colonic intussusception. *Surgery* 1987; 101: 104–107
- 4 Stebbings WS, Staunton MD. Spontaneous expulsion of a large submucosal colonic lipoma. *J R Soc Med* 1989; 82: 624–625

Bibliography

DOI 10.1055/s-0030-1255821

Endoscopy 2011; 43: E16

© Georg Thieme Verlag KG Stuttgart · New York · ISSN 0013-726X

Corresponding author

S. Ishiyama, MD

Department of Coloproctological Surgery

Juntendo University

2-1-1 Hongo

Bunkyo-ku

Tokyo 113-8421

Japan

Fax: +81-3-38130731

i-shun@juntendo.ac.jp