

## Endoscopic removal of a biliary covered metallic stent with the invagination method

Endoscopic removal of covered self-expandable metallic stents (SEMS) has been increasingly reported [1–3]. Migration is one of the complications with covered SEMS, and a recently developed covered WallFlex stent (Boston Scientific, Natick, MA, USA) has flared ends to prevent migration. We experienced difficulty in removal of a partially covered WallFlex stent because of embedment of this flared proximal end. Here we describe a new method for removing an embedded stent. An 85-year-old man presented with obstructive jaundice from pancreatic cancer. A partially covered WallFlex stent (Boston Scientific, Natick, MA, USA) was inserted. A plastic stent was also inserted into the gallbladder for concomitant cholecystitis. Four months later, the patient presented with recurrent jaundice. Endoscopic retrograde cholangiopancreatography revealed stent occlusion by sludge, without evidence of tumor ingrowth.

Stent removal was attempted. The stent could not be removed by grasping the looped distal ends with a forceps or grasping the distal edge with a snare (▶ **Figs. 1 and 2**, ▶ **Video 1**).

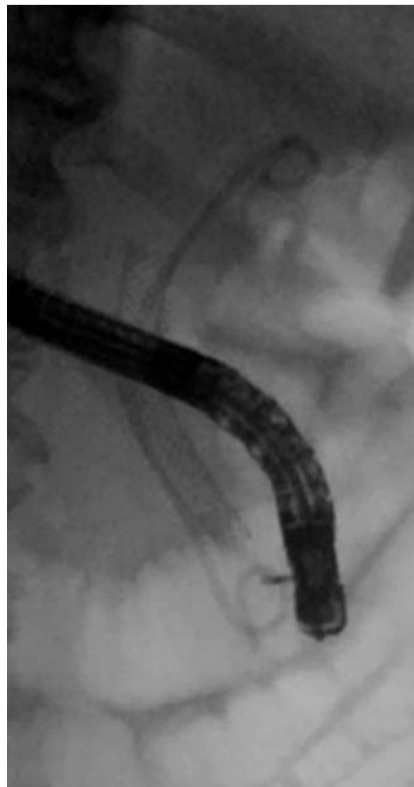
The proximal uncovered portion was firmly embedded in the bile duct. To peel off the embedded stent, a biopsy forceps was cannulated inside the stent and the proximal wire loop was grasped and pulled off the bile duct. The proximal edge was gradually invaginated into the inner lumen. The stent was finally removed with a snare (▶ **Fig. 3**, ▶ **Video 2**).

### Video 1

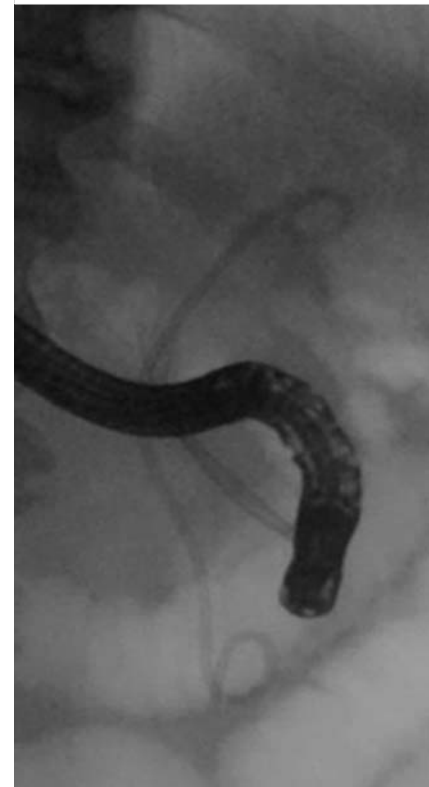
Failed stent removal by grasping the distal edge with a biopsy forceps or snare.

### Video 2

Stent removal with invagination by forceps, followed by removal with a snare.



**Fig. 1** Stent removal with a biopsy forceps failed.

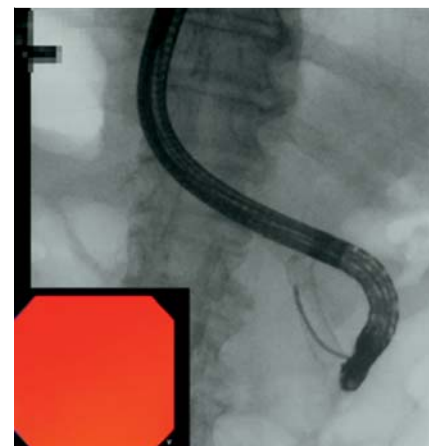


**Fig. 2** The proximal edge of the stent was firmly embedded in the bile duct, and stent removal with a snare failed.

We did not experience difficulty in removal of partially covered Wallstents (Boston Scientific, Natick, MA, USA) using a snare. The covered WallFlex stent is a similar braided design to the covered Wallstent [4,5] but has looped and flared ends to prevent migration and tissue damage. This design might cause tight embedment of the uncovered flared ends and difficulty in stent removal. Our combination method of invagination with a forceps followed by removal with a snare is one of the useful techniques for embedded covered SEMS removal.

Endoscopy\_UCTN\_Code\_TTT\_1AR\_2AZ

**Competing interests:** None



**Fig. 3** A biopsy forceps was cannulated into the stent, and the proximal stent edge was grasped and peeled off the bile duct.

Y. Nakai, H. Isayama, K. Kawakubo,  
H. Kogure, T. Sasaki, O. Togawa,  
N. Sasahira, K. Hirano, T. Tsujino,  
M. Tada, M. Omata, K. Koike  
Department of Gastroenterology,  
Graduate School of Medicine,  
University of Tokyo

## References

- 1 *Familiari P, Bulajic M, Mutignani M et al.* Endoscopic removal of malfunctioning biliary self-expandable metallic stents. *Gastrointest Endosc* 2005; 62: 903–910
- 2 *Shin HP, Kim MH, Jung SW et al.* Endoscopic removal of biliary self-expandable metallic stents: a prospective study. *Endoscopy* 2006; 8: 1250–1255
- 3 *Kahaleh M, Tokar J, Le T, Yeaton P.* Removal of self-expandable metallic Wallstents. *Gastrointest Endosc* 2004; 60: 640–644
- 4 *Kahaleh M, Tokar J, Conaway MR et al.* Efficacy and complications of covered Wallstents in malignant distal biliary obstruction. *Gastrointest Endosc* 2005; 61: 528–533
- 5 *Nakai Y, Isayama H, Komatsu Y et al.* Efficacy and safety of the covered Wallstent in patients with distal malignant biliary obstruction. *Gastrointest Endosc* 2005; 62: 742–748

## Bibliography

DOI 10.1055/s-0030-1256023  
Endoscopy 2011; 43: E30–E31  
© Georg Thieme Verlag KG Stuttgart · New York ·  
ISSN 0013-726X

## Corresponding author

**Yousuke Nakai, MD, PhD**  
Department of Gastroenterology  
University of Tokyo  
7-3-1 Hongo Bunkyo-ku  
Tokyo 113-8655  
Japan  
Fax: +81-3-3814-0021  
ynakai-ky@umin.ac.jp