

Atypical clinical presentation of typical endoscopic finding of Bouveret's syndrome

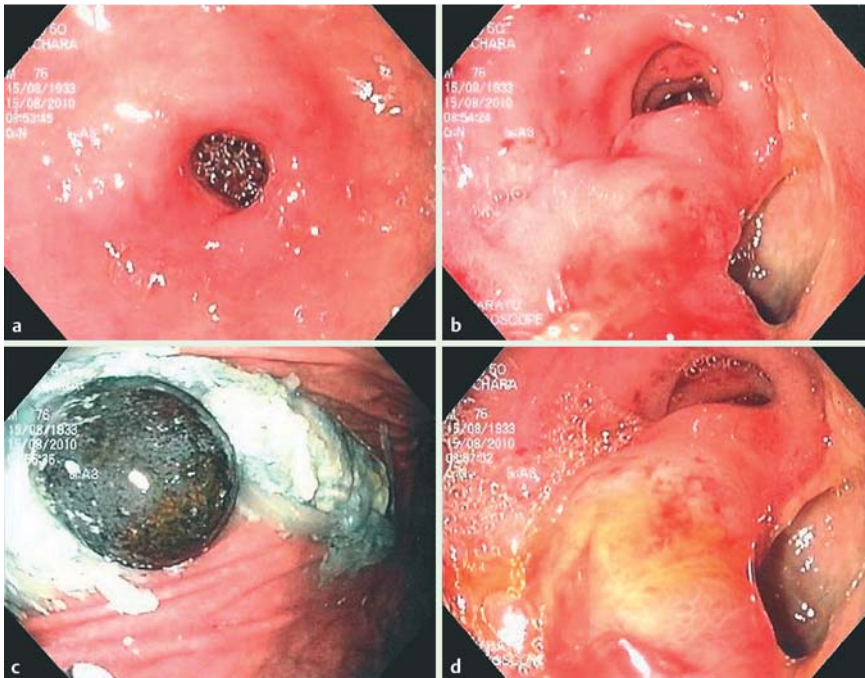


Fig. 1 Endoscopic view of gallstone **a** impacted in the duodenal bulb and **c** after it was removed. **b, d** Choledochoduodenal fistula.

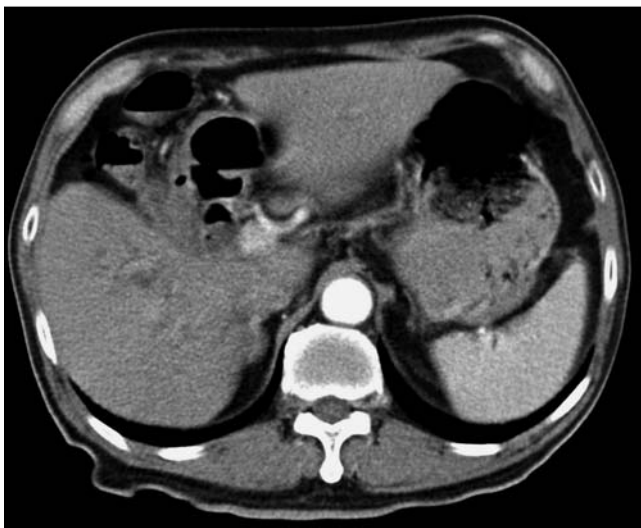


Fig. 2 Computed tomography (CT) scan showing the hypodensity tract which connected gallbladder and duodenum.

Bouveret's syndrome is a rare but recognizable condition which was first reported by Leon Bouveret in 1896 [1]. This syndrome is a clinical syndrome of gastric outlet obstruction due to gallstone impaction. Cappell et al. characterized the symptoms of Bouveret's syndrome: patients, usually older than 70 years, presented with abdominal pain (71%), nausea, and vomiting (87%), hematemesis (15%), anorexia (13%), and weight loss (14%)

[2]. Endoscopic investigation would show a cholecystoduodenal (or, rarely, choledochoduodenal) fistula, which was the complication of gallstone impaction together with adhesion at the gallbladder bed or impairment of vascular supply to the gallbladder wall.

We report a case of a 68-year-old man with atypical presentation of abdominal discomfort, nausea, and subacute watery diarrhea with pyrexia for a few weeks.

The stool was watery without any white blood cells or red blood cells. The patient underwent endoscopy to exclude internal malignancy. The esophagogastroduodenoscopy showed a large gallstone 2.5 cm in diameter (● **Fig. 1**) impacted in the duodenal bulb.

After the stone was removed endoscopically, there was a cholecystoduodenal fistula at the posterior wall of the duodenal bulb. The computed tomography (CT) scan (● **Fig. 2**) showed a hypodensity tract which connected the gallbladder and duodenum.

The patient's diarrhea subsided after the endoscopy was performed. The patient underwent endoscopic retrograde cholangiopancreatography 1 week later, which demonstrated multiple common bile duct (CBD) stones with leakage of contrast media from the mid CBD to the first part of the duodenum. Finally, the patient underwent CBD stone removal with a Dormia basket and balloon retrieval catheter, and we planned for surgical correction.

Despite the fact that more than 300 cases of Bouveret's syndrome have been reported [3], subacute diarrhea has never been reported as one of the clinical presentations of Bouveret's syndrome. We think that the diarrhea in this case might be related to intestinal inflammation or colonic irritation from bile salts.

Endoscopy_UCTN_Code_CCL_1AB_2AZ_3AZ

Competing interests: None

V. Prachayakul^{1,2}, P. Aswakul², U. Kachintorn^{1,2}

¹ Division of Gastroenterology, Department of Internal Medicine, Siriraj Hospital, Mahidol University, Bangkok, Thailand

² Vikit Viranuwatti Endoscopy Center, Siriraj Hospital, Mahidol University, Bangkok, Thailand

References

- 1 Alessabdro F, Pietro N, Antonio M et al. A rare variant of gallstone ileus: Bouveret's syndrome. *J Gastrointest Surg* 2010; 14: 753–755
- 2 Mitchell SC, Michael D. Characterization of Bouveret's syndrome: a comprehensive review of 128 cases. *Am J Gastroenterol* 2006; 101: 2139–2146
- 3 Cornel I, Raluca B, Nadin AH et al. Bouveret syndrome associated with acute gangrenous cholecystitis. *J Gastrointest Liver Dis* 2008; 17: 87–90

Bibliography

DOI 10.1055/s-0030-1256058

Endoscopy 2011; 43: E55 – E56

© Georg Thieme Verlag KG Stuttgart · New York ·
ISSN 0013-726X

Corresponding author

P. Aswakul, MD

Vikit Viranuwatti Endoscopy Center

Siriraj Hospital

Mahidol University

Bangkok 10711

Thailand

Fax: +66-2-4299672

asawakul@gmail.com