

Retention of endoscopic capsule in an umbilical hernia

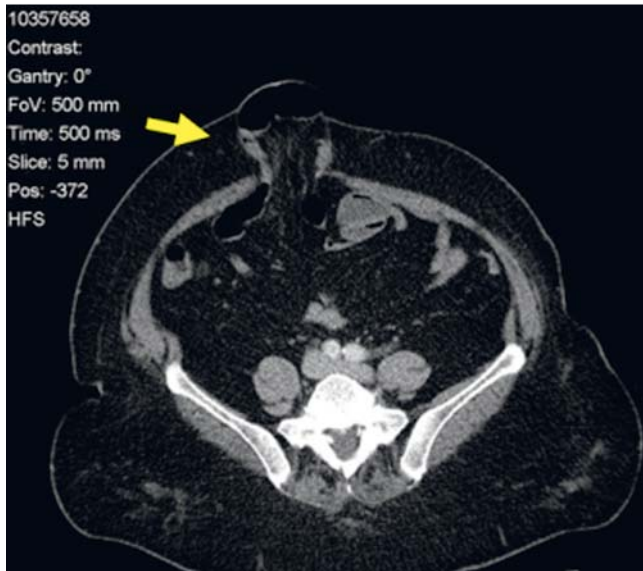


Fig. 1 Computed tomography (CT) enteroclysis showing the umbilical hernia (yellow arrow) with a bowel loop within.

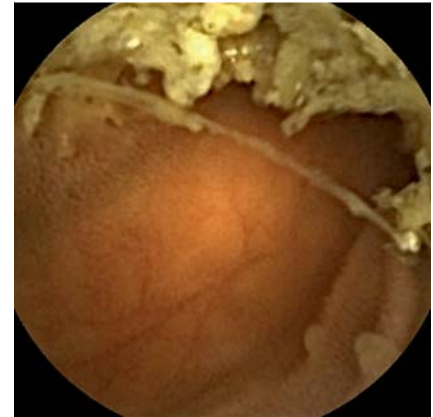

Fig. 2 Image captured by capsule endoscopy at the site of stagnation.

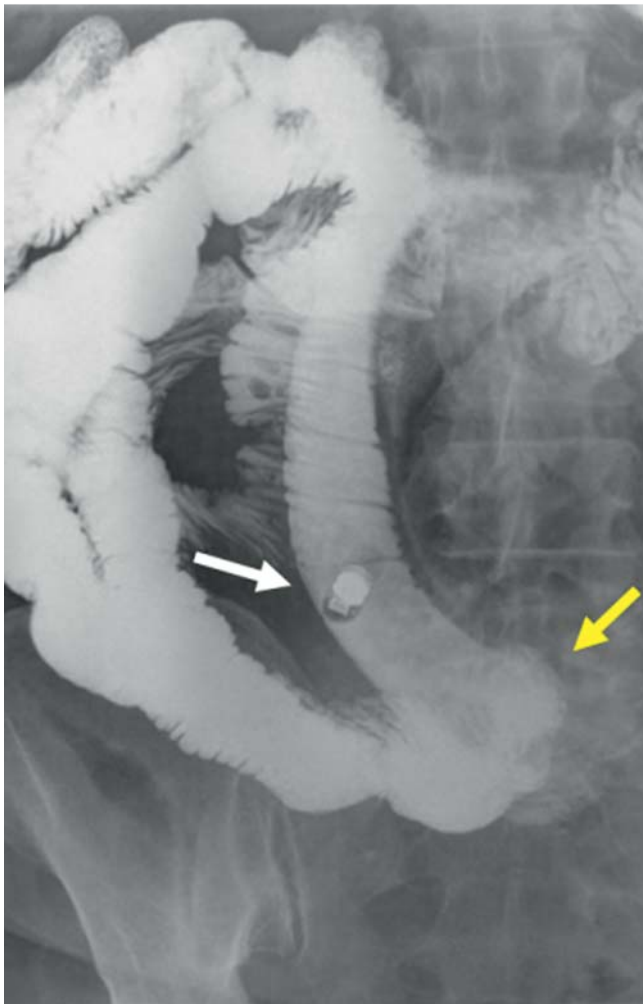


Fig. 3 Small-bowel radiograph with water-soluble contrast showing retained capsule (white arrow) in relation to an umbilical hernia (yellow arrow).

Capsule endoscopy is a common method for the investigation of obscure gastrointestinal bleeding. Despite the reduced risk of complications, capsule retention is the most frequent complication, occurring in 1%–3% of cases [1].

A 64-year-old woman, obese and hypertensive, with indeterminate colitis in remission for several years, presented to the emergency department with hematochezia. She reported a history of recent surgery to varicose veins of the lower limbs and post-operative treatment with diclofenac. On physical examination, she appeared pale; the rest of the examination was unremarkable except for a reducible incoercible umbilical hernia. Analytically, the patient presented hemoglobin of 5.6 g/dL (12–16 g/dL).

Upper endoscopy and colonoscopy showed no lesions, and the patient was admitted for investigation. The computed tomography (CT) enteroclysis was normal except for an umbilical hernia with a bowel loop within, without signs of strangulation (• Fig. 1).

Capsule endoscopy (PillCam SB 2; Given Imaging, Yoqneam, Israel) was then performed; it showed no changes in the mucosa up to the jejunum, where after 1 hour and 20 minutes the capsule remained stagnant until the end of the battery's life (• Fig. 2).

The patient remained asymptomatic. A small-bowel radiograph with water-soluble contrast showed the capsule retained

in the umbilical hernia and ruled out stenosis or signs of small-bowel obstruction (● Fig. 3).

After 16 days of capsule retention, a hernioplasty was performed and the capsule was spontaneously expelled afterwards. Retention of an endoscopic capsule is a rare complication. There are a few case reports of capsule retention in different types of digestive diverticulum [2–4] but, to the best of our knowledge, this is the first case of capsule retention in an umbilical hernia. Current recommendations do not consider these entities as contraindications for capsule endoscopy [5], but the gastroenterologist should keep in mind the potentially increased risk of capsule retention.

Endoscopy_UCTN_Code_CPL_1AI_2AB

Competing interests: None

F. Ferreira, P. Bastos, H. Cardoso, A. C. R. Nunes, G. Macedo

Gastroenterology Department, Hospital S. João and Faculty of Medicine, Porto, Portugal

References

- 1 Liao Z, Gao R, Xu C, Li ZS. Indications and detection, completion, and retention rates of small-bowel capsule endoscopy: a systematic review. *Gastrointest Endosc* 2010; 71: 280–286
- 2 Ordubadi P, Blaha B, Krampla W et al. Capsule endoscopy with retention of the capsule in a duodenal diverticulum. *Endoscopy* 2008; 40: 247–248
- 3 Giday SA, Pickett-Blakely OE, Buscaglia JM, Mullin GE. Capsule retention in a patient with small-bowel diverticulosis. *Gastrointest Endosc* 2009; 69: 384–386
- 4 Tanaka Y, Motomura Y, Akahoshi K et al. Capsule endoscopic detection of bleeding Meckel's diverticulum, with capsule retention in the diverticulum. *Endoscopy* 2010; 42: 199–200

- 5 Ladas SD, Triantafyllou K, Spada C et al. European Society of Gastrointestinal Endoscopy (ESGE): recommendations (2009) on clinical use of video capsule endoscopy to investigate small-bowel, esophageal and colonic diseases. *Endoscopy* 2010; 42: 220–227

Bibliography

DOI 10.1055/s-0030-1256140

Endoscopy 2011; 43: E111–E112

© Georg Thieme Verlag KG Stuttgart · New York · ISSN 0013-726X

Corresponding author

F. Ferreira

Hospital de São João – Serviço de Gastreenterologia
Alameda Professor Hernâni Monteiro

4200-319 Porto

Portugal

Fax: +351-22-5507742

fredericoferreira2@hotmail.com