

Colonoscopy in a patient with a giant Morgagni hernia

Morgagni hernia is an uncommon type of diaphragmatic hernia, which usually appears in adulthood. The diagnosis is mainly made by chest radiograph and multi-detector computed tomography (CT) [1]. As in this case, colonoscopy with fluoroscopic control is very helpful too. Repair can be performed either by using a trans-thoracic or transabdominal approach, and good results with laparoscopic transabdominal repair have been reported [2]. The case is presented of a 63-year-old man with a giant Morgagni hernia, diagnosed by CT, who underwent a preoperative colonoscopy to rule out other associated pathology and for decompression. The colonoscopy helped to assess the very large volume of the hernia. The patient had experienced abdominal pain, cough, expectoration, and dyspnea. No abdominal trauma was mentioned. Plain abdominal radiographs showed dilated colon and bowel loops, with fluid levels, within the chest. There was diffuse abdominal distension on physical examination.

An emergency colonoscopy was done for decompression prior to surgery. The intestinal contents and gas were drained successfully. No luminal constriction sites were seen. The colonoscope progressed directly, diagonally to the right chest, reaching the level of the second rib (▶ Fig. 1 a) and then moved down in a parallel direction (▶ Fig. 1 b).

The patient underwent urgent laparoscopy due to aggravation of dyspnea. Laparoscopy revealed a giant Morgagni hernia which contained much of the colon; the small bowel was very dilated. The omentum was reduced into the abdomen, the hernia sac was excised, and the defect was repaired with a 12 × 12-cm prosthetic mesh patch. The patient was discharged without complication 3 days after the operation.

Some cases of diaphragmatic hernia are diagnosed unexpectedly during diagnostic colonoscopy [3]. Endoscopists should be aware of the possible occurrence of diaphragmatic hernias and their risk as life-threatening complications. To avoid such dangerous complications, access to radiography facilities with fluoroscopy is

recommended in endoscopic units where colonoscopies are performed.

Endoscopy_UCTN_Code_CCL_1AD_2AJ

Competing interests: None

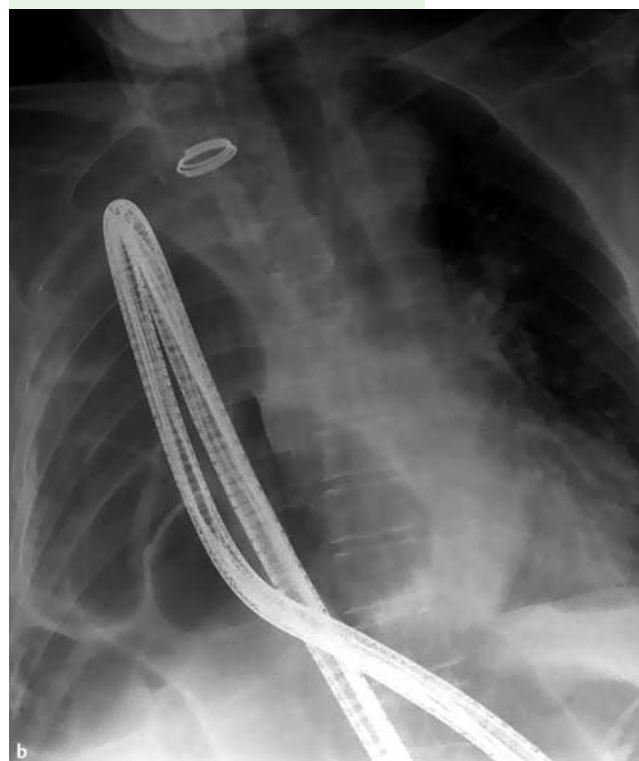
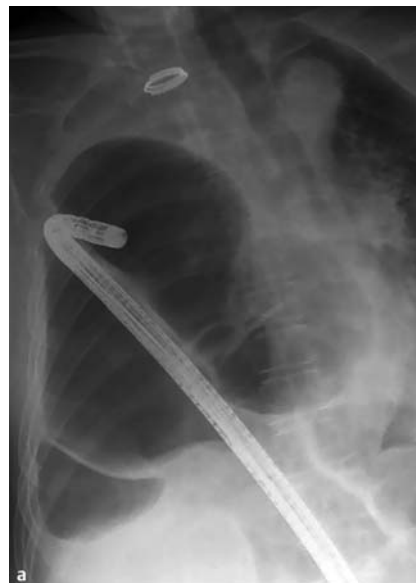

Fig. 1 a The colonoscope progressed diagonally to the right chest, reaching the level of the second rib. b The colonoscope then moved down in a parallel direction, occupying the right thorax.

J. J. Sebastián

Gastroenterology Department, Hospital Royo Villanova, Zaragoza, Spain

References

- 1 Altinkaya N, Parlakgümüş A, Koc Z, Ulsan S. Morgagni hernia: diagnosis with multi-detector computed tomography and treatment. *Hernia* 2010; 14: 277–281
- 2 Yilmaz M, Isik B, Coban S et al. Transabdominal approach in the surgical management of Morgagni hernia. *Surg Today* 2007; 37: 9–13
- 3 Baumann UA, Mettler M. Diagnosis and hazards of unexpected diaphragmatic hernias during colonoscopy: report of two cases. *Endoscopy* 1999; 31: 274–276

Bibliography

DOI 10.1055/s-0030-1256160

Endoscopy 2011; 43: E124

© Georg Thieme Verlag KG Stuttgart · New York · ISSN 0013-726X

Corresponding author

J. J. Sebastián, MD

Servicio de Aparato Digestivo

Hospital Royo Villanova

Avda San Gregorio, 30

50015 Zaragoza

Spain

Fax: +34-976-466917

jjsebastian@salud.aragon.es