

Inflammatory myofibroblastic tumor: an unusual submucosal lesion of the stomach

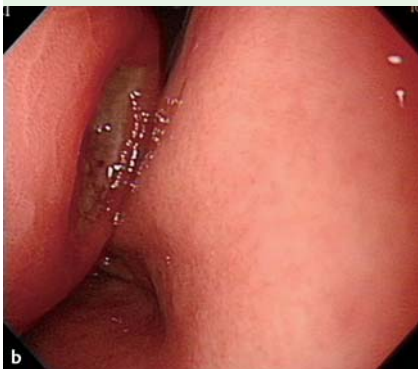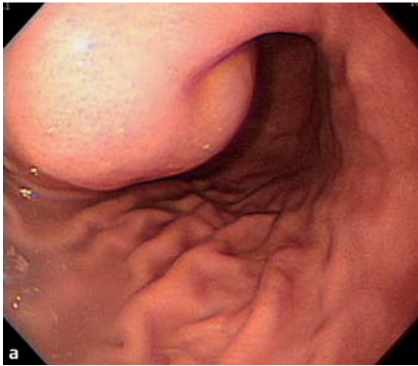


Fig. 1 a, b Upper endoscopy showing a broad-based, protruding mass, approximately 5.5 cm in size, in the anterior wall of lower gastric body. The tumor is accompanied by bridging folds and two deep ulcerations on the surface.

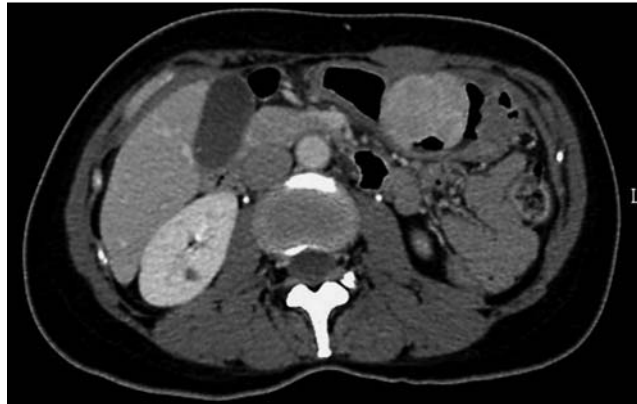

Fig. 2 Abdominal computed tomography (CT) scan demonstrating a strongly enhancing mass, approximately 5.5 cm in size, with surface ulceration, arising from the submucosal layer of the anterior wall of the lower gastric body.

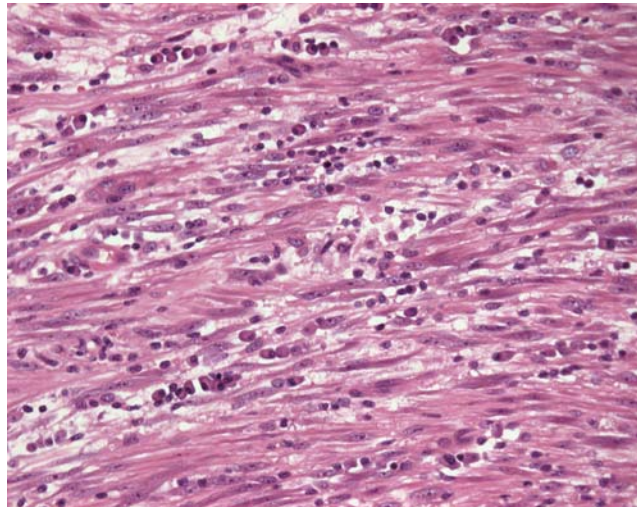


Fig. 3 Microscopic section showing the tumor composed of spindle cells with massive, predominantly inflammatory, infiltration of plasma cells (hematoxylin and eosin, magnification × 40).

Inflammatory myofibroblastic tumor (IMT) is a mesenchymal tumor that occurs preferentially in children and young adults. IMTs were considered arise as a result of a reactive inflammatory or post surgery process [1]. However, they are thought to have low-grade malignant potential, based on the recent molecular finding of rearrangement at chromosome band 2p23, the site of the anaplastic lymphoma kinase (*ALK*) gene in the tyrosine kinase locus [2]. They are most commonly found in the lung but may arise in extrapulmonary sites [3].

A 42-year-old woman presented with intermittent dull epigastric pain since 1 month and tarry stool passage since 1 week. The laboratory findings were unremarkable except for a normocytic anemia (hemoglobin 7.7 g/dL). Upper endoscopy

revealed a broad-based, protruding mass of approximately 5.5 cm, located in the anterior wall of lower gastric body. The tumor was accompanied by bridging folds and two deep ulcerations on its surface (● Fig. 1). Abdominal computed tomography (CT) demonstrated a strongly enhancing mass with surface ulceration, arising from the submucosal layer (● Fig. 2), which was in keeping with a submucosal lesion such as a gastrointestinal stromal tumor (GIST). The patient underwent local tumor excision. Microscopically, the tumor was composed of spindle cells with massive infiltration of plasma cells (● Fig. 3). IMT was diagnosed by immunohistochemistry (IHC), which showed positive staining for desmin and smooth muscle actin and was negative for GIST markers including CD117, DOG1, CD34, and

S100. Kit-negative GIST was further excluded as there no mutations in the c-KIT and PDGFRA genes.

Gastric IMT is very rare and may be confused with other submucosal lesions, especially GIST, and IHC studies are the only conclusive diagnostic modality [4]. When investigating a gastric submucosal lesion, IMT should be taken into consideration particularly if the patient is young or the pathology shows massive plasma cell infiltration admixed with spindle cells.

Endoscopy_UCTN_Code_CCL_1AB_2AD_3AB

Competing interests: None

**Y. K. Lee, H. Y. Wang, L. R. Shyung,
C. W. Chang, M. J. Chen**

Division of Gastroenterology, Department of Internal Medicine, Mackay Memorial Hospital and Mackay Medicine, Nursing and Management College, Taipei, Taiwan

References

- 1 *Leon CJ, Castillo J, Mebold J et al.* Inflammatory myofibroblastic tumor of the stomach: an unusual complication after gastrectomy. *Gastrointest Endosc* 2006; 63: 347–349
- 2 *Sukov WR, Cheville JC, Carlson AW et al.* Utility of ALK-1 protein expression and ALK rearrangements in distinguishing inflammatory myofibroblastic tumor from malignant spindle cell lesions of the urinary bladder. *Mod Pathol* 2007; 20: 592–603
- 3 *Coffin CM, Watterson J, Priest JR et al.* Extrapulmonary inflammatory myofibroblastic tumor (inflammatory pseudotumor). A clinicopathologic and immunohistochemical study of 84 cases. *Am J Surg Pathol* 1995; 19: 859–872
- 4 *Greenson JK.* Gastrointestinal stromal tumors and other mesenchymal lesions of the gut. *Mod Pathol* 2003; 16: 366–375

Bibliography

DOI 10.1055/s-0030-1256257

Endoscopy 2011; 43: E151–E152

© Georg Thieme Verlag KG Stuttgart · New York · ISSN 0013-726X

Corresponding author

Dr. M. J. Chen

Division of Gastroenterology
Department of Internal Medicine
Mackay Memorial Hospital
No.92, Sec. 2 Chung-Shan North Road
Taipei
Taiwan
Fax: +886-2-25433642
mingjen.ch@msa.hinet.net