

Dysphagia resolved with vitamin B₁₂ therapy: a case of esophageal parakeratosis

A 50-year-old woman presented with dysphagia since 1 week. She did not drink alcohol and there was no history of systemic disease, including dermatologic, immunologic, or genetic disease. The initial laboratory findings, complete blood count, and serum biochemistries were normal, except the serum vitamin B₁₂ level, which was 52 pg/mL (normal range: 126–505 pg/mL). Upper endoscopy revealed pangastritis with whitish strips and pseudomembranes on the esophageal mucosa, which peeled off similarly to eosinophilic esophagitis or a lesion of dermatologic origin (● Fig. 1).

The lesions, which presented as discrete patches starting in the upper esophagus, extended diffusely through the entire esophagus. While the gastric biopsy samples showed features of atrophic gastritis, the esophageal biopsy samples were interpreted as parakeratosis (● Fig. 2).

Serum antiparietal antibodies were also positive. The patient was diagnosed as having early-stage pernicious anemia and esophageal parakeratosis. Replacement therapy with vitamin B₁₂ injections was followed by prompt resolution of the dysphagia, and a repeat endoscopy showed complete healing of the esophageal mucosa (● Fig. 3).

The control biopsy samples showed only minimal parakeratosis despite the short-term therapy (● Fig. 4).

Diffuse esophageal parakeratosis is a rare endoscopic diagnosis and is associated with conditions such as tylosis, mucosal hyperkeratosis syndrome, pachyonychia congenita, ethanol exposure, duodenal reflux, riboflavin deficiency, and zinc deficiency [1–6]. Following this first report of pernicious anemia due to vitamin B₁₂ deficiency leading to esophageal parakeratosis, we recommend adding it to the long list of etiologic factors of this condition. Our patient presented with the sole symptom of dysphagia, that is without the established findings of pernicious anemia, such as low hemoglobin, other cytopenias, neurologic findings, and hemolysis. Like the majority of reported cases of esophageal parakeratosis due to nutritional deficiencies, our patient's symptoms and signs also resolved after replacement of the specific deficiency [7].

Endoscopy_UCTN_Code_CCL_1AB_2AC_3AH

Competing interests: None

B. Kayhan¹, S. Olmez¹, E. Ozaslan¹, E. Uner¹, N. Turhan², T. Koseoglu¹, T. Purnak¹

¹ Department of Gastroenterology, Ankara Numune Education and Research Hospital, Ankara, Turkey

² Department of Pathology, Turkiye Yuksek Ihtisas Training and Research Hospital, Ankara, Turkey

References

- 1 Ashworth MT, Nash JR, Ellis A et al. Abnormalities of differentiation and malnutrition in the oesophageal squamous epithelium of patients with tylosis: morphological features. *Histopathology* 1991; 19: 303–310
- 2 Korsten MA, Wornor TM, Feinman L et al. Balloon cytology in screening of asymptomatic alcoholics for esophageal cancer. *Dig Dis Sci* 1985; 30: 845–851
- 3 Clark GW, Smyrk TC, Mirvish SS et al. Effect of gastroduodenal juice and dietary fat on the development of Barrett's esophagus and esophageal neoplasia: an experimental rat model. *Ann Surg Oncol* 1994; 1: 252–261
- 4 Foy H, Kondi A. The vulnerable esophagus: riboflavin deficiency and squamous cell dysplasia of the skin and the esophagus. *J Natl Cancer Inst* 1984; 72: 941–948
- 5 Barney GH, Orgebin-Crist MC, Macapinalac MP. Genesis of esophageal parakeratosis and histologic changes in the testes of the zinc-deficient rat and their reversal by zinc repletion. *J Nutr* 1968; 95: 526–534
- 6 Tu CH, Tai CM, Chang CY et al. Diffuse esophageal parakeratosis. *Endoscopy* 2007; 39: E119–E120
- 7 Carmack SW, Vemulapalli R, Spechler S, Genta RM. Esophagitis dissecans superficialis. A clinicopathologic study of 12 cases. *Am J Surg Pathol* 2009; 33 (12): 1789–1794

Bibliography

DOI 10.1055/s-0030-1256285

Endoscopy 2011; 43: E231

© Georg Thieme Verlag KG Stuttgart · New York · ISSN 0013-726X

Corresponding author

T. Purnak

Department of Gastroenterology, Ankara Numune Education and Research Hospital

PK 203. 06443

Yenisehir

Ankara

Turkey

Fax: +90-312-4414694

purnakt@yahoo.com

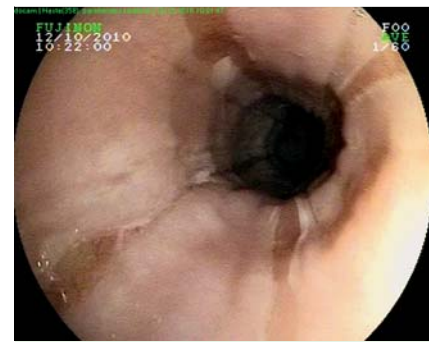


Fig. 1 The whitish strips with extensive sloughing of the esophageal mucosa.

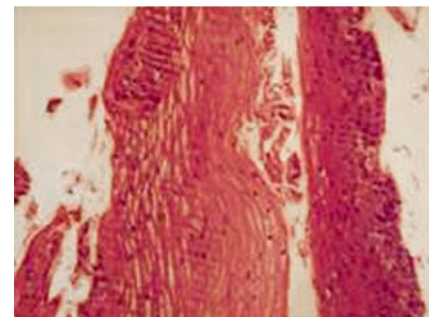


Fig. 2 Histologic section of the esophagus showing a dense layer of parakeratosis (hematoxylin and eosin stain).

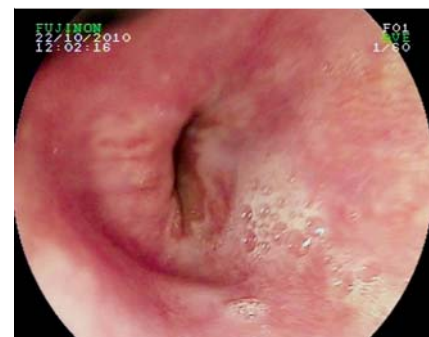

Fig. 3 Normal esophageal mucosa seen at the control endoscopy 5 days later.

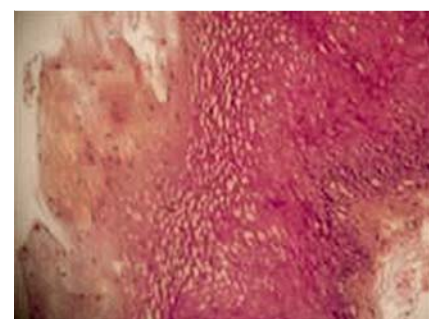

Fig. 4 Reduction in epithelial parakeratosis after therapy (hematoxylin and eosin stain).