

Bronchobiliary fistula as a complication after long-term stenting of hepatic ducts, applied by ERCP after hepatobiliary surgery due to hydatid cyst

A 48-year-old white woman, who worked in agriculture, was admitted with a 4-month history of cough productive of bile-like yellow phlegm. She had been hospitalized several times previously for recurrent right-sided pneumonias. The patient had undergone surgical resection of echinococcal cysts within liver segments V, VI, and VIII, cholecystectomy, and reconstruction of the right hepatic duct damaged by parasitic cyst infiltration 6 years previously (● Fig. 1).

External drains had been inserted into both hepatic ducts through the common bile duct under radiological guidance (● Fig. 2).

At subsequent outpatient visits, leakage of bile from the drains had persisted, and 3 months later, a plastic stent had been inserted into each hepatic duct during endoscopic retrograde cholangiopancreatography (ERCP). The patient had been advised to attend again for monitoring within 3–4 months with the possibility of replacement stents being required. However, she had refused to continue undergoing endoscopic procedures, and the stents remained in place for the next 6 years.

At the time of readmission, abdominal and chest computed tomography (CT) showed inflammatory lesions and a fluid collection in the subdiaphragmatic region; it was impossible to pinpoint the exact location of the fistula at bronchoscopy. A subsequent CT and ERCP demonstrated the fistula between the biliary system and the lower lobe of the right lung (● Figs. 3–5).

After endoscopic removal of the occluded plastic biliary stents, the patient was treated with antibiotics, and an improvement in her general condition and regression of symptoms were observed. A follow-up thoracic CT showed no inflammatory lesion in the lung tissue (● Fig. 6).

The patient was discharged home after 8 days in good general condition. There were no recurrent symptoms at follow-up 24 months later.

A bronchobiliary fistula (BBF), a communication of the biliary system with the bronchial tree, is an exceptionally rare condition with underlying factors that include hydatid disease, hepatobiliary sur-

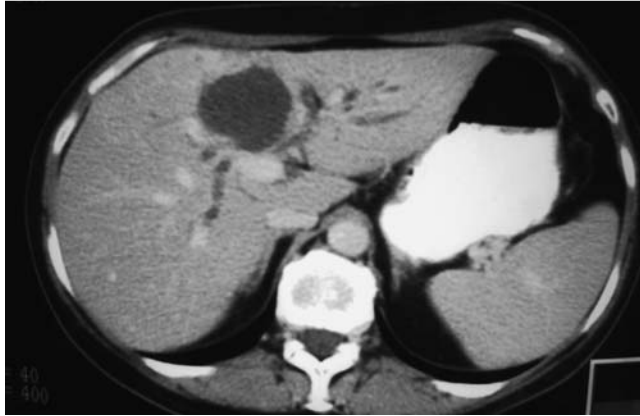


Fig. 1 Abdominal computed tomography (CT) image of an echinococcal cyst in the right lobe of the liver.

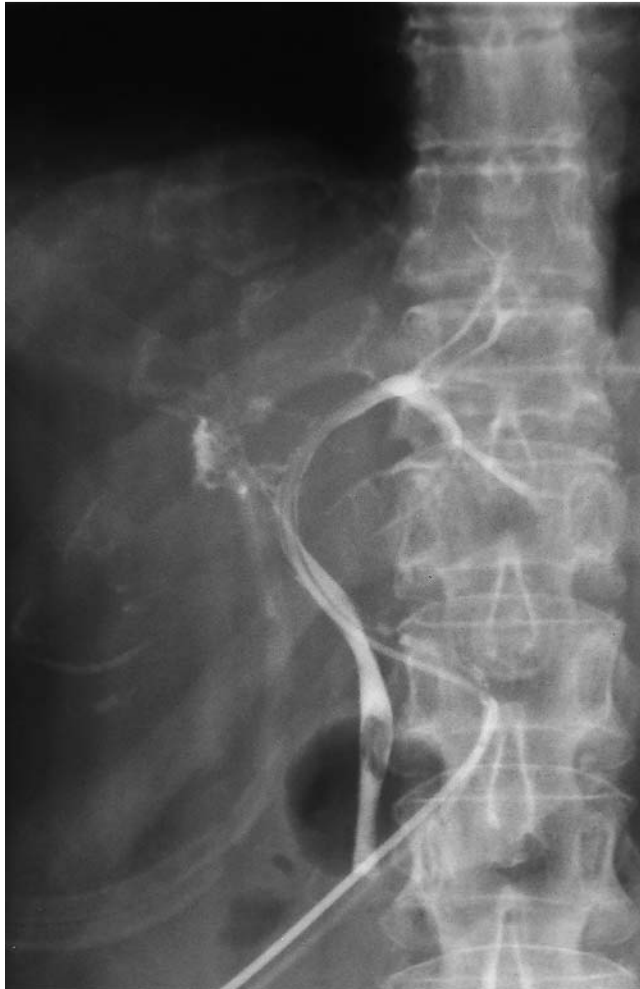

Fig. 2 Postoperative cholangiography showing leakage of bile from the region of the right hepatic duct.

gery, hepatic trauma, and congenital malformation [1–4]. The mechanism of transdiaphragmatic extension in BBF remains controversial. BBF due to the migration of short-term intrahepatic biliary

stents has been previously reported [5]. To our knowledge, BBF caused by long-term extrahepatic biliary stenting has not previously been described, but has clearly been shown by our case, which also

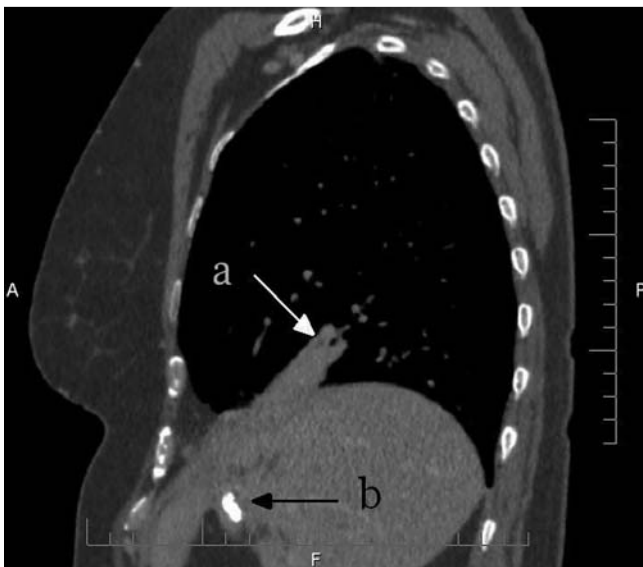


Fig. 3 Abdominal and chest computed tomography (CT) image showing the presence of the fistula between the biliary system and the lower lobe of the right lung (arrow a) and the previously placed plastic biliary stents (arrow b).

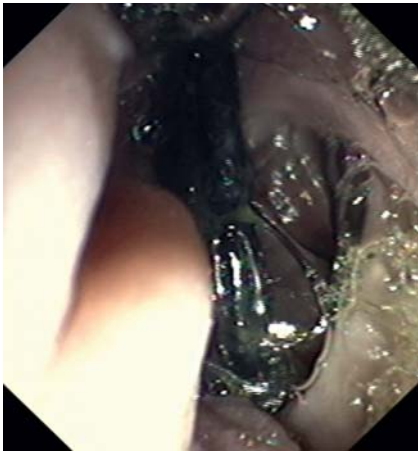


Fig. 4 Both stents are seen protruding from the major duodenal papilla during endoscopic retrograde cholangiopancreatography (ERCP).

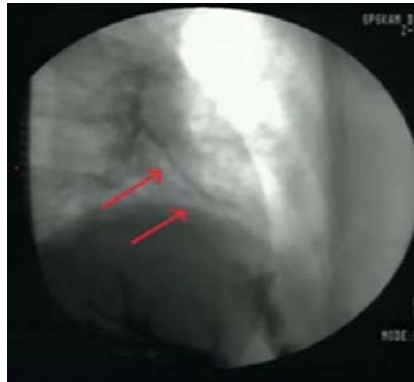


Fig. 5 The presence of the fistula between the biliary system and the lower lobe of the right lung (red arrows) is shown during endoscopic retrograde cholangiopancreatography (ERCP).

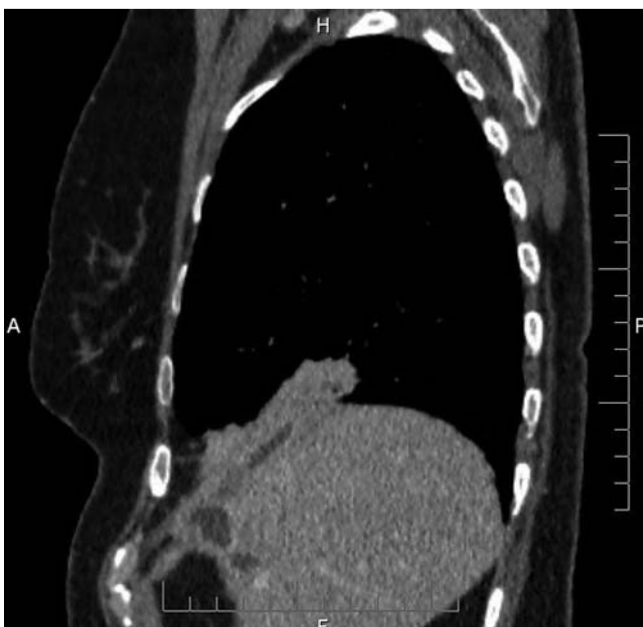

Fig. 6 Thoracic computed tomography (CT) image after antibiotic therapy and endoscopic removal of the plastic biliary stents showing no signs of inflammatory lesions in the lungs.

demonstrates that in particular cases, the condition can be successfully managed with a conservative endoscopic approach.

Endoscopy_UCTN_Code_CPL_1AK_2AI

Competing interests: None

H. Razak Hady¹, A. Baniukiewicz², M. Luba¹, P. Rogalski², A. Dabrowski², J. Dadan¹

¹ First Department of General and Endocrinological Surgery, Medical University of Bialystok, Poland

² Department of Gastroenterology and Internal Medicine, Medical University of Bialystok, Poland

References

- 1 Delande S, Goffette P, Verbaandert C, Rahier J *et al*. Bronchobiliary fistula and cholangiocarcinoma: a case report and principles of management. *Acta Clin Belg* 2007; 62: 438–441
- 2 Rando K, Harguindeguy M, Zunini G. Echinococcal disease with bronchobiliary fistula. *Can J Surg* 2008; 51: 117–118
- 3 Gandhi N, Kent T, Kaban JM *et al*. Bronchobiliary fistula after penetrating thoracoabdominal trauma: case report and literature review. *J Trauma* 2009; 67: 143–145
- 4 Najdi T, Sibai H, Zineddine A *et al*. Congenital bronchobiliary fistula: a case report. *Arch Pediatr* 2009; 16: 1137–1141
- 5 Dasmahapatra HK, Pepper JR. Bronchopleurobiliary fistula: a complication of intrahepatic biliary stent migration. *Chest* 1988; 94: 874–875

Bibliography

DOI 10.1055/s-0030-1256295

Endoscopy 2011; 43: E178–E179

© Georg Thieme Verlag KG Stuttgart · New York · ISSN 0013-726X

Corresponding author

H. Razak Hady, MD

Medical University of Bialystok

ul. M. Skłodowskiej-Curie 24a

15-276 Bialystok

Poland

Fax: +48-85-7468620

klchirog@umwb.edu.pl