

Spraying N-butyl-2-cyanoacrylate (Histoacryl) as a rescue therapy for gastrointestinal malignant tumor bleeding after failed conventional therapy

We report here on five cases of bleeding gastrointestinal malignant tumors treated by spraying N-butyl-2-cyanoacrylate (Histoacryl) on the lesion with satisfactory results (Table 1). The first case was a 84-year-old man who presented with recurrent upper gastrointestinal bleeding since a few days. Esophagogastroduodenoscopy (EGD) revealed a 5-cm gastric cancer at the lesser curvature with oozing. Epinephrine (1:20000) was injected into the tumor to slow down the bleeding, following which Histoacryl (cyanoacrylate 0.5 mL with Lipiodol 0.8 mL per aliquot) was sprayed via a 23-G needle catheter (Interject™, Boston Scientific, Massachusetts, USA) (Fig. 1) over the tumor surface, followed by sterile water until hemostasis was achieved. The patient had no overt bleeding at 9 weeks after the procedure. The second case was a 76-year-old woman with cryptogenic cirrhosis who presented with recurrent lower gastrointestinal bleeding. Colonoscopy revealed a 5-cm sessile polyp in the ascending colon with oozing. Epinephrine was injected and Histoacryl sprayed using the same technique as described above, and the bleeding stopped. The third case was a 15-year-old boy with a metastasizing germinoma with tumor invasion of the second portion of the duodenum. The bleeding was stopped using the same technique again. The patient had recurrent bleeding 48 h later, which was successfully stopped by angio-embolization. The fourth case involved a 56-year-old man with pancreatic

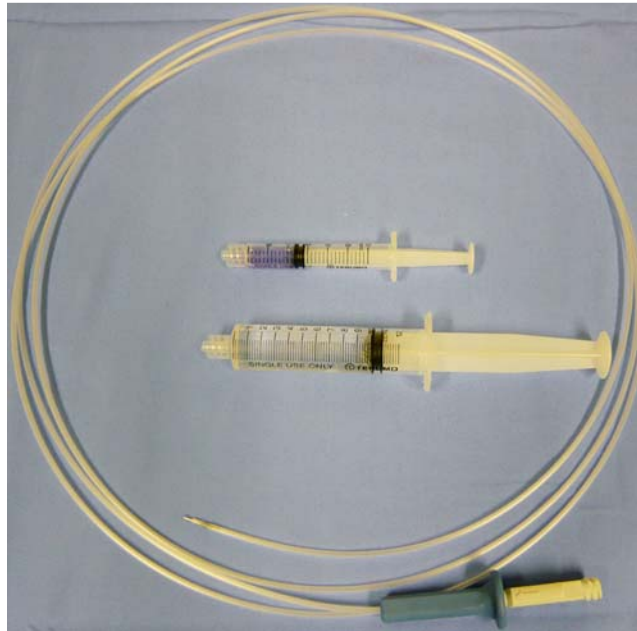


Fig. 1 The instruments used for spraying Histoacryl.

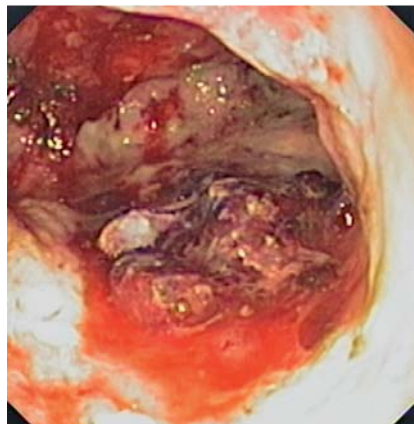


Fig. 2 Active oozing from the gastric tumor surface.

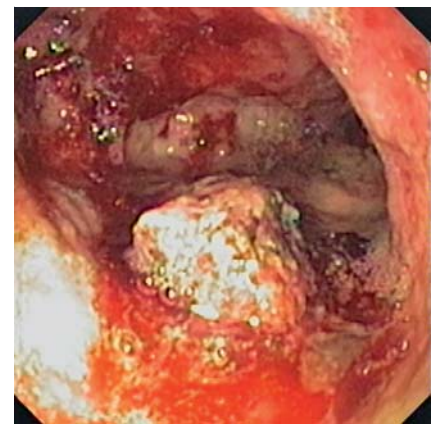


Fig. 3 View after initial Histoacryl spray.

Table 1 Clinical outcomes of the patients.

Patient no	Age and sex	Type of malignancy	Epinephrine injection	Histoacryl spray (mL)	Initial homeostasis	Re-bleeding (72 h)	Intermediate outcome
1	84 M	Gastric cancer	Yes	3.0	Yes	No	Still alive, no re-bleeding at 9 weeks
2	76 F	Malignant colonic polyp	Yes	2.0	Yes	No	Dead, no re-bleeding at 5 weeks
3	15 M	Duodenal cancer	Yes	1.0	Yes	Yes	Continue to bleed and still alive
4	56 M	Pancreatic cancer with gastric wall invasion	No, with metallic clip	1.0	Yes	No	Still alive, No re-bleeding at 6 weeks
5	62 F	Ampullary carcinoma	Yes with argon plasma coagulation (failed embolization at first step)	1.5	Yes	No	Dead, no re-bleeding at 9 weeks

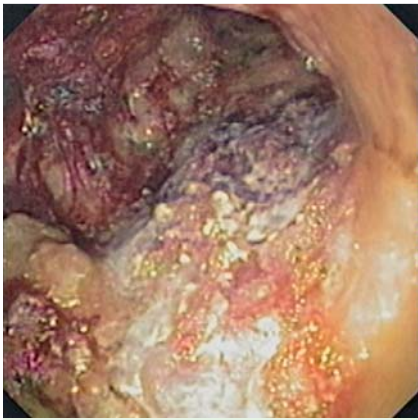

Fig. 4 Bleeding stopped successfully.

mass and gastric wall invasion. EGD showed a 6-cm ulcerating mass with oozing in the upper part of the lesser curvature (► **Fig. 2, 3**). A metal clip was applied at the bleeding site but failed to stop it. Therefore, Histoacryl was sprayed and the bleeding stopped (► **Fig. 4**). Lastly, a 62-year-old woman, a known case of advanced ampullary carcinoma invading the second portion of the duodenum, was

referred for EGD after failed epinephrine injection, argon plasma coagulation (APC), and angio-embolization. Histoacryl spray was again used to stop the bleeding. In our experience, the use of Histoacryl spray for initial hemostasis of bleeding tumors led to impressive results, with a low risk of immediate and delayed recurrent bleeding after the procedure. The procedure itself was easy to carry out and without complications. No special techniques or equipment were required. Therefore, in our opinion, this technique might be suitable as a bridging therapy for bleeding tumors after other failed interventions, but not as the primary method of treatment.

Endoscopy_UCTN_Code_TTT_1AO_2AD
Endoscopy_UCTN_Code_TTT_1AQ_2AZ

Competing interests: None

**V. Prachayakul, P. Aswakul,
U. Kachinthorn**

Siriraj Endoscopy Center, Department of Internal Medicine, Bangkok, Thailand

References

- 1 Anjiki H, Kamisawa T, Sanaka M *et al*. Endoscopic hemostasis techniques for upper gastrointestinal hemorrhage: A review. *World J Gastrointest Endosc* 2010; 2: 54–60
- 2 Garcia-Tsao G, Bosch J. Management of varices and variceal hemorrhage in cirrhosis. *N Engl J Med* 2010; 4: 823–831
- 3 Shida T, Takano S, Miyazaki M *et al*. Spraying N-butyl-2-cyanoacrylate (Histoacryl) might be a simple and final technique for bleeding gastrointestinal lesions. *Endoscopy* 2009; 41: E27–E28

Bibliography

DOI 10.1055/s-0030-1256350

Endoscopy 2011; 43: E227–E228

© Georg Thieme Verlag KG Stuttgart · New York · ISSN 0013-726X

Corresponding author

P. Aswakul

Siriraj Endoscopy Center
Siriraj Hospital – Internal Medicine
Siriraj Hospital
Prannok Road
Bangkok 10700
Thailand
Fax: +662-412-1088
asawakul@gmail.com