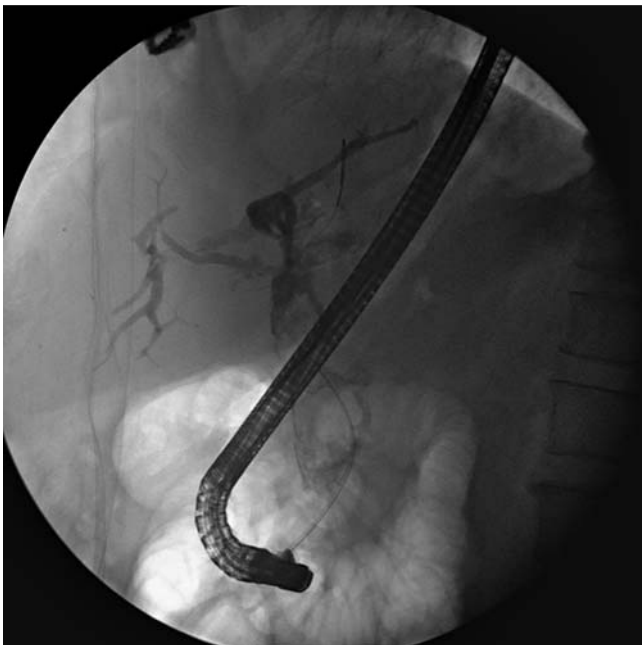

## Common bile duct stone removal with overtube-assisted direct peroral cholangioscopy, without balloon inflation, using an ultra-slim gastroscop following electrohydraulic lithotripsy

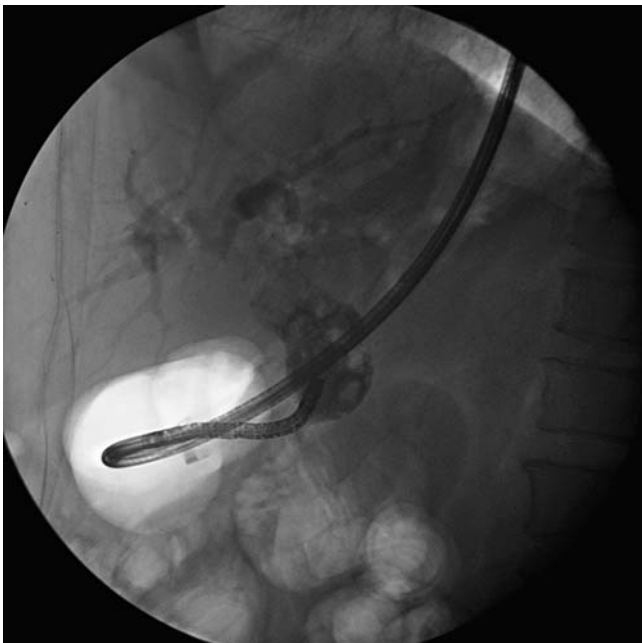We report a case of a 60-year-old woman who presented with obstructive jaundice due to a large (2.5 cm) stone in the common bile duct (CBD). We attempted mechanical lithotripsy but the stone was too big for the basket (▶ Fig. 1). We decided to break the stone with electrohydraulic lithotripsy (EHL) and carry out direct per-

oral cholangioscopy instead of mother-baby endoscopy. In our experience, the mother-baby endoscopic system has several disadvantages. The caliber of the working channel is too narrow and it requires two experienced endoscopists for carrying out the procedure. In addition, the baby endoscope is rather fragile and

we have had to very often send it back to the company for repair. Therefore, overtube-assisted direct peroral cholangioscopy using an ultra-slim gastroscop was the preferred intervention in this patient. Before the procedure, we made a hole at 70 cm from the distal end of the overtube of a single-balloon enteroscope (ST-SB1, Olympus, Tokyo, Japan) [1,2] (▶ Fig. 2). Then, an ultra-slim gastroscop (GIF-N260; Olympus, Tokyo, Japan) with a 2-mm working channel and 5.9-mm outer diameter was inserted through the hole. In the next step, first the CBD was cannulated with a duodenoscope using a sphincterotome and 0.035-inch jag wire, and then the duodenoscope was replaced with the ultra-slim gastroscop with the overtube over the wire. The overtube was advanced over the scope into the antrum. The overtube was useful for keeping the endoscope straight when inserted in the stomach as it prevented loop formation during advancement of the scope at a more accessible angle to the papilla. Then, without balloon inflation, the gastroscop was supported by the overtube and advanced over the wire into the bile duct (▶ Fig. 3). The CBD stone was visualized (▶ Fig. 4) and EHL was carried out to break the stone into several pieces. The stone fragments were removed using a



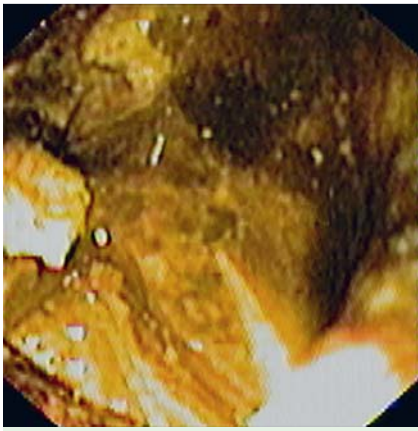
**Fig. 1** Cholangiogram revealing a large stone in the common bile duct.



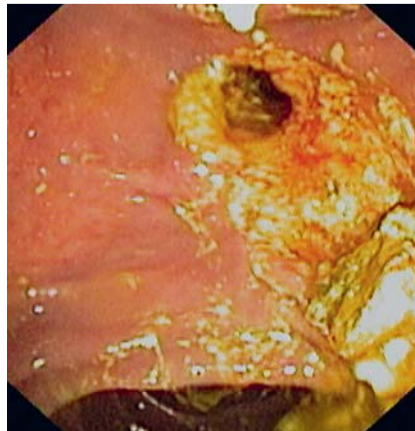
**Fig. 3** The ultra-slim gastroscop in the common bile duct; note that the balloon was not inflated.



**Fig. 2** The overtube with a hole at 70 cm from the distal end.



**Fig. 4** Endoscopic view of the common bile duct stone during electrohydraulic lithotripsy (EHL).



**Fig. 5** After electrohydraulic lithotripsy (EHL), the pieces of the common bile duct stone were removed using Dormia basket.

Dormia basket and balloon retrieval catheter (► **Fig. 5**). Finally, an occluded cholangiogram showed no residual CBD stones after the procedure.

In our opinion, overtube-assisted direct peroral cholangioscopy, which can be carried out by a single endoscopist, provides superior endoscopic images and a larger working channel than the mother-baby endoscopy. This method also improved the success rate, even though we do not

use balloon inflation as other endoscopists [3, 4].

Endoscopy\_UCTN\_Code\_TTT\_1AR\_2AK

**Competing interests:** None

**V. Prachayakul, P. Aswakul, U. Kachintorn**

Siriraj Endoscopy Center, Department of Internal Medicine, Siriraj Hospital, Bangkok, Thailand

## References

- 1 Moon JH, Ko BM, Choi HJ et al. Intraductal balloon-guided direct peroral cholangioscopy with an ultraslim upper endoscope. *Gastrointest Endosc* 2009; 70: 297–302
- 2 Moon JH, Ko BM, Choi HJ et al. Direct peroral cholangioscopy using an ultra-slim upper endoscope for the treatment of retained bile duct stones. *Am J Gastroenterol* 2009; 104: 2729–2733
- 3 Tsou YK, CH Lin, JH Tang et al. Direct POC with ultraslim endoscope and overtube balloon-assisted technique. *Endoscopy* 2010; 42: 681–683
- 4 Choi HJ, Moon JH, Ko BM et al. Overtube-balloon-assisted direct peroral cholangioscopy by using an ultra-slim upper endoscopy (with video). *Gastrointest Endosc* 2009; 69: 935–940

## Bibliography

**DOI** 10.1055/s-0030-1256351

*Endoscopy* 2011; 43: E273–E274

© Georg Thieme Verlag KG Stuttgart · New York · ISSN 0013-726X

## Corresponding author

**V. Prachayakul**

Siriraj Endoscopy Center  
Siriraj Hospital – Internal Medicine  
Siriraj Hospital  
Prannok Road  
Bangkoknoi  
Bangkok 10700  
Thailand  
Fax: +662-411-5013  
psprvaks@gmail.com, asawakul@gmail.com