

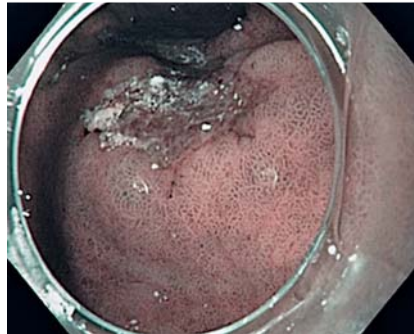## Fluorescein-aided endomicroscopy for detection of signet ring cell carcinoma

Confocal laser endomicroscopy is rapidly emerging as a new key technology for in vivo diagnosis, for example of Barrett's esophagus, celiac disease, and colonic polyps and their neoplastic counterparts [1]. Also, various studies have shown the potential of endomicroscopy for in vivo diagnosis of gastric cancer [2, 3]. However, fluorescein-aided endoscopic diagnosis of cancer can only detect architectural changes, because fluorescein does not provide direct nuclear visualization, and the appreciation of nucleus-to-cytoplasm ratio or pleomorphic nuclear changes cannot be used for diagnosis and grading of intraepithelial neoplasia. An alternative fluorescence agent, acriflavine hydrochloride, which is topically applied via standard spraying catheters, enables direct visualization of nuclei, but concerns about a potential mutagenic risk have been raised [1].

We describe the case of a 54-year-old woman who presented at our outpatient department with weight loss of 14 kg and mild abdominal pain that had lasted for the previous 2 months. Physical examination was unremarkable, while laboratory investigations showed mild anemia with hemoglobin of 10.2 g/dL (normal 12–16 g/dL).

High-resolution endoscopy revealed a large, superficial erosive lesion of 12 × 20 mm in diameter in the gastric antrum. Pit-pattern analysis of the lesion with narrow-band imaging (Olympus, Tokyo, Japan) revealed distinctive microvascular irregularities (● Fig. 1). Subsequent endoscopic examination of the esophagus, stomach, and duodenum were unremarkable.

After withdrawal of the endoscope (GIF H180; Olympus, Tokyo, Japan), we attached a clear cap to the end of the scope and administered 5 mL 10% fluorescein (Alcon Laboratories, Texas, USA) intravenously. Following reinsertion of the scope into the esophagus, the handheld probe-based confocal laser endomicroscope (pCLE; Cellvizio, Mauna Kea Technologies, Paris, France) was introduced through the working channel of the scope and gently pushed against the mucosal erosion. Fluorescein-guided endomicros-



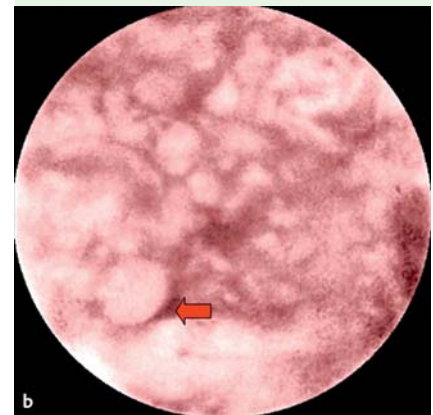
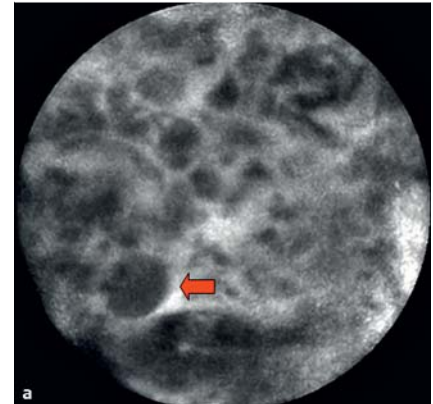
**Fig. 1** High-resolution endoscopy with narrow-band imaging revealed a superficial erosive lesion in the gastric antrum. A clear cap was attached to the distal tip of the endoscope in order to perform probe-based endomicroscopy.

copy showed disturbed mucosal architecture and large, irregular dark cells with thickened borders at one side (● Fig. 2a). Digital post-processing during the endoscopic procedure using a filter technology that enables virtual eosin staining (Cellvizio Viewer; Mauna Kea Technologies, Paris, France) enhances cell contrast, thereby clearly demonstrating large cells with large vacuoles full of mucin which displaces the nucleus to the periphery (● Fig. 2b). Based on these findings, in vivo diagnosis of signet ring cell carcinoma was made, which was later confirmed by corresponding histopathological analysis (● Fig. 3).

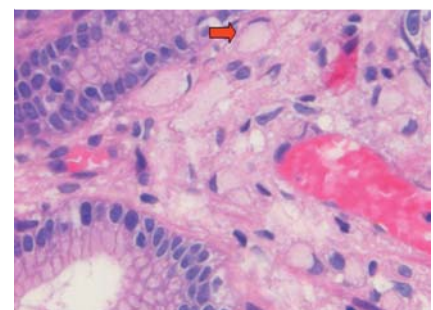
The tumor was finally staged as cT3N3M1 and the patient was put on intravenous FLOT (5-fluorouracil, leucovorin, oxaliplatin, and docetaxel) chemotherapy. Stable disease was achieved after the fourth course of chemotherapy, and the patient is currently free from symptoms (2 months after first diagnosis). This is the first report that fluorescein-aided endomicroscopy contributes to subtype classification of gastrointestinal cancer. Therefore, this report opens the door for future studies to evaluate the role of fluorescein-aided endomicroscopy in the diagnosis of gastrointestinal cancer.

Endoscopy\_UCTN\_Code\_TTT\_1AP\_2AD

**Competing interests:** None



**Fig. 2** a After intravenous injection of fluorescein, endomicroscopy was performed, showing disturbed mucosal architecture and large, irregular cells with thickened borders at one side (arrow). b Digital post-processing using a special filter technology that enables virtual eosin staining enhances cell contrast, thereby clearly demonstrating signet ring cells (arrow).



**Fig. 3** In vivo diagnosis of signet ring cell carcinoma (arrow) was confirmed in a corresponding histopathological slide.

H. Neumann<sup>1</sup>, M. Vieth<sup>2</sup>, J. Siebler<sup>1</sup>,  
T. Bernatik<sup>1</sup>, M. F. Neurath<sup>1</sup>,  
F. Boxberger<sup>1</sup>

<sup>1</sup> Department of Medicine I, University  
of Erlangen-Nuremberg, Erlangen,  
Germany

<sup>2</sup> Institute of Pathology, Klinikum  
Bayreuth, Bayreuth, Germany

## References

- 1 Neumann H, Kiesslich R, Wallace MB *et al.* Confocal laser endomicroscopy: technical advances and clinical applications. *Gastroenterology* 2010; 139: 388 – 392
- 2 Li WB, Zuo XL, Li CQ *et al.* Diagnostic value of confocal laser endomicroscopy for gastric superficial cancerous lesions. *Gut* 2011; 60: 299 – 306
- 3 Kitabatake S, Niwa Y, Miyahara R *et al.* Confocal endomicroscopy for the diagnosis of gastric cancer in vivo. *Endoscopy* 2006; 38: 1110 – 1114

## Bibliography

DOI 10.1055/s-0030-1256380

Endoscopy 2011; 43: E199 – E200

© Georg Thieme Verlag KG Stuttgart · New York ·  
ISSN 0013-726X

## Corresponding author

**H. Neumann, MD**

Department of Medicine I  
University of Erlangen-Nuremberg  
Ulmenweg 18  
91054 Erlangen  
Germany  
Fax: +49-9131-8535209  
helmut.neumann@uk-erlangen.de