

Malignant fibrous histiocytoma of the small bowel with colon metastasis

A 59-year-old man was admitted to the Institute of Gastroenterology with recurrent abdominal pain and weight loss. Colonoscopy revealed dark fecal content in the ileum (melena). A simple small-bowel follow-through was indicated, which showed the presence of a filling defect image in the jejunum, suggestive of a tumor in that location.

An antegrade double-balloon enteroscopy was indicated. Four ulcerated tumors (● Fig. 1) were observed immediately after the Treitz angle, separated by normal mucosa of about 10–15 cm, with severe lumen stenosis caused by the last tumor, which impeded the progress of the enteroscope (● Fig. 1 d). Biopsy specimens were studied at the Institute of Oncology, and pathological diagnosis was a pleomorphic malignant fibrous histiocytoma. The patient underwent surgery with resection of 150 cm of affected jejunum, with subsequent chemotherapy cycles. Months later, a follow-up computed tomography (CT) scan described a mass projecting between the hepatic flexure and transverse colon. Although anemia and leukopenia were controlled, the patient died months later after an episode of severe hematemesis. The histological analysis of the colon tumor proved it to be a metastasis of a pleomorphic malignant fibrous histiocytoma.

Malignant fibrous histiocytoma is a rare sarcoma in the digestive tract. There are fewer than 50 primary cases reported in world literature, and fewer than 10 metastatic cases [1,2].

Treatment relies on early diagnosis and resection of the intestinal block, with regional lymph node dissection [3]. Radiotherapy and/or chemotherapy have not been reported as useful because of the tumor's frequent recurrence [4]. A size greater than 5 cm is linked closely with the occurrence of metastasis [2,5].

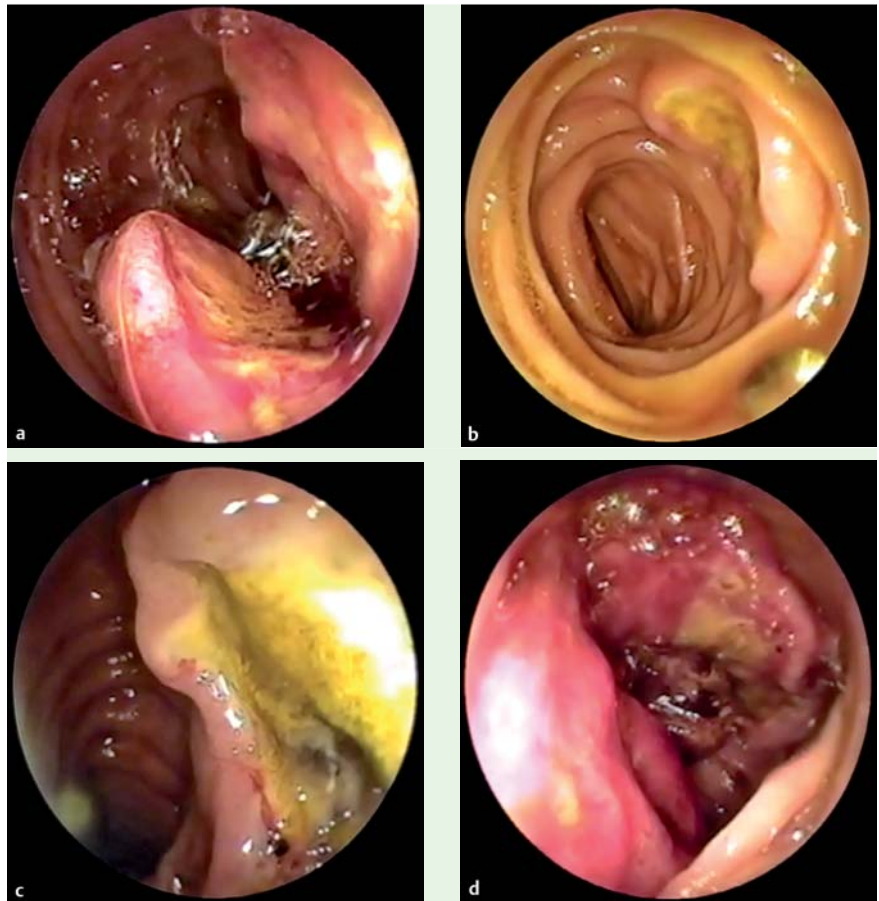


Fig. 1 a–c Jejunal tumors. d Fourth and last jejunal tumor, with stenosis of the lumen.

In our case, the patient was operated on before any evidence of metastasis, after double-balloon enteroscopy determined the presence of jejunal tumors. This allowed the removal of only the compromised intestinal block and improved the patient's quality of life for over a year.

Endoscopy_UCTN_Code_CCL_1AC_2AC
Endoscopy_UCTN_Code_CCL_1AD_2AC

Competing interests: None

O. M. Villa Jiménez¹, H. R. Hernández Garcés², C. Ruenes Domech², O. M. Hano García², S. Quintero Cayola³, J. L. Guerra Mesa⁴, F. Pérez Triana², L. Wood Rodríguez⁵

¹ Institute of Gastroenterology, Department of Small Bowel and Malabsorptive Diseases, Havana, Cuba

² Institute of Gastroenterology, Gastrointestinal Endoscopy Department, Havana, Cuba

³ Institute of Oncology and Radiobiology, Pathology Department, Havana, Cuba

⁴ Institute of Oncology and Radiobiology, Department of Splanchnic Surgery, Havana, Cuba

⁵ Institute of Gastroenterology, Department of Colorectal Disease, Havana, Cuba

References

- 1 *Agaimy A, Gaumann A, Schroeder J et al.* Primary and metastatic high-grade pleomorphic sarcoma/malignant fibrous histiocytoma of the gastrointestinal tract: an approach to the differential diagnosis in a series of five cases with emphasis on myofibroblastic differentiation. *Virchows Arch* 2007; 451: 949–957
- 2 *Fu DL, Yang F, Maskay A et al.* Primary intestinal malignant fibrous histiocytoma: two case reports. *World J Gastroenterol* 2007; 13: 1299–1302
- 3 *Okubo H, Ozeki K, Tanaka T et al.* Primary malignant fibrous histiocytoma of the ascending colon: report of a case. *Surg Today* 2005; 35: 323–327
- 4 *Zagars GK, Mullen JR, Pollack A.* Malignant fibrous histiocytoma: outcome and prognostic factors following conservation surgery and radiotherapy. *Int J Radiat Oncol Biol Phys* 1996; 34: 983–994
- 5 *Kearney MM, Soule EH, Ivins JC.* Malignant fibrous histiocytoma: a retrospective study of 167 cases. *Cancer* 1980; 45: 167–178

Bibliography

DOI 10.1055/s-0030-1256390
Endoscopy 2011; 43: E206–E207
© Georg Thieme Verlag KG Stuttgart · New York ·
ISSN 0013-726X

Corresponding author

O. M. Villa Jiménez, MD
Institute of Gastroenterology
Department of Small Bowel and Malabsorptive
Diseases
25 Number 503 Street
Havana 10400
Cuba
Fax: +537-8333253
villa@infomed.sld.cu