

Mucosal tears during colonoscopy in a patient with ulcerative colitis

A 66-year-old man had a 2-month history of bloody diarrhea. Except for partial gastroduodenectomy because of a duodenal ulcer, the subject was healthy and was not taking any regular medication. He had not recently visited any foreign countries. Physical examination was unremarkable. Routine laboratory tests and complete blood analysis were normal. Total colonoscopy was performed after standard bowel preparation, without sedation. Colonoscopic findings revealed diffuse edema, hyperemia, erosion, and granular mucosa from the rectum to the cecum (Fig. 1).

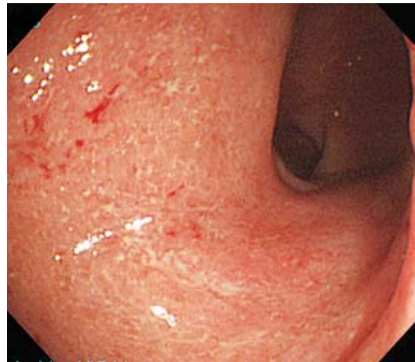

Fig. 1 Colonoscopic findings of diffuse edema, hyperemia, erosion, and granular mucosa from the rectum to the cecum.

On withdrawal of the endoscope longitudinal mucosal tears were noted in the transverse colon (Fig. 2), whereas such mucosal tears were not observed during the insertion of the endoscope.

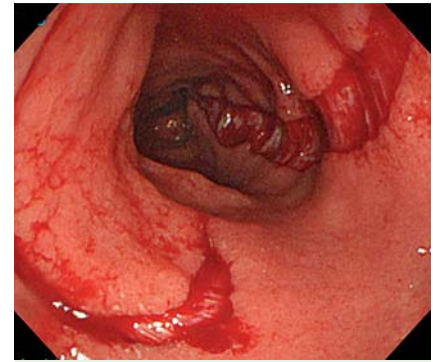


Fig. 2 Longitudinal mucosal tears were noted in the transverse colon during withdrawal of the endoscope.

Histopathological examination of samples taken from the cecum to the rectum showed moderate to severe mucosal inflammation with cryptitis, crypt destruction, and goblet cell depletion, without subepithelial deposition of a collagen band, which was consistent with the histological finding of ulcerative colitis (Fig. 3).

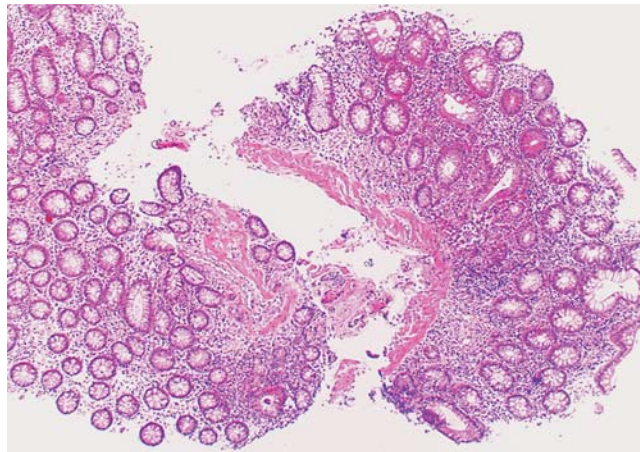


Fig. 3 Histopathological examination showed moderate to severe mucosal inflammation without subepithelial deposition of a collagen band, findings which were consistent with the histological finding of ulcerative colitis.

Richieri et al. reported the unique clinical presentation of longitudinal mucosal tears for the first time in a patient with collagenous colitis [1]. Endoscopic examination usually reveals normal colonic mucosa, although minimal mucosal edema and hyperemia may be present; however, mucosal tears or fracture are characteristic of collagenous colitis [2].

To date, mucosal tears have not been reported in patients with ulcerative colitis, except for a case report of mucosal tears occurring on remnant rectal mucosa on endoscopic insufflation in a patient with ulcerative colitis [3]. Mucosal tears have not been reported in the colonic mucosa of patients with ulcerative colitis, therefore mucosal inflammation alone is not sufficient to explain the cause of mucosal tears in the colonic mucosa. Owing to the possible occurrence of mucosal tears that will lead to colonic perforation, careful colonoscopic examination is required, even in the case of ulcerative colitis patients with mildly active mucosa.

Competing interests: None

N. Oshitani¹, K. Aomatsu¹, H. Yamagami², R. Ogawa³

¹ Department of Gastroenterology, Izumiotsu Municipal Hospital, Osaka, Japan

² Department of Gastroenterology, Osaka City University Graduate School of Medicine, Osaka, Japan

³ Medical Care and Medical Center, Osaka Medical Association, Osaka, Japan

References

- 1 Richieri J-P, Bonneau H-P, Cano N et al. Collagenous colitis: an unusual endoscopic appearance. *Gastrointestinal Endosc* 1993; 39: 192–194
- 2 Allende DS, Taylor SL, Bronner MP. Colonic perforation as a complication of collagenous colitis in a series of 12 patients. *Am J Gastroenterol* 2008; 103: 2598–2604
- 3 Hata K, Watanabe T, Kanazawa T et al. Mucosal tears on endoscopic insufflation. *Gut* 2003; 52: 613

Bibliography

DOI 10.1055/s-0030-1256396

Endoscopy 2011; 43: E215

© Georg Thieme Verlag KG Stuttgart · New York · ISSN 0013-726X

Corresponding author

Nobuhide Oshitani

Department of Gastroenterology

Izumiotsu Municipal Hospital

16-1, Shimojuou-machi

Izumiootsu City

Osaka 595-3027

Japan

endoscope@hosp-ozu-osaka.jp