

Mixed cavernous hemangioma-lymphangioma of the jejunum: detection by wireless capsule endoscopy

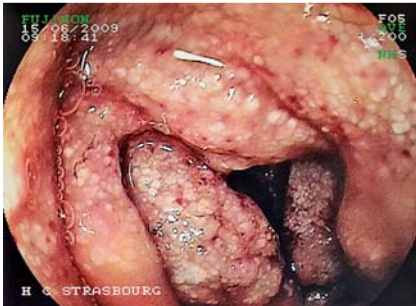

Fig. 1 Case 1. Double-balloon endoscopy showing a large hemi-circumferential lesion, with whitish carpet-like villi and red spots.

A 26-year-old woman (case 1) was referred for evaluation of recurrent episodes of melena. Gastroscopy, colonoscopy with ileoscopy, and small-bowel computed tomography (CT) scan were normal. Capsule endoscopy (Pill cam SB 2, Given Imaging, Yoqneam, Israel) disclosed a lesion with whitish carpet-like villi and superficial red spots with spontaneous bleeding at the proximal jejunum. At double-balloon enteroscopy (Fujinon, Saitama, Japan) the lesion occupied two-thirds of the lumen (● Fig. 1).

The involved segment was resected by laparoscopy (● Fig. 2).

Microscopy showed a mixed lesion with a central core of dilated cavernous vascular channels surrounded by dilated lymphatic vessels (● Fig. 3).

The diagnosis of a mixed cavernous hemangioma-lymphangioma was confirmed by immunostaining [1] (● Fig. 4).

A 59-year-old man (case 2) was admitted for two episodes of melena. Gastroscopy and colonoscopy were normal. Capsule enteroscopy revealed a polypoid lesion covered by whitish and red spots at the proximal jejunum (● Fig. 5), which was confirmed on double-balloon enteroscopy.

The patient underwent single-port laparoscopy and the involved segment was resected. The lesion, 3.5 cm × 7 cm in size, corresponded to a mixed cavernous hemangioma-lymphangioma.

Gastrointestinal cavernous hemangiomas are congenital benign vascular lesions that are usually located in the jejunum. Their endoscopic appearance at enteros-

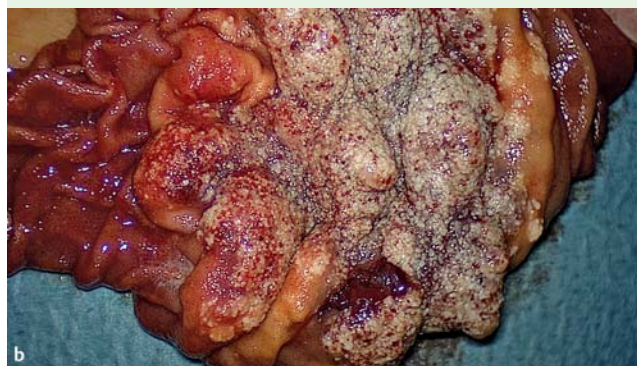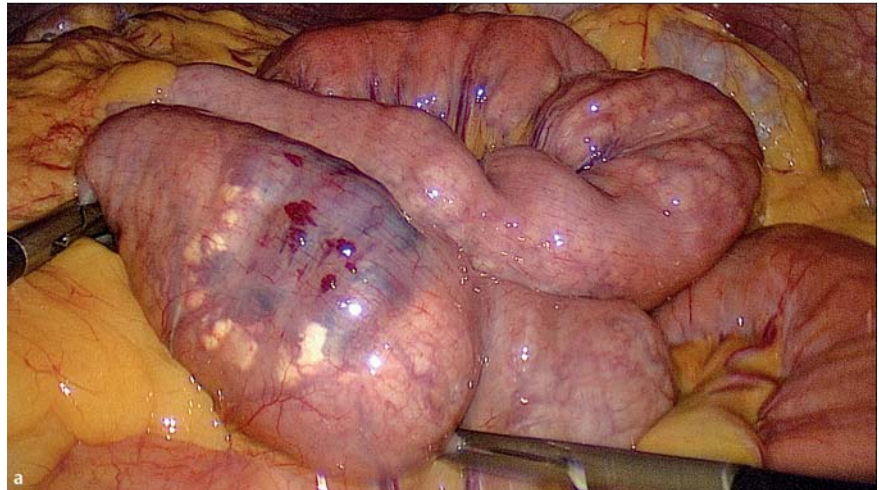


Fig. 2 Case 1. **a** The lesion was easily identified at laparoscopy because of its central bluish appearance, surrounded by whitish lymphatic tissue. **b** Internal aspect of the surgical specimen.

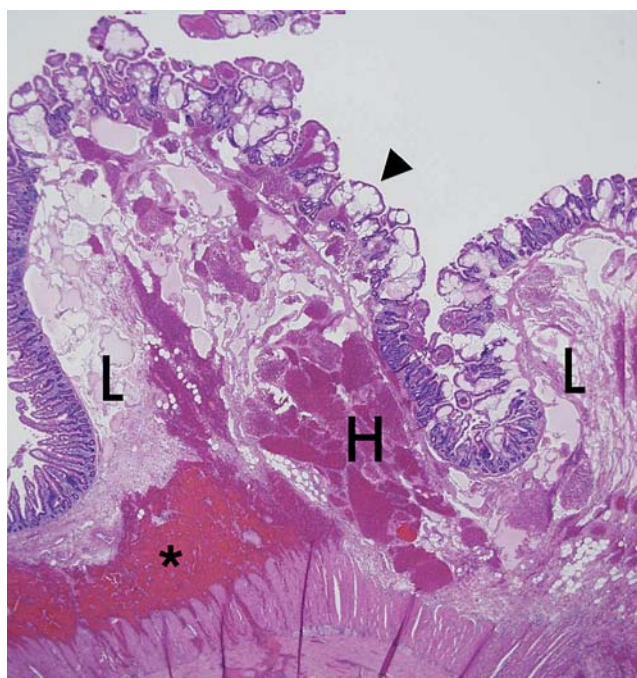


Fig. 3 Case 1. The lesion involving the mucosa and the submucosa is a cavernous hemangioma (H) surrounded by dilated cavernous lymphatic channels (L). The overlying intact mucosa is thickened by numerous lymphangiectasis (arrowhead). The asterisk indicates a focal hemorrhage in contact with the muscularis propria (hematoxylin and eosin staining; original magnification × 20).

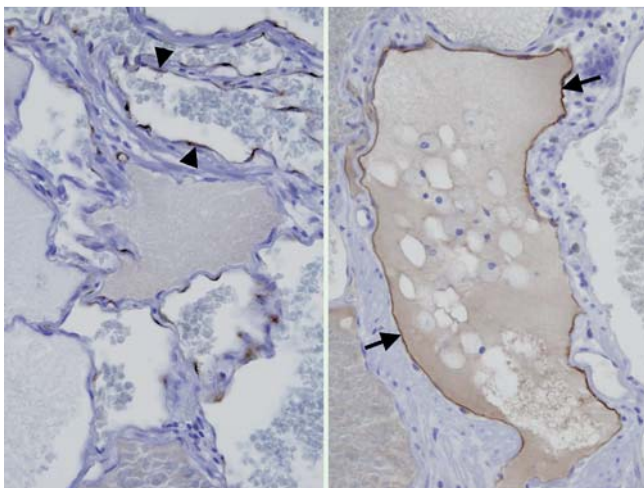


Fig. 4 Case 1. Immunohistochemistry helped to differentiate between hemangioma and lymphangioma. Factor VIII stained the endothelium of the blood channels (left side; arrowheads), while D2-40 stained the endothelium of lymphatic channels (right side; arrows) (original magnification $\times 400$).

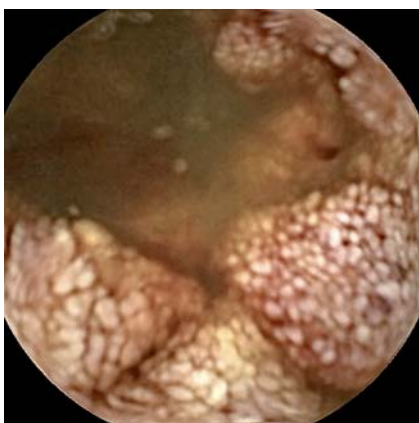


Fig. 5 Case 2. Capsule endoscopy: vascular lesion with whitish spots resembling lymphangiectasis.

copy or capsule endoscopy is usually of a sessile or polypoid, bluish or red lesion [2–4]. However, in our two cases, the surface of the hemangioma was covered by white spots, suggesting a lymphatic component. The mixed pattern of lymphatic-vascular tissue was confirmed on histological examination. Mixed hemangioma-lymphangioma has been previously described at the colon and the designation of hemangiolympangioma has been proposed [5]. The images presented here are the first by means of capsule endoscopy and double-balloon enteroscopy. This histological variation should be kept in mind in the differential diagnosis of vascular lesions with lymphangiectasias.

Endoscopy_UCTN_Code_CCL_1AC_2AB

Competing interests: None

G. Mavrogenis¹, D. Coumaros¹, N. Lakhrib¹, C. Renard², J. P. Bellocq², J. Leroy³

- ¹ Department of Gastroenterology, University Hospital, Strasbourg, France
² Department of Histopathology, University Hospital, Strasbourg, France
³ Department of Digestive Surgery, University Hospital, Strasbourg, France

References

- 1 Kahn HJ, Bailey D, Marks A. Monoclonal antibody D2-40, a new marker of lymphatic endothelium, reacts with Kaposi's sarcoma and a subset of angiosarcomas. *Mod Pathol* 2002; 15: 434–440
- 2 Chen CH, Jones J. Profound iron deficiency anemia caused by a small-intestinal cavernous hemangioma. *Gastrointest Endosc* 2009; 69: 1392–1393
- 3 Quentin V, Lermite E, Lebigot J et al. Small bowel cavernous hemangioma: wireless capsule diagnosis of a surgical case. *Gastrointest Endosc* 2007; 65: 551–552
- 4 Willert RP, Chong AK. Multiple cavernous hemangiomas with iron deficiency anemia successfully treated with double-balloon enteroscopy. *Gastrointest Endosc* 2008; 67: 765–766
- 5 Sylla P, Deutsch G, Luo J et al. Cavernous, arteriovenous, and mixed hemangioma-lymphangioma of the rectosigmoid: rare causes of rectal bleeding-case series and review of the literature. *Int J Colorectal Dis* 2008; 23: 653–658

Bibliography

DOI 10.1055/s-0030-1256400

Endoscopy 2011; 43: E217–E218

© Georg Thieme Verlag KG Stuttgart · New York · ISSN 0013-726X

Corresponding author

D. Coumaros

IRCAD/EITS

University Hospital

1 Place de l'Hôpital

67091 Strasbourg

France

Fax: +333-887-51521

coumarosd@wanadoo.fr