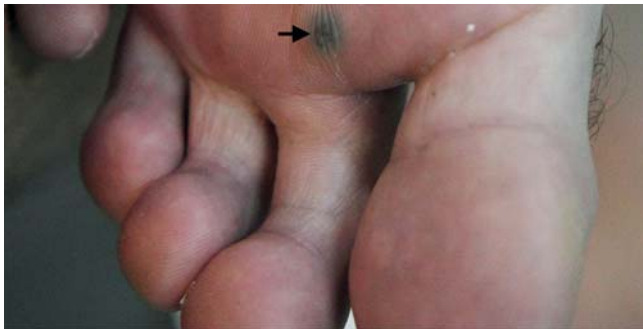
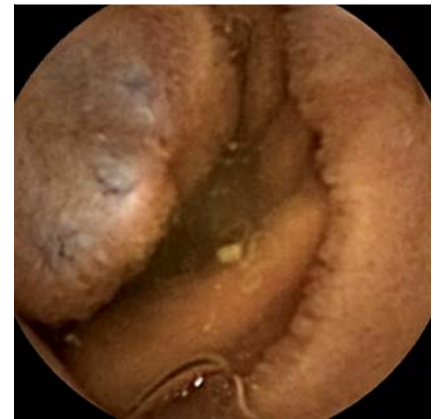
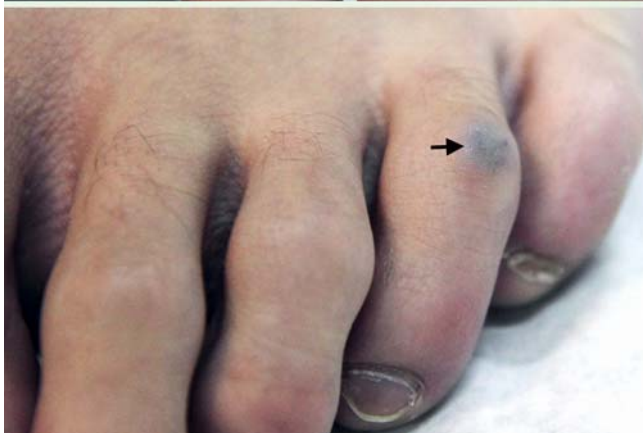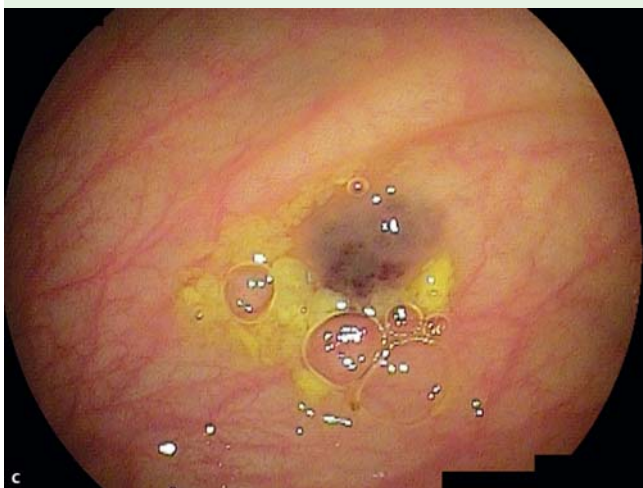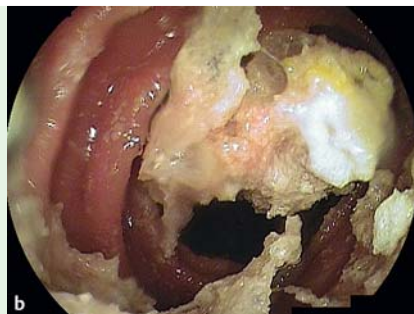
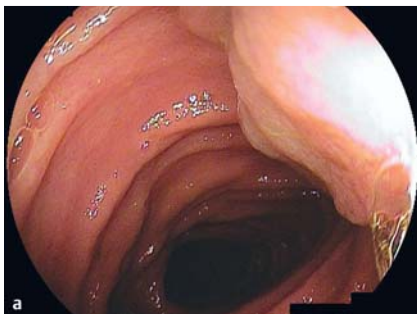
## Cyanoacrylate glue in the management of blue rubber bleb nevus syndrome



**Fig. 1** Case 1. Hemangiomas of the foot.



**Fig. 2** Case 1. Capsule endoscopy picture of a bluish, nipple-like rubbery vascular lesion of the jejunum, compatible with a blue rubber bleb nevus.



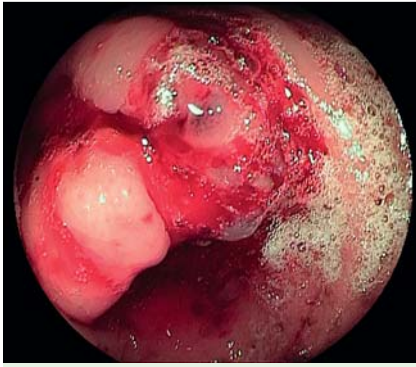
**Fig. 3** **a** Case 1. Hemangioma of the proximal jejunum. **b** Solidification of the glue inside the lumen. Inadvertent sticking of the needle inside the lesion or adherence of the glue to the needle was avoided by flushing at least 2 ml water for injection after each aliquot of Glubran 2 and Lipiodol. **c** Typical lesion of the transverse colon.

Case 1. A 16-year-old boy with blue rubber bleb nevus syndrome (BRBNS) was admitted for occult bleeding. He had a history of gastric and colonic hemangiomas treated 2 years earlier by argon plasma coagulation and alcohol injection respectively. Clinical examination showed a few hemangiomas on his back and feet (● Fig. 1).

Capsule endoscopy (Pillcam SB2; Given Imaging, Yoqneam, Israel) disclosed three blebs of the small bowel (● Fig. 2), and the patient underwent double-balloon enteroscopy (Fujinon, Saitama, Japan).

A 2-cm bleb was found at the jejunum, two smaller lesions at the ileum, and one at the transverse colon. N-butyl-2-cyanoacrylate and methacryloxysulfolane (Glubran 2), 1 ml, diluted with Lipiodol, 1 ml, was injected in aliquots of 1 ml per injection and up to 4 ml at each lesion (● Fig. 3). No complications occurred. At 6-month follow-up the patient had no anemia.

Case 2. An 11-year-old girl with BRBNS was addressed for hematochezia due to colonic blebs. Colonoscopy revealed a bleeding lesion at the cecum (● Fig. 4). After initial failure to stop the bleeding with a hemostatic grasper (Coagrasper, Olympus), Glubran 2 was injected successfully. Two more blebs of the right colon were treated similarly. After 2 years the patient remained asymptomatic.



**Fig. 4** Case 2. Bleeding hemangioma of the cecum near the ileocecal valve.

BRBNS is a rare condition characterized by multiorgan cavernous hemangiomas. Gastrointestinal bleeding is the major problem, and several endoscopic therapeutic approaches have been proposed: Nd:YAG laser, bipolar or argon plasma coagulation, band ligation, snare resection, and sclerotherapy [1–4]. Our patients were treated successfully by Glubran 2 injection, commonly used in the management of gastric varices. Endoscopic obliteration of cavernous hemangiomas with

n-butyl-2-cyanoacrylate (Histoacryl) has been previously described, in the rectum [5]. However, these appear to be the first cases of cyanoacrylate glue injection to control bleeding in the small bowel and colon in the setting of BRBNS.

Endoscopy\_UCTN\_Code\_TTT\_1AO\_2AD

**Competing interests:** None

**G. Mavrogenis<sup>1</sup>, D. Coumaros<sup>1</sup>,  
D. Tzilves<sup>1</sup>, E. Rapti<sup>1</sup>, G. Stefanidis<sup>2</sup>,  
J. Leroy<sup>3</sup>, F. Becmeur<sup>4</sup>**

<sup>1</sup> Department of Gastroenterology, University Hospital, Strasbourg, France

<sup>2</sup> Department of Gastroenterology, Athens Naval Hospital, Athens, Greece

<sup>3</sup> Department of Digestive Surgery, University Hospital, Strasbourg, France.

<sup>4</sup> Department of Pediatric Surgery, University Hospital, Strasbourg, France

#### References

1 *Shahed M, Hagenmüller F, Rösch T et al.* A 19-year-old female with blue rubber bleb nevus syndrome. Endoscopic laser photocoagulation and surgical resection of gastrointestinal angiomata. *Endoscopy* 1990; 22: 54–56

2 *Maunoury V, Turck D, Brunetaud JM et al.* Blue rubber bleb nevus syndrome. 3 cases treated with a Nd:YAG laser and bipolar electrocoagulation [in French with English abstract]. *Gastroenterol Clin Biol* 1990; 14: 593–595

3 *Bak YT, Oh CH, Kim JH.* Blue rubber bleb nevus syndrome: endoscopic removal of the gastrointestinal hemangiomas. *Gastrointest Endosc* 1997; 45: 90–92

4 *Arguedas MR, Wilcox CM.* At the focal point. Blue rubber bleb nevus syndrome. *Gastrointest Endosc* 1999; 50: 544

5 *Zurakowski J, Swiercz P, Wróblewski T et al.* Diffuse cavernous hemangioma of rectosigmoid colon treated with n-butyl-2-cyanoacrylate injections. *Endoscopy* 2008; 40: E120–121

#### Bibliography

**DOI** 10.1055/s-0030-1256425

*Endoscopy* 2011; 43: E291–E292

© Georg Thieme Verlag KG Stuttgart · New York · ISSN 0013-726X

#### Corresponding author

**D. Coumaros, MD**

IRCAD/EITS

University Hospital

1 Place de l'Hôpital

67091 Strasbourg

France

Fax: +33-3-88751521

coumarosd@wanadoo.fr