

Large gastric heterotopia presenting as an obstructing duodenal mass

Gastric heterotopia is an ectopic lesion found throughout the gastrointestinal tract. The classic endoscopic appearance of gastric heterotopia is raised, salmon-colored mucosal patches or clusters of nodules above normal duodenal mucosa, ranging in size from 3 mm to 10 mm [1]. Large polypoid gastric heterotopia of the duodenum, defined as being greater than 2.5 cm, is rare and clinical relevance has only been described on one other occasion [2]. We report the first published case of a large polypoid gastric heterotopia of the duodenum causing obstructive symptoms and diagnosed by endoscopy.

A 21-year-old woman was evaluated in October 2006 for complaints of dyspepsia, nausea, and vomiting. She was initially treated with lansoprazole. By February 2007, the patient developed early satiety, inability to tolerate solid foods, and lost 9 kg (20 lb) in weight. An upper gastrointestinal series noted narrowing of the second part of the duodenum. An esophagogastroduodenoscopy (EGD) demonstrated a single, pedunculated polypoid mass in the duodenum with the base originating near the major papilla, measuring over 4 cm (● Fig. 1). Histological findings were consistent with gastric heterotopia.

A modified abdominal computed tomography (CT) scan with three-dimensional reconstruction demonstrated a 4.5 × 2.5 cm polypoid mass with a broad-based attachment along the posterior aspect of the second part of the duodenum. Piecemeal resection was attempted on two subsequent EGDs with approximately 50% of the lesion excised (● Fig. 2 and 3). However, only temporary symptomatic relief was achieved. The patient underwent surgical resection with complete symptom resolution.

Gastric heterotopia presenting as a large polypoid mass is a rare finding. Clinically significant lesions are typically found in the jejunum and ileum [1,3–5]. There has only been one reported case of symptomatic, duodenal gastric heterotopia since 1927 [2]. The present case illustrates a rare, large polypoid lesion of gastric heterotopia causing obstructive symptoms in a young woman. Although endoscopic

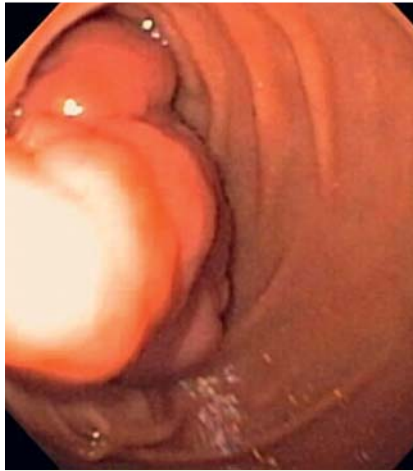

Fig. 1 Pedunculated, polypoid mass causing obstruction in the second portion of the duodenum on initial upper endoscopy.

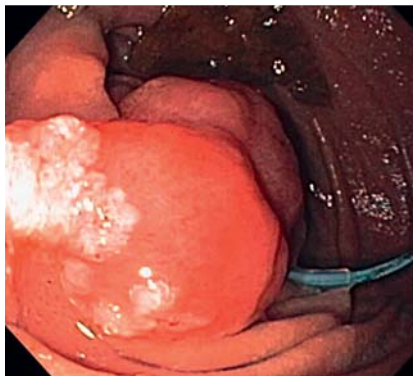


Fig. 2 The polypoid mass following piecemeal resection.

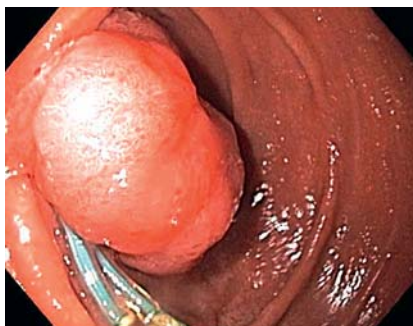

Fig. 3 Residual gastric heterotopia following two attempts at piecemeal resection and detachable snares.

treatment with piecemeal resection was unsuccessful for our patient, it remains a potential therapeutic option.

Endoscopy_UCTN_Code_CCL_1AB_2AZ_3AB

Competing interests: The views expressed in this article are those of the authors and should not be consumed to represent those of the U. S. Department of Defense, or the U. S. Department of the Army.

R. K. Fincher¹, M. Donovan²

¹ D. D. Eisenhower Army Medical Center, Fort Gordon, and Medical College of Georgia, Augusta, Georgia, USA

² D. D. Eisenhower Army Medical Center, Fort Gordon, Georgia, USA

References

- 1 Mann NS, Mann SK, Rachut E. Heterotopic gastric tissue in the duodenal bulb. *J Clin Gastroenterol* 2000; 30 (3): 303–306
- 2 Cynn WS, Rickert RR. Heterotopic gastric mucosal polyp in the duodenal bulb associated with congenital absence of the gallbladder. *Am J Gastroenterol* 1973; 60: 171–177
- 3 Lambert MP, Heller DS, Bethel C. Extensive gastric heterotopia of the small intestine resulting in massive gastrointestinal bleeding, bowel perforation, and death: report of a case and review of the literature. *Pediatr Dev Pathol* 2000; 3 (3): 277–280
- 4 Khan MJ, Mullerat P, Desai A. A polypoid gastric heterotopia of jejunum diagnosed by capsule endoscopy. *J Coll Physicians Surg Pak* 2009; 19: 661–662
- 5 Omotosho PA, Varnholt H, Tirabassi MV et al. Giant polypoid gastric heterotopia of the jejunum presenting with intermittent intussusceptions. *J Laparoendosc Adv Surg Tech A* 2007; 17 (2): 249–251

Bibliography

DOI 10.1055/s-0030-1256452

Endoscopy 2011; 43: E246

© Georg Thieme Verlag KG Stuttgart · New York · ISSN 0013-726X

Corresponding author

R. K. Fincher, MD, FACP, FACC

D. D. Eisenhower Army Medical Center
Fort Gordon
Georgia 30905
USA

Fax: +706-787-2409

keithfincher@comcast.net