

Dysphagia caused by migrated mesh after paraesophageal hernia repair

The placement of expanded polytetrafluoroethylene (ePTFE) mesh to reinforce the crural hiatal closure in laparoscopic antireflux surgery, has proved to be useful in preventing hiatal hernia recurrence and reducing the risk of postoperative migration of the wrap into the chest [1].

We report the case of a 71-year-old woman who was referred for progressive dysphagia and weight loss 2 years after undergoing Nissen fundoplication with the placement of a ePTFE mesh for a large paraesophageal hernia. An esophagogram (● Fig. 1) revealed multiple air bubbles in the upper esophagus, with passage of contrast into the bronchial tree. The radiological contrast flowed into the stomach thorough a stenosis of about 1 cm in diameter. Endoscopy revealed a mesh located at 22 cm from the dental arch in the esophageal lumen, like a prosthesis that had rotated on its axis (● Fig. 2). The mesh was firmly fixed and impossible to move, preventing the progression of the endoscope. Because of the patient's age, associated comorbidity, the impossibility of endoscopic treatment, and the complexity of possible surgery, a decision was made to commence palliative treatment and a gastrostomy was created without any other complications.

Although the use of ePTFE mesh in the laparoscopic surgical repair of hiatal hernia has proved to be safe, migration into the chest cavity is a rare complication, comprising approximately 0.5% of complications in large series [2]. In exceptional cases, transmural migration into the gastrointestinal tract has been observed [3–5]. Dysphagia in the immediate postoperative period is common in these patients and should disappear in the short term; however, if dysphagia occurs later, as in our patient, migration of the prosthesis into the thoracic cavity or transmural dislodgment towards the lumen of the upper gastrointestinal tract should be ruled out.

Endoscopy_UCTN_Code_CCL_1AB_2AC_3AH

Competing interests: None

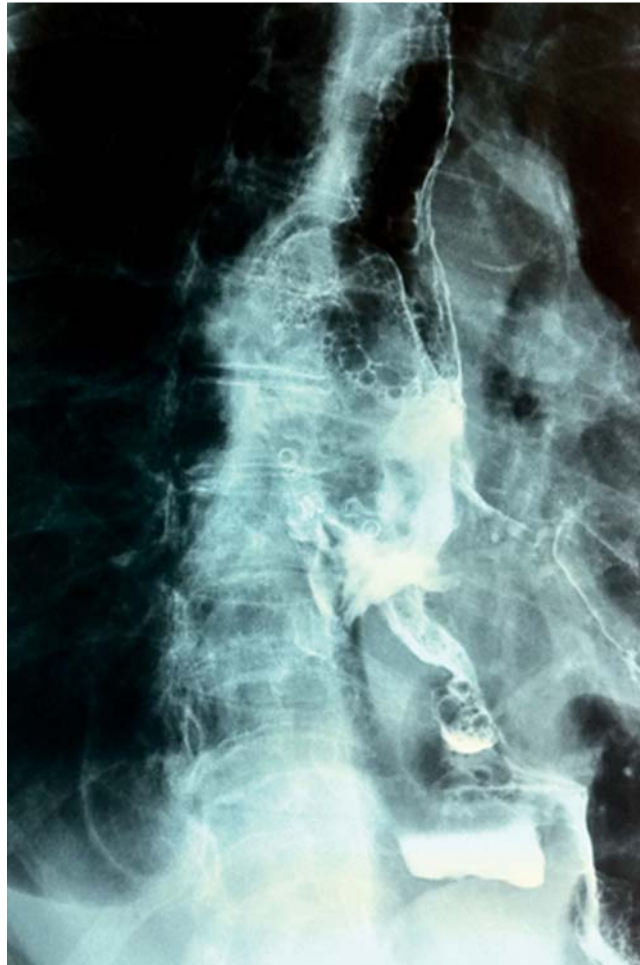

Fig. 1 Esophagogram showing multiple air bubbles in the upper esophagus with passage of contrast into the bronchial tree, and distal stenosis with a sliding hiatal hernia.

Q. Arroyo¹, F. Argüelles-Arias¹, M. Jimenez-Saenz², J. M. Herrerias-Gutierrez², F. Pellicer Bautista³

¹ Division of Digestive Diseases, Virgen Macarena University Hospital, Seville, Spain

² Division of Gastroenterology, Virgen Macarena University Hospital, Seville, Spain

³ Endoscopy Unit, Virgen Macarena's Hospital, Seville, Spain

References

- 1 Zilberstein B, Eshkenazy R, Pajeccki D et al. Laparoscopic mesh repair antireflux surgery for treatment of large hiatal hernia. *Dis Esophagus* 2005; 18: 166–169
- 2 Soricelli E, Basso N, Genco A et al. Long-term results of hiatal hernia mesh repair and antireflux laparoscopic surgery. *Surg Endosc* 2009; 23: 2499–2504
- 3 Coluccio G, Ponzio S, Ambu V et al. Dislocation into the cardial lumen of a PTFE prosthesis used in the treatment of voluminous hiatal sliding hernia. A case report. *Minerva Chir* 2000; 55: 341–345
- 4 Hergueta-Delgado P, Marin-Moreno M, Morales-Conde S et al. Transmural migration of a prosthetic mesh after surgery of a paraesophageal hiatal hernia. *Gastrointest Endosc* 2006; 64: 120–121
- 5 Carpelan-Holmström M, Kruuna O, Salo J et al. Late mesh migration through the stomach wall after laparoscopic refundoplication using a dual-sided PTFE/ePTFE mesh. *Hernia* 2011; 15: 217–220

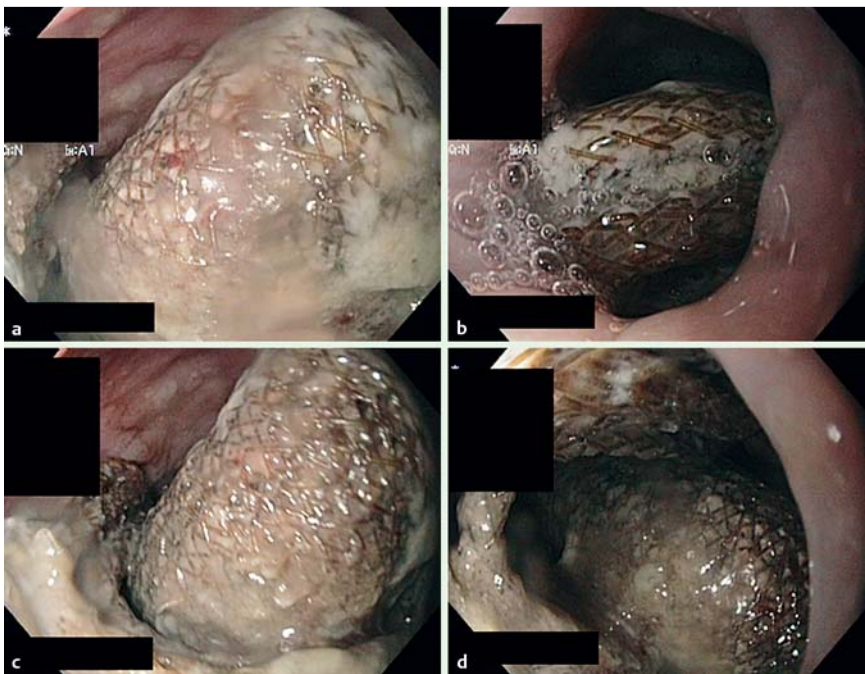


Fig. 2 A migrated mesh is seen in the esophagus, occupying the lumen as a 'prosthesis' that had rotated on its axis.

Bibliography

DOI 10.1055/s-0030-1256520

Endoscopy 2011; 43: E257 – E258

© Georg Thieme Verlag KG Stuttgart · New York ·
ISSN 0013-726X

Corresponding author

Q. Arroyo

Division of Digestive Diseases
Virgen Macarena University Hospital
Seville
Spain
quetzalihuit@hotmail.com