

Acute hemorrhagic colitis induced by the oral administration of oseltamivir used for influenza A treatment

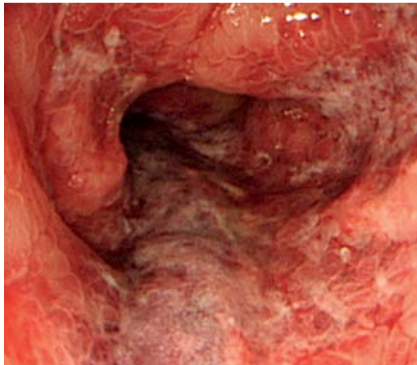


Fig. 1 Colonoscopic findings in the descending colon showing acute circumferential hemorrhagic colitis, with hemorrhage, edema, segmental erythema, and longitudinal erosion.

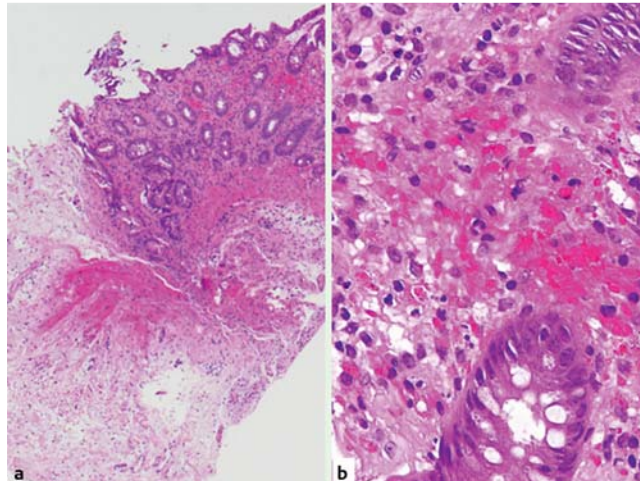


Fig. 2 Photomicrographs of the hematoxylin and eosin (H&E)-stained biopsy specimens from the descending colon showing: **a** mucosal hemorrhage and submucosal edema, magnification $\times 40$; **b** mucosal hemorrhage, magnification $\times 400$.

A 40-year-old woman with a history of bronchial asthma was diagnosed with influenza A using a rapid diagnosis kit. She began to experience abdominal pain, diarrhea, and hematochezia approximately 4 hours after a single capsule of oseltamivir had been administered. Colonoscopic findings indicated circumferential hemorrhagic colitis with longitudinal erosions in the descending colon, findings which mimicked those of ischemic colitis (▶ Fig. 1). Histopathological analysis of the lesion showed the presence of mucosal hemorrhage and submucosal edema (▶ Fig. 2). Stool culture showed normal flora. Discontinuation of the oseltamivir therapy was followed by an immediate improvement in the hemorrhagic colitis. The lymphocyte transformation test (LTT) yielded positive results for oseltamivir only, with negative results for the other drugs administered, which included clarithromycin and acetaminophen.

Oseltamivir, a neuraminidase inhibitor, plays a key role in the management of influenza. The most commonly reported adverse effect of oseltamivir is gastrointestinal discomfort [1, 2]. Oseltamivir-induced acute hemorrhagic colitis (OAH) is very rare, and to the best of our knowledge, there has been only one case of OAH reported in the literature in English [3]. However, the Japanese Ministry of Health, Labor and Welfare provided data on oseltamivir-linked gastrointestinal bleeding, and consequently, the summary of pro-

duct characteristics for oseltamivir was modified in 2005 to include hemorrhagic colitis.

Matsushita et al. reported that ischemia might be involved in the pathogenesis of OAH [3]. The colonoscopic findings in our patient, who had no other risk factors for ischemia, mimicked those of ischemic colitis. Toffler et al., in their report, attributed ischemia to allergic vasculitis [4]. The positive LTT results for our patient suggest that the OAH was induced by drug allergy; however, the detailed mechanism that underlies OAH has not been clarified. To the best of our knowledge, this is the first report in English that details a case of OAH with positive LTT results for oseltamivir. In conclusion, the risk of OAH must be considered before prescribing the drug.

Endoscopy_UCTN_Code_CCL_1AD_2AJ

Competing interests: None

Y. Nakagawa¹, T. Nagai¹, H. Okawara¹, H. Nakashima¹, A. Hisamatsu¹, M. Shuto¹, M. Yamauchi¹, S. Kai², S. Yokoyama³, K. Murakami⁴, T. Fujioka⁴

¹ Department of Gastroenterology, Oita Kouseiren Tsurumi Hospital, Beppu, Japan

² Department of Pathology, Oita Kouseiren Tsurumi Hospital, Beppu, Japan

³ Department of Pathology, Faculty of Medicine, Oita University, Yufu, Japan

⁴ Department of General Medicine and Gastroenterology, Faculty of Medicine, Oita University, Yufu, Japan

References

- 1 Nicholson KG, Aoki FY, Osterhaus AD et al. Efficacy and safety of oseltamivir in treatment of acute influenza: a randomized controlled trial. Neuraminidase Inhibitor Flu Treatment Investigator Group. *Lancet* 2000; 355: 1845–1850
- 2 Treanor JJ, Hayden FG, Vrooman PS et al. Efficacy and safety of the oral neuraminidase inhibitor oseltamivir in treating acute influenza: a randomized controlled trial. US Oral Neuraminidase Study Group. *JAMA* 2000; 283: 1016–1024
- 3 Matsushita M, Nishihara H, Nishiyama R, Kobayashi Y. Acute hemorrhagic colitis associated with oral administration of oseltamivir for the treatment of influenza A. *J Infect Chemother* 2007; 13: 267–269
- 4 Toffler RB, Pingoud EG, Burrell MI. Acute colitis related to penicillin and penicillin derivatives. *Lancet* 1978; 2: 707–709

Bibliography

DOI 10.1055/s-0030-1256524

Endoscopy 2011; 43: E261

© Georg Thieme Verlag KG Stuttgart · New York · ISSN 0013-726X

Corresponding author

Y. Nakagawa, MD

Department of Gastroenterology
Oita Kouseiren Tsurumi Hospital
Tsurumi, 4333
Beppu 874-8585
Japan
Fax: +81-97-7237039
nakagawa4423@ybb.ne.jp