

Jejunogastric intussusception causing gastrointestinal bleeding

A 66-year-old man presented to the emergency room with history of hematemesis without melena or postural symptoms. He complained of diffuse, crampy abdominal pain with no specific aggravating or relieving factors. He had undergone surgery for a bleeding ulcer 22 years ago, details of which were not available. On examination, he was pale and there was a firm mass with ill-defined margins in the left lumbar region. Investigations revealed low hemoglobin (7.3 gm/dL) and gastroscopy revealed a large, congested mass occupying the body and antrum of the stomach (● Fig. 1).

Contrast-enhanced computed tomography (CT) of the abdomen (● Fig. 2) showed telescoping of the proximal small bowel and mesenteric vessels into the stomach.

The patient was diagnosed as having jejunogastric intussusception. He underwent surgery, at which 60 cm (2 ft) of the efferent loop of the gastrojejunostomy was found to have intussuscepted into the stomach. The bowel appeared gangrenous and was resected.

Jejunogastric intussusception is a rare complication of gastrojejunostomy that may occur from within a week to even 50 years after the primary gastric surgery [1]. Patients usually present with acute epigastric pain, vomiting, and hematemesis. Some patients may have epigastric tenderness and a palpable mass. A chronic form with recurrent self-limiting symptoms has also been described [2]. To the unsuspecting eye, the lesion may appear like a tumor, in the stomach especially because of suboptimal vision due to pooled blood and clots. This may delay further investigation and therapy resulting in bowel loop strangulation and gangrene. The diagnosis is confirmed using ultrasonography or contrast-enhanced CT of the abdomen [1,3], and is classified based on

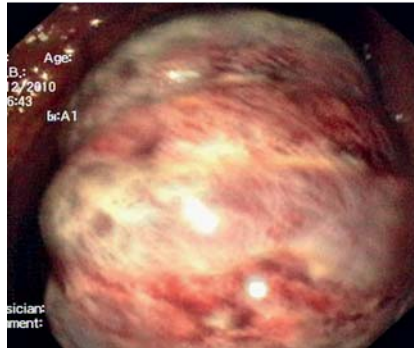


Fig. 1 Gastroscopy showing a large, congested mass in the stomach.

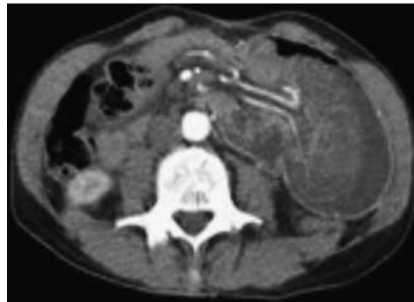

Fig. 2 Contrast-enhanced computed tomography (CT) scan showing telescoping of proximal small bowel and mesenteric vessels into the stomach.

the intussuscepting loop as type I (afferent loop), type II (efferent loop, most common type), and type III (combined) [4]. Endoscopic reduction has been described but emergency surgery is the definitive treatment. Surgery may involve bowel loop reduction or resection depending on its viability [5]. Awareness and prompt recognition is vital for minimizing morbidity and mortality.

Endoscopy_UCTN_Code_CCL_1AB_2AD_3AF

Competing interests: None

S. D. Chowdhury¹, A. K. Dutta¹, S. Pal¹, R. V. Leena², A. Chacko¹

¹ Department of GI Sciences, Christian Medical College, Vellore, Tamil Nadu, India

² Department of Radiology, Christian Medical College, Vellore, Tamil Nadu, India

References

- 1 Tokue H, Tsushima Y, Arai Y, Endo K. Jejunogastric intussusception: life-threatening complication occurring 55 years after gastrojejunostomy. *Intern Med* 2009; 48 (18): 1657–1660
- 2 Ertresvaag K, Haffner JF. Jejunogastric intussusception, an acute exacerbation diagnosed by gastroscopy. *Endoscopy* 1981; 13 (3): 131–133
- 3 Hashimoto Y, Akagi S, Sakashita Y et al. Usefulness of computed tomography as a preoperative diagnostic modality in a case with acute jejunogastric intussusception. *J Gastrointest Surg* 2007; 11 (8): 1078–1080
- 4 Shackman R. Jejunogastric intussusception. *Br J Surg* 1940; 27: 475–480
- 5 Jain BK, Lodh U, Chandra SS et al. Jejunogastric intussusception: therapeutic options. *Aust N Z J Surg* 1989; 59 (11): 865–868

Bibliography

DOI 10.1055/s-0030-1256601

Endoscopy 2011; 43: E247

© Georg Thieme Verlag KG Stuttgart · New York · ISSN 0013-726X

Corresponding author

Professor A. Chacko

Department of GI Sciences

Christian Medical College

Vellore

Tamil Nadu 632004

India

Fax: +91-416-2232035

gastro@cmcvellore.ac.in