

Fulminant Epstein–Barr virus esophagitis in an immunocompetent patient

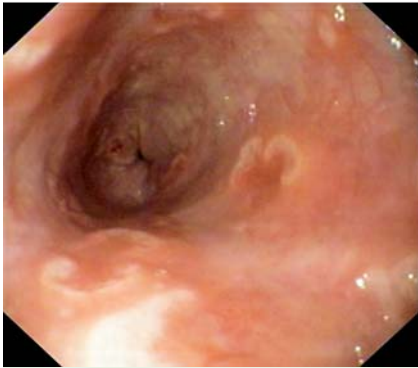


Fig. 1 Denuded ulcers in the esophagus of a 48-year-old man with a 3-week history of fever, nausea, and dysphagia.

A 48-year-old man presented to our hospital with a 3-week history of fever, nausea, and dysphagia. He had undergone bilateral femoral amputation 5 years ago

following an accident. Besides hypertension he had no other pathology. He lived with his family and was a smoker but did not take any drugs or alcohol. On examination, his skin was pale and there was slight epigastric tenderness. Initial laboratory tests revealed normocytic anemia. Abdominal ultrasound showed hepatosplenomegaly. The patient was admitted and upper endoscopy carried out, which revealed severe esophagitis with denuded ulcers (● Fig. 1).

Histological examination of the biopsy samples was noninformative, showing lymphocytic esophagitis with CD3 positive T-cells in the mucosa (● Fig. 2). Mononuclear cells were observed in the peripheral blood, but there was no evidence of a malignant hematological disorder. Blood, urinary, and esophageal cultures were negative for bacteria. The

patient was also negative for human immunodeficiency virus (HIV) antibody and antigen, HBSAg, and HCV antibody. Serological examinations suggested a previous herpes simplex virus (HSV) 1,2 and Epstein–Barr virus (EBV) infection, but real-time polymerase chain reaction (PCR) of a peripheral blood sample proved negative for these viruses. The patient was given intravenous proton-pump inhibitor therapy along with oral sucralfate suspension, but there was no clinical improvement after 1 week. Instead, he had an episode of hematemesis, and a repeat endoscopy showed increased ulceration in the esophagus (● Fig. 3).

Esophageal biopsies were taken for PCR, which was negative for cytomegalovirus and HSV, but highly positive for EBV (8040 copies/mL). Aciclovir therapy was initiated (5 × 800 mg) and continued for 2 weeks. After 1 month of this treatment, the esophagitis resolved completely, and was confirmed by endoscopy (● Fig. 4). EBV esophagitis is a rare pathological presentation that may occur in immunocompetent patients [1,2]. Our case highlights the importance of undertaking PCR on tis-

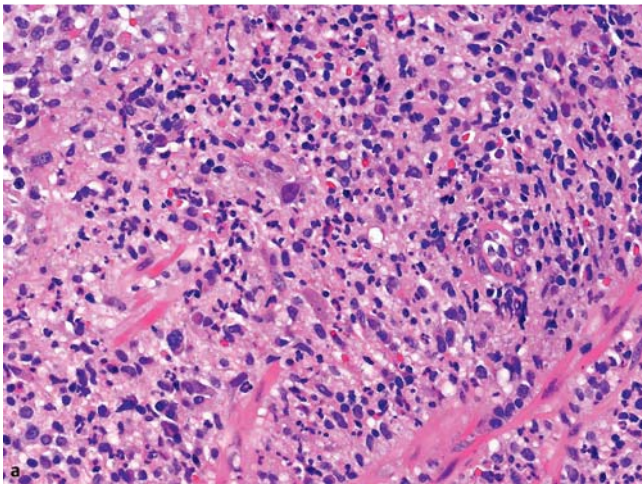


Fig. 2 Monocytyoid cells seen in the esophageal biopsy specimen (original magnification × 800). **b** Immunohistochemistry showing numerous CD3-positive lymphocytes both within and deep to the epithelium (original magnification × 400).

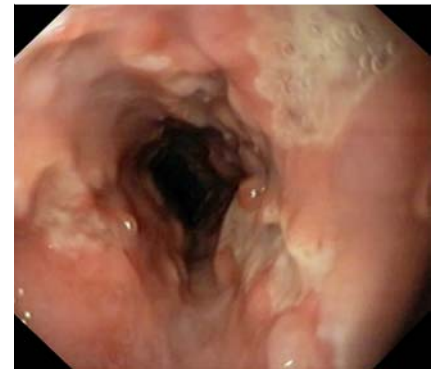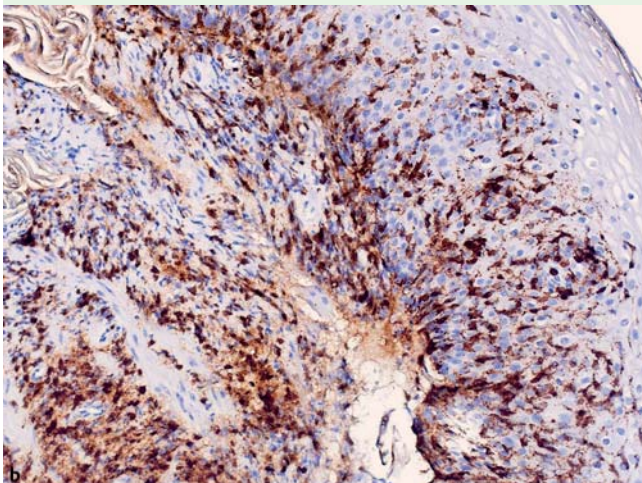


Fig. 3 Extensive ulceration of the esophagus after 1 week of nonspecific treatment.

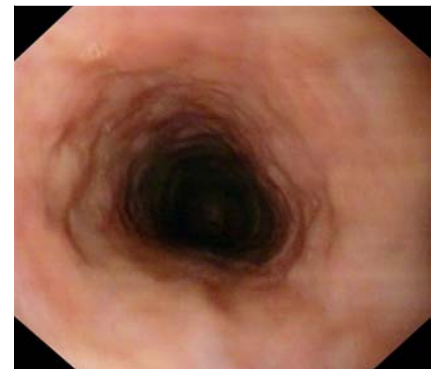


Fig. 4 Complete resolution after treatment with aciclovir.

sue biopsy samples, which in the present case was the only tool that led to the diagnosis, as the peripheral blood examination was negative for EBV.

Endoscopy_UCTN_Code_CCL_1AB_2AC_3AZ

Competing interests: None

**A. Annaházi¹, G. Terhes², J. Deák²,
L. Tizslavicz³, A. Rosztóczy¹,
T. Wittmann¹, R. Róka¹**

¹ First Department of Medicine, University of Szeged, Szeged, Hungary

² Institute of Clinical Microbiology, University of Szeged, Szeged, Hungary

³ Department of Pathology, University of Szeged, Szeged, Hungary

References

- 1 *Dekeyser S, El Nady M, Diaz E et al.* Diagnosis of herpetic esophagitis in the immunocompetent subject by PCR (Herpès Consensus Générique-Argène). Report of six cases [Article in French]. *Pathol Biol (Paris)* 2009; 57: 101–106
- 2 *Pape M, Mandravel K, Sidiropoulos I et al.* Unusual Epstein–Barr esophageal infection in an immunocompetent patient: a case report. *J Med Case Reports* 2009; 3: 7314

Bibliography

DOI 10.1055/s-0030-1256844

Endoscopy 2011; 43: E348–E349

© Georg Thieme Verlag KG Stuttgart · New York · ISSN 0013-726X

Corresponding author

A. Annaházi

First Department of Medicine

University of Szeged

Szeged

Korányi fasor 8-10, 6720

Hungary

Fax: +36-62-545210

annanita3@yahoo.com