

Laparoendoscopic mediastinal vacuum therapy of a gastric perforation through the diaphragm

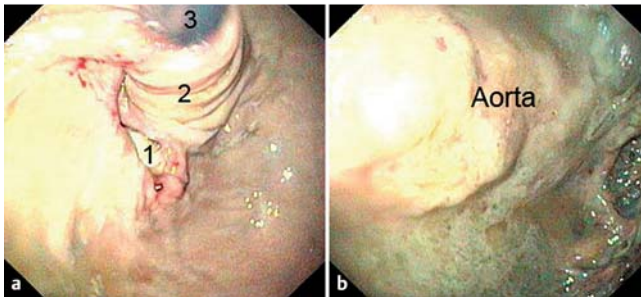


Fig. 1 Transhiatal perforation of the fundus. **a** Image showing: entry into the mediastinal necrosis cavity (1); fundoplication cuff (2); endoscope (3). **b** View into the necrosis cavity.

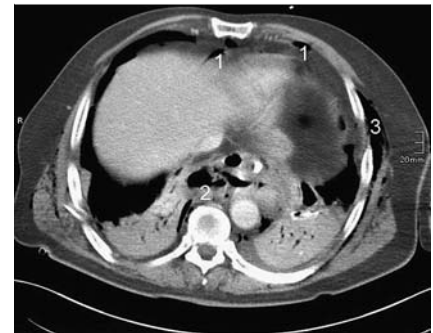

Fig. 2 Computed tomography (CT) scan showing air within the abdomen (1), air in the lower mediastinum (2), and subcutaneous emphysema (3).

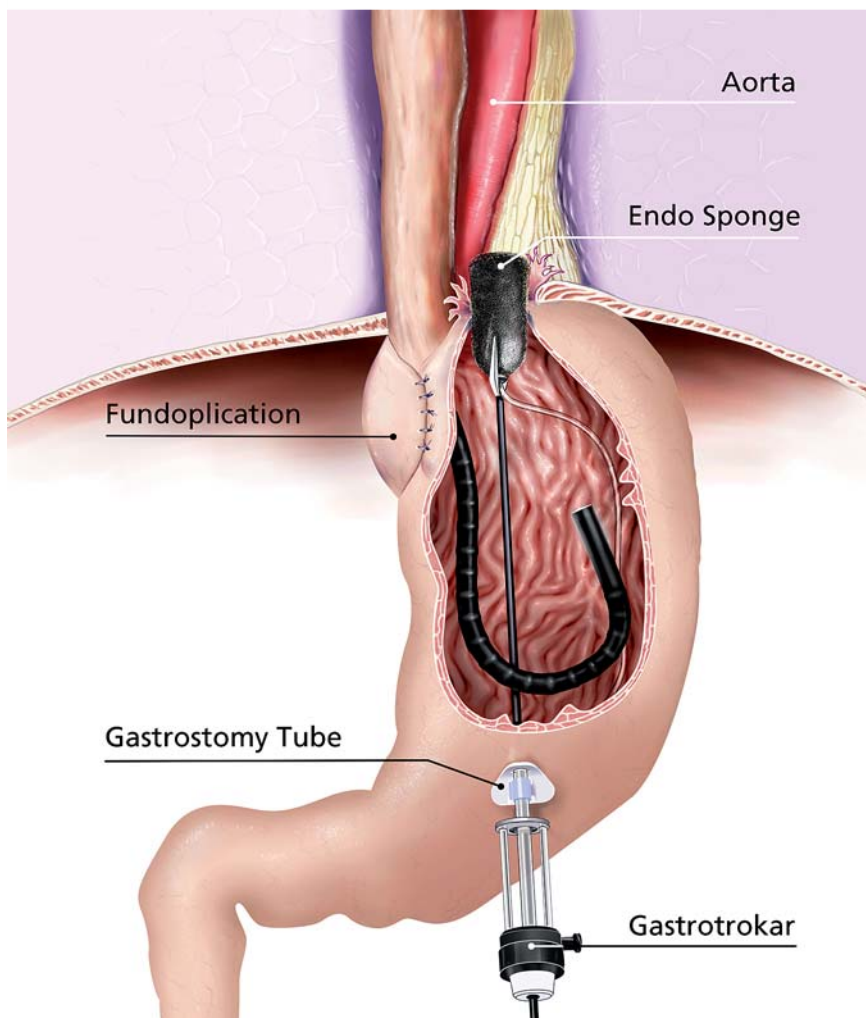


Fig. 3 The laparoendoscopic rendez-vous maneuver for placement of Endo-Sponge drainage of the mediastinal necrosis cavity (with the Gastrotrokar).

Endoscopically guided endoluminal vacuum therapy using polyurethane sponges has become an established method for treating rectal anastomotic leaks [1] and is now increasingly also used in the upper gastrointestinal tract [2–4]. We report on transhiatal placement of an Endo-Sponge

(Braun Medical, Melsungen, Germany) into the mediastinum using the Gastrotrokar described in an earlier paper [5]. A 54-year-old man was referred by the emergency doctor after a 2-day history of thoracolumbar pain on violent coughing. Immediate intubation was necessary be-

cause the patient presented a complete picture of sepsis. A laparoscopic fundoplication had been performed 6 years earlier due to gastroesophageal reflux disease. Gastroscopy revealed a satisfactory fundoplication. However, a transhiatal perforation of the fundus was observed (● Fig. 1). The necrosis cavity, which was located para-aortally in the mediastinum, was measured during computed tomography (CT) as 5.4 × 5 × 3.2 cm. Free intra-abdominal air and subcutaneous emphysema were found (● Fig. 2). Transesophageal endoscopic placement of an Endo-Sponge was not possible, because of the need for a maximally retroflexed scope position.

A Gastrotrokar (Storz, Tuttlingen, Germany) was introduced through a 20-Fr percutaneous endoscopic gastrostomy (PEG) tube (Fresenius Kabi AG, Bad Homburg, Germany) into the body of the stomach. The Endo-Sponge introduced transesophageally into the stomach using an overtube was then introduced easily into the cavity using a laparoscopic forceps (● Figs. 3 and 4). The Endo-Sponge tube was drained through the PEG tube and kept under continuous negative pressure of 125 mmHg using a negative pressure therapy system (KCI, USA Inc., San Antonio, Texas, USA). Broad-spectrum antibiotics (cefuroxime and metronidazol) were delivered.

After 48 h, the patient showed marked improvement both clinically and in laboratory test values. The patient was extubated. The Endo-Sponge was replaced on days 2 and 8, cleansing the wound and reducing the cavity by 50% (● Fig. 5), so

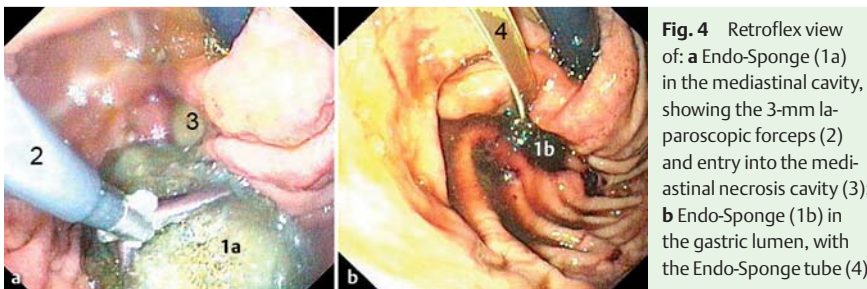


Fig. 4 Retroflex view of: **a** Endo-Sponge (1a) in the mediastinal cavity, showing the 3-mm laparoscopic forceps (2) and entry into the mediastinal necrosis cavity (3); **b** Endo-Sponge (1b) in the gastric lumen, with the Endo-Sponge tube (4).

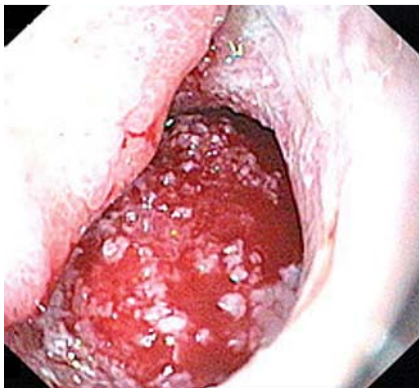


Fig. 5 The mediastinal cavity on day 8. The cavity is clean and has reduced in size by about 50%.

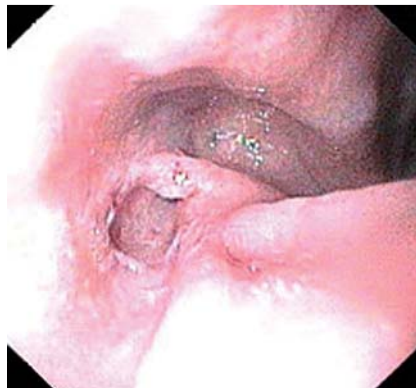

Fig. 6 The completely healed mediastinal cavity with formation of scar tissue, on day 21.

treatment was withdrawn on day 14. Complete reduction of the necrosis cavity was found on removal of the PEG tube after 21 days (► **Fig. 6**). Subsequently, the patient had no difficulty swallowing.

Endoscopy_UCTN_Code_TTT_1AO_2AD

Competing interests: None

A. Fischer, P. K. Baier, U. T. Hopt, H. J. Richter-Schrag
Surgical Endoscopy, Department of General and Visceral Surgery, Albert-Ludwigs University of Freiburg, Freiburg, Germany

References

- 1 Weidenhagen R, Gruetzner KU, Wiecken T et al. Endoscopic vacuum-assisted closure of anastomotic leakage following anterior resection of the rectum: a new method. *Surg Endosc* 2008; 22: 1818–1825
- 2 Loske G, Schorsch T, Muller C. Intraluminal and intracavitary vacuum therapy for esophageal leakage: a new endoscopic minimally invasive approach. *Endoscopy* 2011; 43: 540–544
- 3 Loske G, Schorsch T, Muller C. Endoscopic intracavitary vacuum therapy of Boerhaave's syndrome: a case report. *Endoscopy* 2010; 42: E144–E145
- 4 Ahrens M, Schulte T, Egberts J et al. Drainage of esophageal leakage using endoscopic vacuum therapy: a prospective pilot study. *Endoscopy* 2010; 42: 693–698
- 5 Fischer A, Schrag HJ, Keck T et al. Debridement and drainage of walled-off pancreatic necrosis by a novel laparoendoscopic rendezvous maneuver: experience with 6 cases. *Gastrointest Endosc* 2008; 67: 871–878

Bibliography

DOI 10.1055/s-0030-1256933

Endoscopy 2011; 43: E393–E394

© Georg Thieme Verlag KG Stuttgart · New York · ISSN 0013-726X

Corresponding author

A. Fischer, MD

Surgical Endoscopy
Department of General and Visceral Surgery
Albert-Ludwigs University of Freiburg
Hugstetter Straße 55
Freiburg 79106
Germany
Fax: +49-761-2702543
andreas.fischer@uniklinik-freiburg.de