

New endoscopic suturing device for closure of chronic gastrocutaneous fistula in an immuno-compromised patient

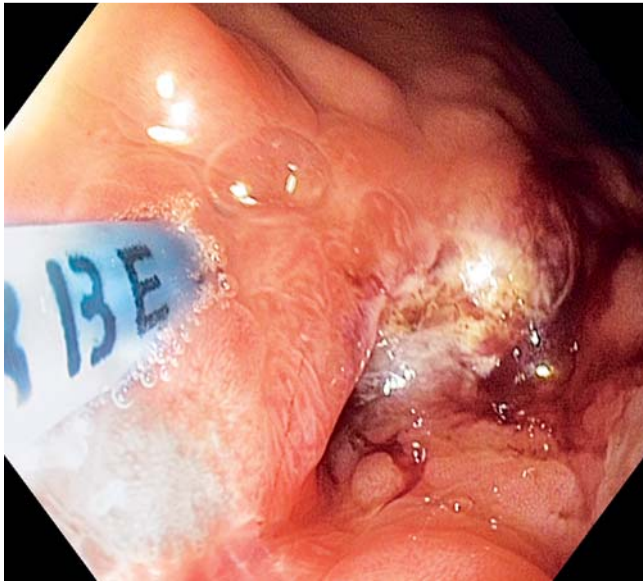

Fig. 1 The fistula track is treated with argon plasma coagulation.

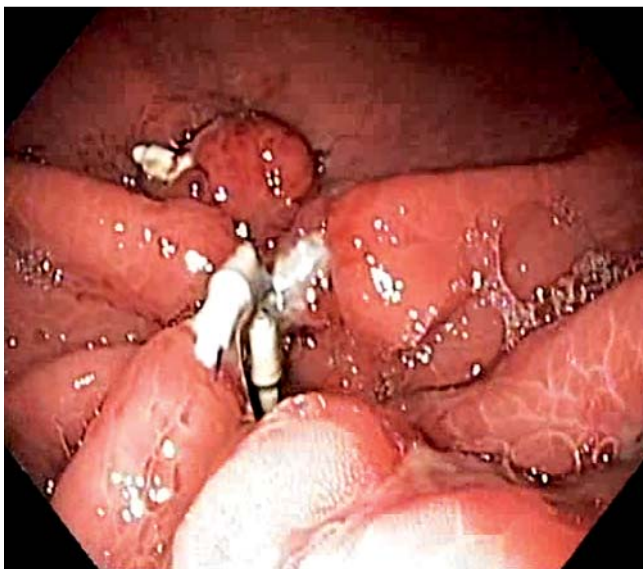


Fig. 3 Follow-up endoscopy demonstrating complete closure of the gastric fistula.

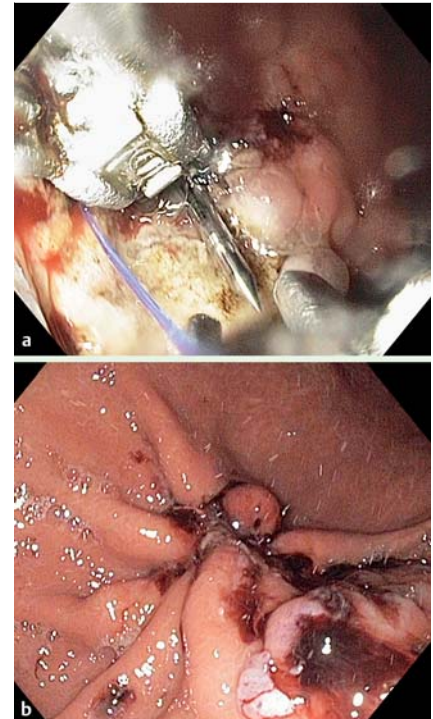


Fig. 2 **a** The Overstitch suturing device is introduced into the stomach. **b** Final view of the gastric wall after suturing is completed.

Video 1

The gastric opening of the fistula and the fistula tract are treated with argon plasma coagulation. The first stitch is made by driving the needle through one side of the fistula, returning the needle into the suturing arm, and then driving the needle through the opposite side of the fistula. The needle is released to become an anchor. The suture line is tightened and cinched, closing the fistula.

Video 2

A second needle is loaded into the Overstitch (without removing the suturing device from the stomach) then a continuous purse-string like suture is made, tightened, and cinched.

Video 3

A third needle is loaded into the Overstitch and the last reinforcing continuous suture is performed, completely closing the gastrocutaneous fistula.

A 46-year-old man with AIDS received a percutaneous endoscopic gastrostomy (PEG) tube in October 2009. His condition improved, and the PEG tube was removed in May 2010. Afterwards, the patient developed a persistent gastrocutaneous fistula at the site of the previous PEG. Multiple attempts to close the fistula with endoscopic clips, gastropexy, and an over-the-scope clip (Ovesco Endoscopy AG, Tübingen, Germany) failed. Upper endoscopy revealed a gastrocutaneous fistula 5 mm in diameter.

The fistula tract was treated with argon plasma coagulation (► **Fig. 1**), (ERBE Elektromedizin, Tübingen, Germany). Three stitches were then made with an Overstitch endoscopic suturing device (Apollo Endosurgery Inc., Austin, Texas, USA), completely closing the fistula (► **Fig. 2 a,b**; ► **Videos 1–3**). The leakage stopped after the procedure, and repeat endoscopy demonstrated good closure of the fistula (► **Fig. 3**). Management of patients with persistent gastrocutaneous fistulas can be very

difficult, especially in debilitated, immunocompromised patients. Multiple devices and techniques have been used in the past with only limited success [1–5]. Our patient was not a good surgical candidate because of his underlying illness. In this situation we decided to use the newly developed Overstitch suturing device. The Overstitch is frontloaded to a double-channel endoscope and then introduced into the stomach. The device utilizes a needle with an attached suture, which can be reloaded into the suturing device inside the stomach an unlimited number of times. It also uses intracorporeal knot cinching without the need to remove the suturing device from the stomach. The Overstitch device allows tissue defects of various sizes to be closed with continuous or separate sutures. The tightness of the suture is regulated by the physician performing the procedure.

In conclusion, this is the first report of successful clinical use of the new Overstitch endoscopic suturing device in Europe. Overstitch is simple to assemble, easy to work with, and can potentially be used for a variety of procedures requiring suturing inside the gastrointestinal tract.

Acknowledgement



The authors would like to acknowledge Apollo Endosurgery Inc (Austin, Texas, USA) for providing the Overstitch suturing device free of charge for treatment of this patient. The authors would also like to thank the W.I.D.E.R. institute (Barcelona, Spain) for arranging the necessary collaboration to perform this case study.

Endoscopy_UCTN_Code_TTT_1AO_2AI

Competing interests: Dr. Kantsevoy is a share holder of Apollo Endosurgery Inc.

**J. R. Armengol-Miro^{1,2}, J. Dot^{1,2},
M. Abu-Suboh Abadia^{1,2}, M. Masachs^{1,2},
J. C. Salord^{1,2}, J. Armengol Bertroli^{1,2},
A. Benages^{1,2}, S. V. Kantsevoy^{2,3}**

¹ Vall d'Hebron University Hospital, Barcelona, Spain

² World Institute for Digestive Endoscopy Research (W.I.D.E.R.), Barcelona, Spain

³ Institute for Digestive Health and Liver Diseases, Mercy Medical Center, Baltimore, Maryland, USA

References

- 1 Conio M, Bianchi S, Repici A *et al.* Use of an over-the-scope clip for endoscopic sealing of a gastric fistula after sleeve gastrectomy. *Endoscopy* 2010; 42: 71–72
- 2 Alberti-Flor JJ. Percutaneous-endoscopic suturing of gastrocutaneous fistula: report of 2 cases. *Gastrointest Endosc* 2002; 56: 751–753
- 3 Eskaros S, Ghevariya V, Krishnaiah M *et al.* Percutaneous endoscopic suturing: an effective treatment for gastrocutaneous fistula. *Gastrointest Endosc* 2009; 70: 768–771
- 4 von Renteln D, Denzer UW, Schachschal G *et al.* Endoscopic closure of GI fistulae by using an over-the-scope clip (with videos). *Gastrointest Endosc* 2010; 72: 1289–1296
- 5 Albert JG, Friedrich-Rust M, Woeste G *et al.* Benefit of a clipping device in use in intestinal bleeding and intestinal leakage. *Gastrointest Endosc* 2011; 74: 389–397

Bibliography

DOI 10.1055/s-0030-1257039

Endoscopy 2011; 43: E403–E404

© Georg Thieme Verlag KG Stuttgart · New York · ISSN 0013-726X

Corresponding author

S. V. Kantsevoy, MD, PhD

Institute for Digestive Health and Liver Diseases
Mercy Medical Center
Suite 718, POB 7th floor
301 St Paul Place
Baltimore
Maryland 21202
USA
Fax: 410-659-1162
skan51@hotmail.com