

Fatal retroperitoneal gas gangrene complicating colonoscopic polypectomy without bowel perforation in a healthy adult

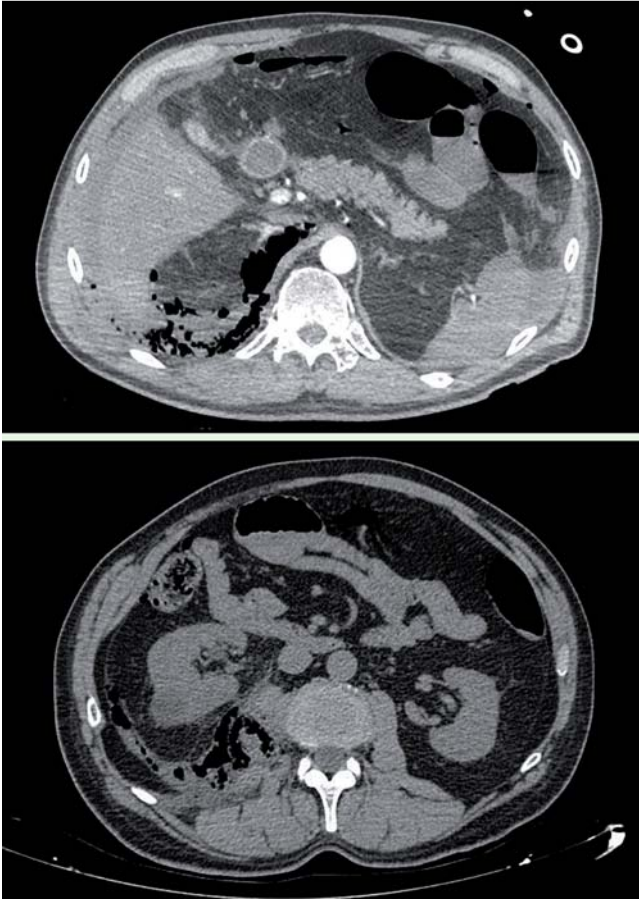


Fig. 1 Abdominal computed tomography (CT) scan images in a previously healthy adult post-polypectomy showing a retroperitoneum, with the emphysema also involving the right psoas muscle.

Colonoscopy is a commonly performed procedure that is rarely associated with severe complications, especially not life-threatening infections [1–3]. We report a fatal outcome caused by *Clostridium perfringens* after colonoscopic polypectomy in a 58-year-old healthy adult. The colonoscopy was performed as part of a public health screening program for colorectal cancer studying fecal occult blood, and during the procedure four polyps were removed.

The patient was readmitted 12 hours after the colonoscopy complaining of severe back and right-sided abdominal pain. Physical examination was normal except for abdominal tenderness. A computed

tomography (CT) scan revealed the presence of extensive retroperitoneal gas, which was also involving the right psoas muscle (▶ Fig. 1). A bowel perforation was suspected, so an urgent laparotomy was indicated. Surgical exploration revealed extensive retroperitoneal emphysema with a parietocolic hematoma, but no evidence of a macroscopic bowel perforation. The hematoma was drained and microbiological samples were collected. Antibiotic treatment with imipenem was started.

In the immediate postoperative period the patient developed hemolysis, and severe respiratory and renal failure. A further CT scan revealed worsening of the

retropneumoperitoneum, which was also dissecting muscle planes in the right leg and scrotum. The emphysema also extended into the thorax. Staining of the previously removed tissue showed Gram-positive bacilli, indicating possible gas gangrene infection. A second laparotomy with extensive retroperitoneal debridement was performed but, despite resuscitation efforts, the patient died 36 hours after admission.

Post-mortem cultures were positive for *C. perfringens*. An autopsy showed massive intra-abdominal bleeding, with destruction and liquefaction of the retroperitoneal muscles. No macroscopic bowel perforation was found. Histological examination of the polyps did not identify a malignancy.

Gas gangrene is a soft-tissue infection caused by *Clostridium* spp. [4,5]. A defining diagnostic feature is gas dissecting into the muscle bellies, and CT scanning is especially useful to diagnose this in an intra-abdominal location [6]. A literature review identified one other case of retroperitoneal gas gangrene associated with colonoscopic polypectomy [7]. Therefore, although CT scan images showing retroperitoneal gas after a colonoscopy have been associated with colonic perforation [8,9], gas gangrene should also be considered in the differential diagnosis, especially after polypectomy and when the gas involves the muscle belly.

Endoscopy_UCTN_Code_CPL_1AJ_2AC

Competing interests: None

Evelyn Shaw¹, Raquel Reyes², Antonia Bonet², Lucia Garcia-Huete², Alberto Pasqualetto², Fe Tubau³, Jordi Carratalà¹

¹ Department of Infectious Diseases, Hospital Universitari de Bellvitge, Barcelona, Spain and Spanish Network for Research in Infectious Diseases (REIPI RD12/0015), Instituto de Salud Carlos III, Madrid, Spain

² Department of Anesthesia, Hospital Universitari de Bellvitge, Barcelona, Spain

³ Department of Microbiology, Hospital Universitari de Bellvitge, Barcelona, Spain and CIBERES (CIBER de Enfermedades Respiratorias), Instituto de Salud Carlos III, Madrid, Spain

References

- 1 Fisher DA, Maple JT. ASGE Standards of Practice Committee et al. Complications of colonoscopy. *Gastrointest Endosc* 2011; 74: 745–752
- 2 Warren JL, Klabunde CN, Mariotto AB et al. Adverse events after outpatient colonoscopy in the Medicare population. *Ann Intern Med* 2009; 150: 849–857
- 3 Nelson DB. Infectious disease complications of GI endoscopy: part I, endogenous infections. *Gastrointest Endosc* 2003; 57: 546–556
- 4 Stevens DL, Bisno AL, Chambers HF et al. Practice guidelines for the diagnosis and management of skin and soft-tissue infections. *Clin Infect Dis* 2005; 41: 1373–1406
- 5 Stevens DL, Aldape MJ, Bryant AE. Life-threatening Clostridial infections. Pathogenesis and toxins. *Anaerobe* 2012; 18: 254–259
- 6 Chapnick EK, Abter EI. Necrotizing soft-tissue infections. *Infect Dis Clin North Am* 1996; 10: 835–855
- 7 Boenicke L, Maier M, Merger M et al. Retroperitoneal gas gangrene after colonoscopic polypectomy without bowel perforation in an otherwise healthy individual: report of a case. *Langenbecks Arch Surg* 2006; 391: 157–160
- 8 Bakker J, van Kersen F, Bellaar Spruyt J. Pneumopericardium and pneumomediastinum after polypectomy. *Endoscopy* 1991; 23: 46–47
- 9 Daniels IR, Sullivan T, Hale J. Retroperitoneal gas after colonoscopy. *J R Soc Med* 1999; 92: 21–22

Bibliography

DOI <http://dx.doi.org/10.1055/s-0033-1344990>
Endoscopy 2014; 46: E91–E92
© Georg Thieme Verlag KG
Stuttgart · New York
ISSN 0013-726X

Corresponding author

Evelyn Shaw, MD
Department of Infectious Diseases
Hospital Universitari de Bellvitge
Feixa Llarga s/n
L'Hospitalet de Llobregat 08907
Barcelona
Spain
Fax: +34-93-2607274
eshawp@gmail.com