

Late presentation of capsule endoscope aspiration with successful extraction by flexible bronchoscopy utilizing a snare wire loop

Table 1 Demographic and clinical data of the patients with well-documented aspiration of a capsule endoscope.

Age, mean, years	79
Male/Female, n	15/1
Total number	16
Co-morbid risk factors for aspiration, n	5
Dysphagia, n	3
Symptoms/signs, n	
Cough	12
Shortness of breath	2
Throat pain	1
Tachypnea	1
Gagging	1
Wheeze	1
Asymptomatic	2
Length of aspiration, n	
≤5 minutes	7
<24 hours	4
>24 hours	2
Not provided	3
Method of diagnosis, n	
Recording download	12
Radiographs	4
Spontaneously coughed out, n	9
Removed by flexible fiberoptic bronchoscopy, n	5
Removed by rigid bronchoscope, n	2

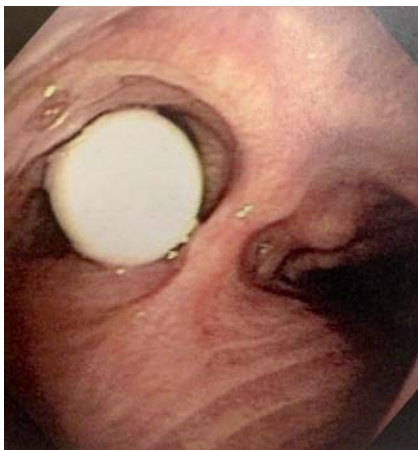

Fig. 2 The capsule endoscope was identified in the left main stem bronchus by fiberoptic bronchoscopy.

Capsule endoscopy is a commonly employed technique to examine patients for gastrointestinal pathology. Pulmonary aspiration of a capsule endoscope is a rare complication of this procedure. There have been 15 well-described instances of

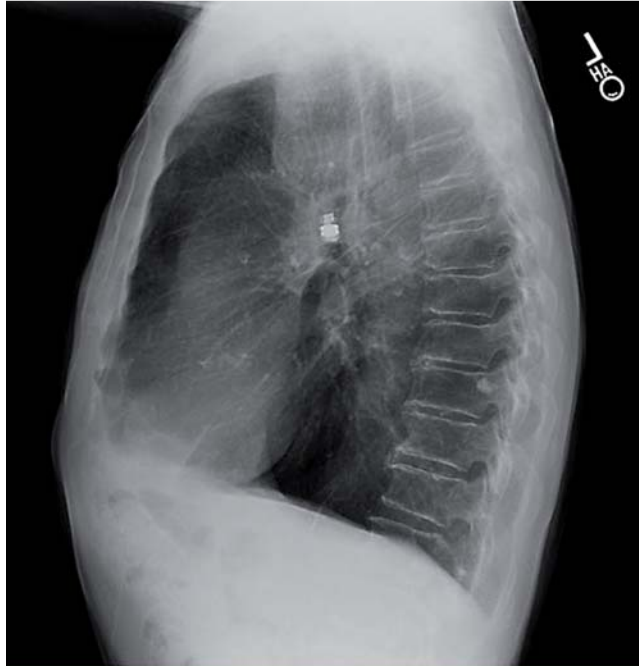
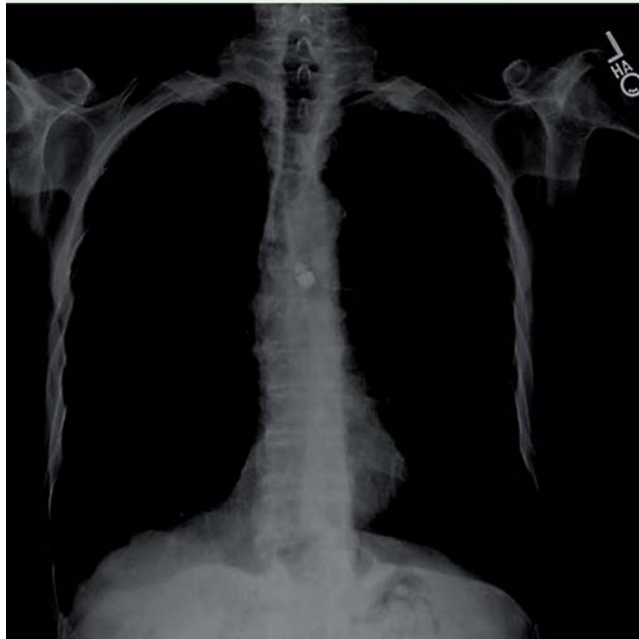

Fig. 1 Chest radiograph demonstrating the capsule endoscope in the left main bronchus.



bronchial aspiration of a capsule endoscope [1–15].

Patients who aspirate this device are generally elderly and may have risk factors for aspiration. Aspiration should be suspected if cough occurs when the patient is swallowing the capsule. Aspiration can be confirmed by chest radiography or by immediate downloading of the recorded

images. Fortunately, most patients are able to cough up the capsule endoscope and swallow it without intervention and do so in a short time frame. However, an invasive intervention may be required to remove the aspirated capsule from the bronchial tree. The technique employed to retrieve the device depends on the expertise of the local physicians and equip-

ment availability (Table 1). Interestingly, a capsule endoscope can remain in the bronchial tree for an extended time period without significant complication to the patient.

We present a case where the capsule endoscope remained in the bronchial tree of an 81-year-old man for 110 days without serious consequences. He manifested the aspiration with a cough only at the initial swallowing of the device. Other than his age he had no risk factor for aspiration. The initial interpretation of the capsule video recording was that the capsule had remained in his esophagus for the 8 hours of recording. However, when the capsule endoscope was identified on chest radiographs (Fig. 1) and the video recording was reviewed, it was determined that the images had been misinterpreted. Not surprisingly, the images actually demonstrated that the device had remained in the patient's bronchus for the entire recording. The capsule was successfully retrieved from his left main stem bronchus (Fig. 2) using a flexible fiberoptic bronchoscope and a snare wire loop.

Endoscopy_UCTN_Code_CPL_1AI_2AB

Competing interests: None

Mahmoud Amarna¹, Amanda Vanlandingham², Parag Brahmhatt², Thomas M. Roy^{1,2,3}, Ryland P. Byrd^{1,2,3}

¹ Division of Pulmonary Diseases and Critical Care Medicine, East Tennessee State University, Johnson City, Tennessee, United States

² Department of Internal Medicine, The James H. Quillen VAMC, Mountain Home, Tennessee, United States

³ Department of Pulmonary Diseases and Critical Care, The James H. Quillen VAMC, Mountain Home, Tennessee, United States

References

- 1 Sepehr A, Albers GC, Armstrong WB. Aspiration of a capsule endoscope and description of a unique retrieval technique. *Otolaryngology* 2007; 137: 965–966
- 2 Nathan S, Biernat L. Aspiration – an important complication of small-bowel video capsule endoscopy. *Endoscopy* 2007; 39: E343
- 3 Tabib S, Fuller C, Daniels J et al. Asymptomatic aspiration of a capsule endoscope. *Gastrointest Endosc* 2004; 60: 845–848
- 4 Depriest K, Wahla A, Blair R et al. Capsule endoscopy removal through flexible bronchoscopy. *Respiration* 2010; 79: 421–424
- 5 Lucendo A, González-Castillo S, Fernández-Fuente M et al. Tracheal aspiration of a capsule endoscope: a new case report and literature compilation of an increasingly reported complication. *Dig Dis Sci* 2011; 56: 2758–2762
- 6 Parker C, Davison C, Panter S. Tracheal aspiration of a capsule endoscope: not always a benign event. *Dig Dis Sci* 2012; 57: 1727–1728
- 7 Pezzoli A, Fusetti N, Carella A et al. Asymptomatic bronchial aspiration and prolonged retention of a capsule endoscope: a case report. *J Med Case Rep* 2011; 5: 341
- 8 Guy T, Jouneau S, D'Halluin P et al. Asymptomatic bronchial aspiration of a video cap-

sule. *Interact Cardiovasc Thorac Surg* 2009; 8: 568–570

- 9 Choi H, Kim J, Kim H et al. A case of asymptomatic aspiration of a capsule endoscope with a successful resolution. *Gut Liver* 2010; 4: 114–116
- 10 Schneider A, Hoepffner N, Rösch W et al. Aspiration of an M2A capsule. *Endoscopy* 2003; 35: 713
- 11 Girdhar A, Usman F, Bajwa A. Aspiration of capsule endoscope and successful bronchoscopic extraction. *J Bronchology Interv Pulmonol* 2012; 19: 328–331
- 12 Shiff AD, Leighton JA, Heigh RI et al. Pulmonary aspiration of capsule endoscope. *Am J Gastroenterol* 2007; 102: 215–216
- 13 Bredenoord AJ. Unintentional video capsule bronchoscopy. *Eur J Gastroenterol Hepatol* 2009; 21: 593–594
- 14 Sinn I, Neef B, Andus T. Aspiration of a capsule endoscope. *Gastrointest Endosc* 2004; 59: 926–927
- 15 Leeds J, Chew TS, Sidhu R et al. Asymptomatic bronchial aspiration and retention of a capsule endoscope. *Gastrointest Endosc* 2009; 69: 561

Bibliography

DOI <http://dx.doi.org/10.1055/s-0034-1377543>
Endoscopy 2015; 47: E6–E7
 © Georg Thieme Verlag KG
 Stuttgart · New York
 ISSN 0013-726X

Corresponding author

Ryland P. Byrd, Jr., MD
 Veterans Affairs Medical Center 111-B
 Division of Pulmonary Diseases
 and Critical Care Medicine
 PO Box 4000
 Mountain Home
 TN 37684-4000
 USA
 Fax: +1-423-979-3471
 Ryland.Byrd@med.va.gov