

A Rare Case of Dacron Graft Rupture due to Friction against a Rib

Katsuhiko Matsuyama¹ Masahiko Kuinose¹ Nobusato Koizumi¹ Toru Iwahashi¹ Kayo Toguchi¹
Hitoshi Ogino¹

¹Department of Cardiovascular Surgery, Tokyo Medical University Hospital, Tokyo, Japan

Address for correspondence Katsuhiko Matsuyama, MD, Department of Cardiovascular Surgery, Tokyo Medical University, 6-7-1 Nishishinjuku Shinjuku-ku, Tokyo 160-0023, Japan (e-mail: spgfs112@yahoo.co.jp).

Thorac Cardiovasc Surg Rep 2014;3:71–72.

Abstract

A 54-year-old man underwent aortic repair for the infected thoracoabdominal aneurysm with a woven Dacron graft (Vascutek, Renfrewshire, Scotland) treated with gentian violet. Four months later, he complained of sudden back pain, resulting in preshock status. Computed tomographic scans showed massive hematoma around the Dacron graft, suggesting graft rupture. Initially, emergency thoracic endovascular aortic repair was performed, which was subsequently followed by open repair. The Dacron graft had a small hole, which was completely compatible with the site contacting with the rib. The graft rupture was considered due to its friction against the rib. We report on a rare event of mechanical Dacron graft rupture after the thoracoabdominal aortic replacement.

Keywords

- ▶ graft rupture
- ▶ rib
- ▶ friction

Case

A 54-year-old man had undergone combined esophagectomy and graft replacement of the descending aorta for aorto-esophageal fistula, due to a chronic erosion of a large descending aortic aneurysm and the esophagus 1 year ago. Although he had been doing well, the extent III thoracoabdominal aorta progressively dilated, complicated with infection. He had urgent thoracoabdominal aortic repair with a Gelweave woven Dacron multibranched graft (Vascutek, Renfrewshire, Scotland) treated with gentian violet. Postoperative computed tomographic (CT) scans showed no recurrence of the infection, with the graft located close to the 10th rib (▶ Fig. 1). Four months later, he presented with sudden back pain and was referred to our hospital. On admission, he was in preshock status, and laboratory data revealed hemoglobin levels of 5.2 mg/dL. CT scans demonstrated active contrast extravasation and a massive hematoma around the graft, suggesting graft rupture (▶ Fig. 2). Emergency thoracic endovascular aortic repair (TEVAR) as a bridge use was successfully performed for the hemostasis, and subsequently stable hemodynamics were obtained. Open repair was subsequently performed. Operative findings after the removal of

the massive hematoma showed that there was no bleeding proximally or distally to the previous anastomosis. However, there was an oozing type of bleeding from a small hole in the previous Dacron. The small hole was located completely compatible with the site in contact with the 10th rib, which lacked periosteum (▶ Fig. 3). The margin of the hole was dull. The Dacron graft rupture was considered due to its friction against the rib. The hole was directly closed with 4–0 Prolene (Ethicon, Somerville, New Jersey, United States). In addition, the graft was wrapped with another Gelweave Dacron prosthesis, and positioned apart from the chest wall to prevent another mechanical graft injury. Intraoperative cultures taken at the time of surgical exploration of the disrupted graft showed all negative. The postoperative course was uneventful, and the patient was discharged after a hospital stay of 10 days. He is doing well 2 years after surgery.

Discussion

Dacron prostheses, which are the most widely used grafts in replacement procedures, have been proven as the most durable and reliable substitutes for vascular replacement in aortic surgery. Although nonanastomotic rupture caused

received
April 1, 2014
accepted after revision
May 6, 2014
published online
July 16, 2014

DOI <http://dx.doi.org/10.1055/s-0034-1383827>.
ISSN 2194-7635.

© 2014 Georg Thieme Verlag KG
Stuttgart · New York

License terms



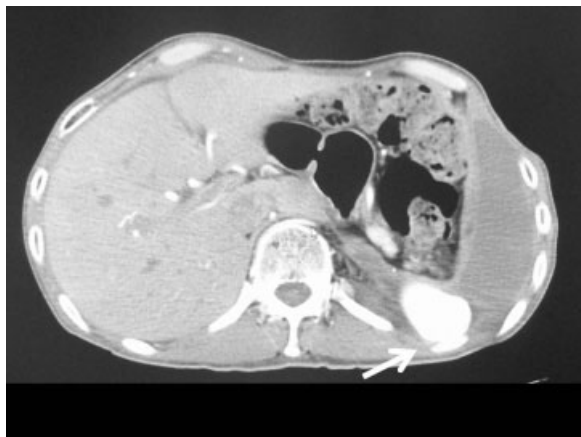


Fig. 1 A postoperative computed tomographic scan after thoracic endovascular aortic repair showing that the graft was closely positioned in contact with the rib (arrow).

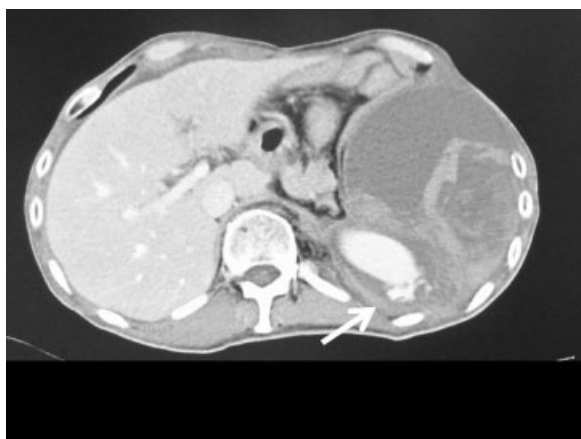

Fig. 2 A computed tomographic scan demonstrating active contrast extravasation (arrow) and a massive hematoma around the graft.

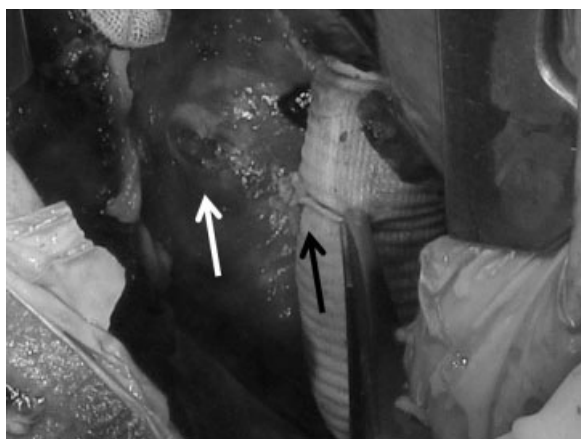

Fig. 3 Operative findings. The black arrow shows the repaired rupture site of the graft. The white arrow shows the rib without periosteum.

by intrinsic factors such as degeneration of graft fibers has been reported previously,¹ graft rupture due to extrinsic damage caused by mechanical stress is rare. To the best of our knowledge, only three recent reports have shown Dacron prosthetic ruptures caused by direct damage, such as contact with the rib stump or aortic calcification.²⁻⁴ However, there have been no reports of graft rupture due to contact with the smooth surface of the rib. In the present case, during the previous repair, the coverage of the Dacron graft with aneurysmal sac to prevent this complication could not be applied because the major part of infected aortic wall was removed. Alternatively, xenopericardial neoaortas or homografts were not routinely available in our country. The Dacron graft was placed slightly more laterally, away from the infected bed. Subsequently, the graft was positioned close to the rib. Repeated graft pulsation may have resulted in gradual damage by friction against the rib surface, resulting in injury of the graft. In particular, Gelweave woven Dacron prostheses have a thin wall, which may be related to the rupture. To avoid such complications, the graft should be positioned away from the ribs or aortic calcification.

With regard to the treatment for such a rare complication, endovascular repairs are quicker and easier. Open repairs need some time for body positioning, thoracotomy, and cardiopulmonary bypass, although they are more durable than endovascular repairs. Consequently, we employed two-stage repairs with bridge use of a stent graft. In the second stage, simple wrapping of the Dacron graft with another Dacron prosthesis with direct closure of the graft injury was chosen because it was easier and did not require a cardiopulmonary bypass.

Disclosure

We have no financial or other interest in the manufacture or distribution of the device.

References

- 1 Nunn DB, Pourdeyhimi B. Intrinsic Dacron graft failure 19 years post-implantation. *Cardiovasc Surg* 1997;5(3):333-338
- 2 Tanaka H, Okada K, Yamashita T, Kawanishi Y, Matsumori M, Okita Y. Disruption of the vascular prosthesis caused by aortic calcification after replacement of the thoracoabdominal aortic aneurysm. *Ann Thorac Surg* 2006;82(3):1097-1099
- 3 Yamamoto H, Yamamoto F, Ishibashi K, Noishiki Y. Vascular prosthesis rupture caused by contact with rib stump after thoracic aorta replacement. *J Vasc Surg* 2009;50(1):195-197
- 4 Ozaki N, Wakita N, Tanaka Y, Yuji D. The life-threatening complication of a vascular graft rupture early after a thoracic aortic replacement. *Eur J Cardiothorac Surg* 2012;42(4):737-738