

Cold snare piecemeal resection of colonic and duodenal polyps ≥ 1 cm

Authors

Neel Choksi¹, B. Joseph Elmunzer², Ryan W. Stidham¹, Dmitry Shuster¹, Cyrus Piraka³

Institutions

¹ Division of Gastroenterology, University of Michigan Hospital and Health Systems, Ann Arbor, MI, USA

² Division of Gastroenterology, Medical University of South Carolina, Charleston, SC, USA

³ Division of Gastroenterology, Henry Ford Hospital, Detroit, MI, USA

submitted

26. November 2014

accepted after revision

13. April 2015

Bibliography

DOI <http://dx.doi.org/>

10.1055/s-0034-1392214

Published online: 24.6.2015

Endosc Int Open 2015; 03:

E508–E513

© Georg Thieme Verlag KG

Stuttgart · New York

E-ISSN 2196-9736

Corresponding author

Cyrus Piraka, MD

Division of Gastroenterology

Henry Ford Hospital

2799 West Grand Boulevard

Detroit

MI 48202

USA

cpiraka@gmail.com

Background: Endoscopic removal of duodenal and colorectal adenomas is currently considered to be the standard of care for prevention of adenocarcinoma. The use of cautery carries a risk of delayed bleeding, post-polypectomy syndrome, and perforation. We examined the safety and feasibility of removing colonic and duodenal polyps ≥ 1 cm using a piecemeal cold snare polypectomy technique.

Patients: The study included 15 patients with duodenal polyps ≥ 1 cm and 15 patients with colonic polyps ≥ 1 cm.

Main outcome measurements: Bleeding, perforation, abdominal pain, or hospitalization occurring within 2 weeks of polypectomy.

Results: Between 24 August 2011 and 29 April 2013, 15 patients had removal of duodenal polyps ≥ 1 cm. Mean patient age was 64 years and 9/15 patients were male. The mean polyp size was 24 mm (10–60 mm). All polyps were removed with a cold snare and some required cold biopsy forceps. One patient required hospitaliza-

tion for gastrointestinal blood loss 7 days post-polypectomy; this patient was using Coumadin. Between 27 February 2012 and 30 May 2013, 15 patients underwent resection of a ≥ 1 cm colonic polyp. Mean patient age was 68 years and 9/15 were male. The mean polyp size was 20 mm (10–45 mm). All polyps were primarily removed with a cold snare. None of the patients required hemostatic clips for control of immediate bleeding. One patient presented to the emergency department with abdominal pain 1 day after initial endoscopy. CT scan showed no abnormalities and the patient was discharged.

Conclusions: Cold snare polypectomy for large duodenal and colonic polyps is technically feasible and may have a favorable safety profile compared to standard electrocautery-based endoscopic resection. Comparative trials are required to determine the relative safety and efficacy of cold snare techniques for complete and durable resection of large polyps compared to standard hot snare methods.

Introduction

The use of electrocautery during polypectomy is widely considered to be the standard of care in resecting polyps ≥ 10 mm. In practice, “hot” polypectomy can aid in both transecting tissue and preventing immediate bleeding through coagulation of small arterial and venous branches [1]. Electrocautery also allows for the en bloc resection of larger polyps, believed to reduce the risk of recurrent adenoma.

The use of electrosurgical current during endoscopic resection, however, may be suboptimal from a safety standpoint. For example, conventional “hot” polypectomy carries a risk of delayed bleeding [2], possibly due to sloughing of coagulum to expose an incompletely coagulated submucosal artery. In addition, cautery-related transmural thermal injury to the bowel wall is a

major contributor to procedural adverse events [3], manifesting in a spectrum of severity from post-polypectomy pain syndrome, to unrecognized perforation at the time of endoscopy, to frank perforation related to transection through the muscularis propria and serosa layers. While electrocautery-aided en bloc resection theoretically may be a more effective strategy for complete resection of all polyp tissue, more than one study has shown local adenoma recurrence at a rate of up to 28% despite this technique [4,5].

Cold snare polypectomy, in contrast, has been widely favored for the resection of smaller polyps since the avoidance of electrocautery clearly reduces post-polypectomy electrocoagulation syndrome, perforation, and delayed bleeding. Despite these benefits, cold snare polypectomy for the resection of larger duodenal and colonic polyps has not been explored previously. We hypothesized

License terms



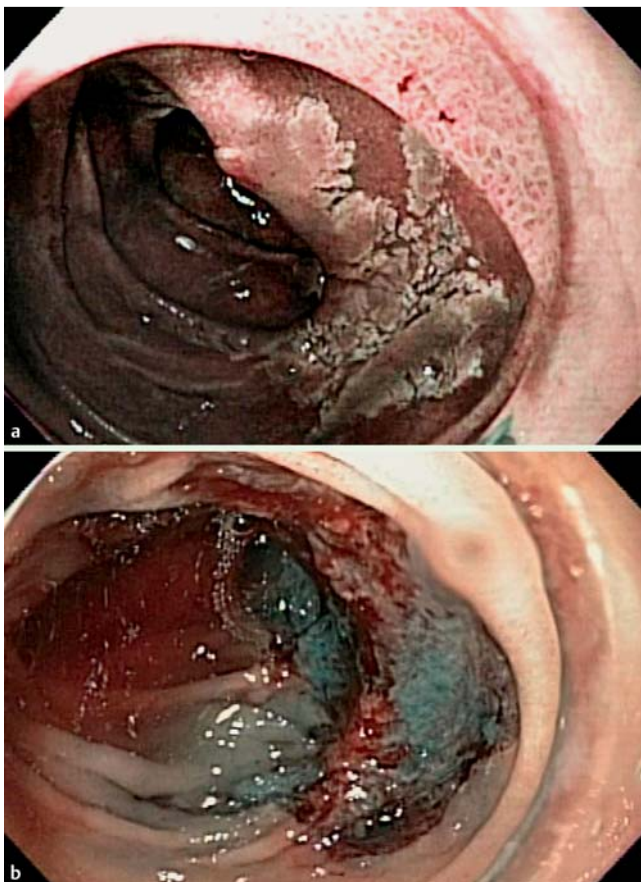


Fig. 1 a Before cold snare piecemeal resection of a large duodenal polyp. b After cold snare piecemeal resection of a large duodenal polyp.

that endoscopic resection using a cold snare piecemeal technique is feasible for larger polyps. To evaluate our hypothesis, in this first proof-of-principle case series, we assessed the technical feasibility and preliminary safety of cold snare polypectomy for larger duodenal and colonic polyps.

Methods

This study was approved by the institutional review board of The University of Michigan Hospital and Health Systems (UMHS). A retrospective review was conducted of all patients who underwent polypectomy of a ≥ 10 mm adenoma from the duodenum or colon through a single endoscopist (CP) over a 16-month period from February 2012 to May 2013. The size, polyp location, morphology, resection technique, and all adjunct therapies were recorded at the time of the procedure using ProVation MD electronic documentation (Provation Medical, Minneapolis, MN, United States). All procedures were performed in the Medical Procedures Unit at UMHS with anesthesia support personnel. Procedures were performed using Olympus equipment (Olympus America, Center Valley, PA, United States) including a standard adult colonoscope, a pediatric colonoscope, a single-channel gastroscope, or a double-channel therapeutic gastroscope. Polyps were resected by cold snare. Several snare manufacturers were used, including Exacto snare (US Endoscopy, Mentor, OH, United States), Mini snare (Cook Medical Inc., Bloomington, IN, United States), or Hexagonal snare (Cook Medical Inc.).

If en bloc resection was not feasible, the polyp was removed in a piecemeal fashion. Cold biopsy forceps were used to aid in resecting smaller pieces of residual polyp at the base and edge of the polypectomy site. Before polypectomy, nearly all patients underwent a submucosal injection of 1:60 000 epinephrine in saline with Methylene Blue for the purpose of lifting the polyp. In some cases, a short, clear, plastic Olympus cap at the tip of the scope was used to aid with resection. Patients did not undergo any form of thermal therapy including the use of “hot” forceps or argon plasma coagulation (APC). Hemostatic clips were used at the discretion of the endoscopist to treat immediate bleeding. In certain cases, polyp margins were removed using Radial Jaw 4 biopsy forceps (Boston Scientific, Natick, MA, United States). In some cases, mucosa near the polyp was tattooed with Spot™ (GI Supply, Camp Hill, PA, United States) for future reference. All patients were observed in the recovery unit following their procedure until discharge criteria were met. Histopathology was assessed through the pathology department at UMHS.

Abstracted data included patient demographics, American Society of Anesthesiologists class score, and procedure indication. Recorded polyp characteristics included type, size, location, number, and the use of forceps in addition to snare. Outcomes assessed for the purpose of this study included adverse events such as delayed post-procedural bleeding and perforation. Post-procedural assessment was conducted by chart review of the University of Michigan Hospital Careweb and MiChart electronic medical records systems. Presence of a post-procedural adverse event was defined as hospitalization within 2 weeks of index endoscopy for gastrointestinal bleeding or abdominal pain based on UMHS admission records or telephone records. In cases where no follow-up (clinic visit or telephone follow-up) was available within 3 months of the procedure, patients were contacted by telephone.

Results

Duodenal polyps

Between 24 August 2011 and 29 April 2013, 10 mm or larger duodenal polyps (● Fig. 1 a) were removed from 15 patients by a single endoscopist (CP). The average age of the patients was 64 years. Nine of the patients were male. The average size of the polyps removed was 24 mm with a range of 10–60 mm in largest dimension, with the 60-mm polyp being fully circumferential. In 14 patients, a submucosal injection of 1:60 000 epinephrine in saline combined with Methylene Blue for lifting was performed (● Fig. 1 b). In nine patients, cold biopsy forceps were utilized for clean-up of polypoid tissue around snared edges (● Table 1). In two patients, hemostatic clips were used to control immediate bleeding. Each polyp was found to be adenomatous on histology. Follow-up was available in 13 patients (● Table 1). Within 2 weeks following the procedures, only one patient was hospitalized at an outside facility with gastrointestinal blood loss and bowel incontinence (● Table 2). The blood loss and bowel incontinence occurred 7 days after initial endoscopy. Oozing from the base of the polypectomy site was noted at the time of the follow-up endoscopy and four hemostatic clips were placed with cessation of bleeding. The patient had been chronically anti-coagulated with warfarin for a bioprosthetic porcine aortic valve. Anti-coagulation was held for 5 days before the index procedure without enoxaparin bridging. A repeat endoscopy was not required at the other facility and the patient was discharged without further

Table 1 Characteristics of patients with duodenal polyps.

Patient ID	Age (years)	Gender	Polyp size (mm)	Submucosal injection	Forceps	Clips	Follow-up	Adverse events requiring medical attention
1	53	M	15	Y	Y	N	Y	N
2	67	M	20	Y	Y	Y	Y	N
3	66	M	12	Y	Y	N	Y	N
4	45	F	40	Y	Y	N	N	N/A
5	27	M	12	Y	N	N	Y	N
6	78	F	30	Y	Y	N	Y	N
7	74	F	15	Y	N	N	Y	N
8	77	M	40	Y	Y	N	Y	N
9	63	M	23	Y	N	N	Y	N
10	41	F	35	Y	Y	Y	Y	N
11	86	F	20	Y	N	N	Y	N
12	86	M	60	Y	Y	N	Y	N
13	72	M	20	Y	Y	N	Y	N
14	69	M	15	Y	Y	Y	Y	Y – See text
15	50	F	10	N	N	N	N	N/A

M, male; F, female; Y, yes; N, no; N/A, data not available.

Table 2 Adverse events following duodenal and colonic polypectomies in patients with follow-up.

	Duodenal polypectomy follow-up (13/15)	Colonic polypectomy follow-up (12/15)
Perforation	0	0
Post-polypectomy syndrome	0	0
Pain post-polypectomy	0	1
Significant bleeding	1 ¹	0

¹ Patient on warfarin.

adverse events. Otherwise, there were no adverse events in the remainder of the cohort, including no perforations and no post-polypectomy syndrome.

Colonic polyps

Between 27 February 2012 and 30 May 2013, a total of 15 patients underwent resection of at least one colonic polyp ≥ 10 mm (• Fig. 2a) by a single endoscopist (CP). The average age of the patients was 68 years. Nine of the patients were male. The average size of the polyps removed was 20 mm with a range of 10–45 mm in the largest dimension. All polyps were removed using a cold snare. In all 15 patients, a submucosal injection of 1:60 000 epinephrine in saline combined with Methylene Blue for lifting was performed (• Fig. 2b). In 12 patients, cold biopsy forceps were utilized for clean-up of polypoid tissue around snared edges (• Table 3). None of the patients required hemostatic clips for control of immediate bleeding. Each polyp was found to be adenomatous on histology.

Follow-up was available in 12 patients (• Table 3). Within 2 weeks following the procedures, only one patient required a hospital visit for a suspected procedure-related adverse event (• Table 2). The patient presented to an outside hospital with right lower quadrant abdominal pain 1 day after resection of a 20-mm polyp from the appendiceal orifice. A computed tomography scan revealed no evidence of perforation or inflammatory changes and the patient was discharged home directly from the emergency department (ED) without intervention outside of

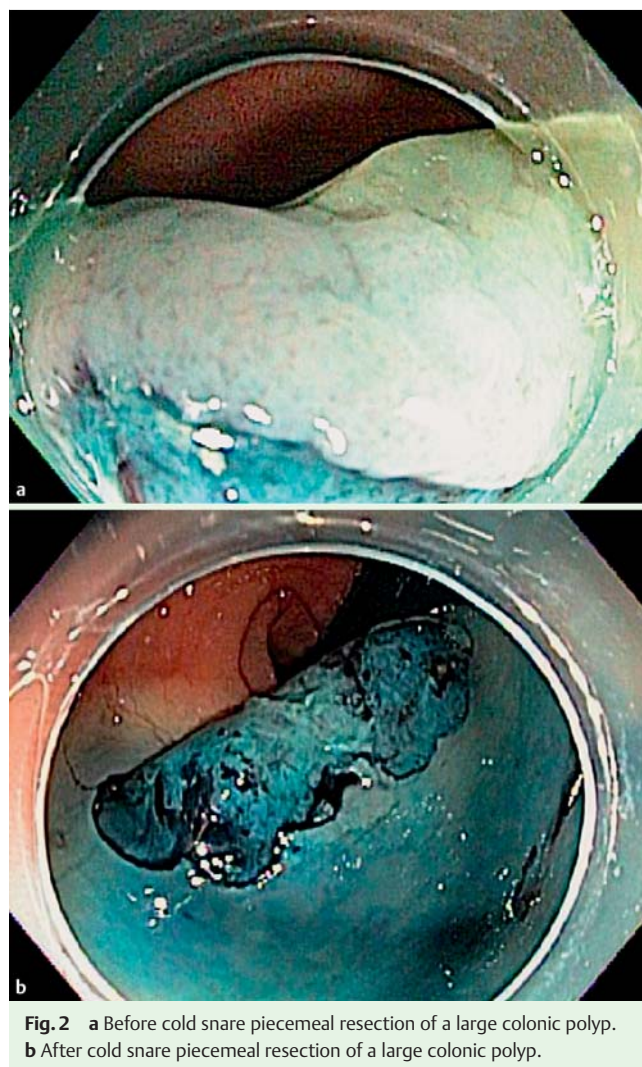


Fig. 2 a Before cold snare piecemeal resection of a large colonic polyp. b After cold snare piecemeal resection of a large colonic polyp.

symptom management with narcotic analgesia during the ED encounter.

There were no perforations, no post-polypectomy syndrome, and no significant delayed bleeding requiring transfusions or repeat

Table 3 Characteristics of patients with colonic polyps.

Patient ID	Age (years)	Gender	Polyp size (mm)	Submucosal injection	Forceps	Clips	Follow-up	Adverse events requiring medical attention
1	63	M	20	Y	Y	N	N	N/A
2	75	F	15	Y	Y	N	Y	N
3	56	F	25	Y	N	N	Y	N
4	49	F	25	Y	Y	N	Y	N
5	68	M	18	Y	Y	N	Y	N
6	79	M	20	Y	Y	N	Y	N
7	63	M	25	Y	Y	N	N	N/A
8	54	F	20	Y	Y	N	Y	Y – see text
9	85	F	35	Y	Y	N	Y	N
10	81	M	35	Y	Y	N	N	N/A
11	54	M	12	Y	Y	N	Y	N
12	71	M	45	Y	N	N	Y	N
13	62	M	12	Y	Y	N	Y	N
14	63	F	25	Y	Y	N	Y	N
15	51	M	20	Y	N	N	Y	N

M, male; F, female; Y, yes; N, no; N/A, data not available.

procedures. During follow-up telephone calls, three patients reported a small amount of hematochezia occurring within 24 hours following their polyp resection. The patients did not seek or require hospitalization or medical attention. Their bleeding resolved without intervention and they did not suffer any further adverse events. No other patients with follow-up suffered any procedure-related adverse events.

Discussion

This case series is the first to demonstrate that cold snare polypectomy for large duodenal and colonic polyps is technically feasible and may have a favorable safety profile compared to standard electrocautery-based endoscopic resection.

Avoidance of electrocautery provides the benefit of eliminating any risk of post-polypectomy electrocoagulation syndrome. A recent paper by Levin et al. [6] suggests that the incidence of post-polypectomy electrocoagulation syndrome is not particularly high with six cases out of 11 000 colonoscopies with biopsy. Other studies, however, have suggested a higher rate with the syndrome occurring in close to 1% of patients [7]. While post-polypectomy electrocoagulation syndrome resolves without surgery, it often necessitates hospitalization for imaging, pain control, and supportive management.

Avoidance of heat also reduces, if not eliminates, the risk of perforation. Studies have suggested that cold snare polypectomies may not confer any added risk of perforation [8]. As most polypectomies are aimed at eradicating adenomatous tissue rather than cancer, a deep resection or ablation beyond the superficial submucosa is not mandatory. Based on our experience in this series, it is doubtful that it is even technically possible to cut through the muscularis propria in normal bowel without the use of cautery.

There are a number of other reasons why it may be safer to avoid heat in the removal of large colonic and duodenal polyps. Larger arterial branches within the bowel wall are difficult to transect without heated snare loops; the use of cold snares may markedly reduce or eliminate the risk of large arterial vessel compromise. Immediate bleeding due to cold snare polypectomy is often the result of small capillary bleeding and venous oozing rather than

larger arterial bleeding which – in the absence of anticoagulation, antiplatelet therapy or inherent coagulopathy – resolves spontaneously in most, if not all, cases. In the reported series, all patients received dilute epinephrine in the injectate, which was added to maintain a clean field by minimizing capillary oozing during polypectomy. However, it is unclear if this is necessary as the lift fluid itself may provide adequate tamponade of smaller capillary vessels.

The effect of cautery and coagulation may provide the endoscopist with a false sense of security by reducing immediate bleeding, but then ultimately promotes the risk of more significant delayed bleeding from sloughing coagulated eschar. This sloughing eschar may occur 5–21 days after the initial polypectomy. With cold snare polypectomies, coagulated eschar formation is eliminated, and, thus, delayed bleeding may not be a significant risk. In our series, delayed bleeding did not occur in any patients who underwent colonic polypectomy and who had follow-up, and only occurred in one of the duodenal polypectomy patients; this patient was on warfarin. An added benefit of cold snare polypectomy may be that, if delayed bleeding were confidently eliminated, there would be no need for prophylactic hemostatic clip placement, a costly and time-consuming intervention. None of the colonic polypectomy cases in this series received prophylactic clipping, and only two of the duodenal polypectomy cases required clipping to manage immediate oozing. By reducing or eliminating delayed bleeding, not only would the morbidity and potential mortality to the patient be reduced, but there would also be the financial benefit of avoiding costly hospitalizations, blood transfusions, and repeat endoscopies or colonoscopies or even interventional radiology procedures.

Cautery has historically also been viewed as a useful tool in preventing polyp recurrence. In theory, cautery from hot snare or APC could destroy any remaining polyp tissue that was not resected, thus preventing recurrence. However, a recent study by Mannath et al. [9], which specifically looked at resection of colonic adenomas ≥ 1 cm, showed that the use of APC did not affect the recurrence rates after a piecemeal polyp resection. In this study, care was taken to excise wide margins of normal tissue around the polypectomy site to ensure the completeness of resection. However, if pieces are not taken in an overlapping manner, there could be residual polyp tissue at the base of the resec-

tion. This was part of the reason why we used cold forceps, to clean up any suspect areas at the base as well as the periphery of the polypectomy. Further study is needed to determine the relative rate of residual polyp tissue with this method.

There are several techniques that facilitate a successful snare polypectomy including a robust submucosal fluid injection, the use of blue dye in the injectate, and the use of braided snares. The submucosal injection and lift itself is of particular value in the resection of large polyps, especially using the cold snare polypectomy technique we describe. A lack of lift, for instance, can signify malignant invasion deeper than the submucosal layer [10] which would serve as a relative contraindication to an endoscopic resection. It appears that the lift also helps to “loosen-up” the submucosa making it easier to transect the submucosal layer, and particularly easier to resect wide lateral margins of tissue. The dye helps to differentiate between residual polyp at the base or margins, the submucosa, and normal intestinal mucosa.

Our experience has also shown that the Exacto snare, a thin braided snare, smaller than other available mini snares, can be a very useful tool in piecemeal resection of polyps. It tends to work well for sections of tissue sized up to 1.5 cm. Sections of tissue larger than 1.5 cm tend to require more of a “sawing” action with the Exacto snare and may be difficult to remove en bloc without heat. It appears that when it is used on larger pieces of tissue, it bunches up the submucosal layer; this makes it more difficult to cut through and can even make it somewhat difficult to discern a stump of bunched-up submucosa from residual mucosal polyp after resection. Therefore, we have found that limiting the size of individual resected pieces helps in producing a quicker, simpler, and cleaner resection. While, in theory, en bloc resection is felt to achieve a more complete lesion resection [11, 12], it is unclear whether en bloc resection in adenomas, rather than cancer, is truly superior to piecemeal resection in prevention of residual or recurrent adenoma [10], and ultimately, from an outcomes perspective, the primary goal in these patients is complete polyp removal with an adequate margin. We have used large capacity forceps and the Exacto snare to widely resect the lateral margins of the polypectomy site to ensure complete adenoma removal; we also take care to resect overlapping sections of polyp tissue and carefully examine the base of the resection to ensure there are no islands of residual adenoma. It should also be noted that, due to technical limitations, the larger a polyp is, particularly >15–20 mm, the more likely it is to be resected in piecemeal fashion anyway, and this may influence the incidence of residual adenomas. Currently, American Society for Gastrointestinal Endoscopy (ASGE) guidelines state that any patient with piecemeal removal of a sessile adenoma should have a repeat colonoscopy in 2 to 6 months to verify complete removal [13] regardless of whether heat is used or not.

Lastly, the use of dye such as Indigo Carmine or Methylene Blue has also been useful in aiding resection of polyps. The dyes can stain small intestinal, colonic, or metaplastic intestinal cells through active cellular absorption [14]. Consequently, dye use can be helpful in visualizing polyp margins and residual polyp tissue during resection, which aids in differentiating between residual polyp at the base or margins, the submucosa layer (stained blue), and normal intestinal mucosa.

Our series is the first to report the use of piecemeal cold snare for duodenal and colonic polyps ≥ 1 cm in size. We had no perforations, no post-polypectomy syndrome, and only one delayed bleeding episode in a patient on warfarin. While this is encouraging, comparative trials are required to determine whether cold

snare resection of duodenal and colonic adenomas truly reduces the risk of bleeding and perforation. Further studies could also shed light on the efficacy of cold snare compared to heat in producing a complete and durable polypectomy. While our results show promise in the utility of cold snare resection for larger duodenal and colonic polyps, we are aware that our series has several important limitations. As a pilot series, our sample size ($n=30$) was limited, precluding robust statistical analysis. Our lack of prospective long-term follow-up raises the possibility of under-reporting complications. In this retrospective case series, we lacked critical data on the adenoma recurrence rates in piecemeal cold snare polypectomy. These data are crucial to assess the safety and efficacy of cold snare polypectomy in large (>10 mm) polyps and our pilot study was not designed or powered to compare adenoma recurrence rates of cold snare versus hot snare resection of large polyps. Large prospective comparative studies should be performed to evaluate this important question.

If cold snare endoscopic resection is found to be as efficacious as, and safer than, hot snare, it will become the preferred approach for resection of larger polyps. In addition to the cost savings associated with reduced adverse events, it may obviate the cost and time necessary for the placement of prophylactic hemostatic clips. Physicians performing cold snare resections may also be more comfortable with the idea of fewer adverse events, which, in turn, may reduce the number of referrals to large academic centers for complex polypectomies. Given the potential for significant healthcare-related benefits, further trials evaluating the efficacy of cold snare polypectomy and comparing cold snare polypectomy to hot snare polypectomy should be strongly considered.

Competing interests: None

References

- 1 *Fyock CJ, Draganov PV.* Colonoscopic polypectomy and associated techniques. *World J Gastroenterol* 2010; 16: 3630–3637
- 2 *Van Gossum A, Cozzoli A, Adler M et al.* Colonoscopic snare polypectomy: analysis of 1485 resections comparing two types of current. *Gastrointest Endosc* 1992; 38: 472–475
- 3 *Tolliver KA, Rex DK.* Colonoscopic polypectomy. *Gastroenterol Clin North Am* 2008; 37: 229–251, ix
- 4 *Walsh RM, Ackroyd FW, Shellito PC.* Endoscopic resection of large sessile colorectal polyps. *Gastrointest Endosc* 1992; 38: 303–309
- 5 *Carvalho R, Areia M, Brito D et al.* Endoscopic mucosal resection of large colorectal polyps: prospective evaluation of recurrence and complications. *Acta Gastroenterol Belg* 2013; 76: 225–230
- 6 *Levin TR, Zhao W, Conell C et al.* Complications of colonoscopy in an integrated health care delivery system. *Ann Intern Med* 2006; 145: 880–886
- 7 *Waye JD, Kahn O, Auerbach ME.* Complications of colonoscopy and flexible sigmoidoscopy. *Gastrointest Endosc Clin N Am* 1996; 6: 343–377
- 8 *Choo WK, Subhani J.* Complication rates of colonic polypectomy in relation to polyp characteristics and techniques: a district hospital experience. *J Interv Gastroenterol* 2012; 2: 8–11
- 9 *Mannath J, Subramanian V, Singh R et al.* Polyp recurrence after endoscopic mucosal resection of sessile and flat colonic adenomas. *Dig Dis Sci* 2011; 56: 2389–2395
- 10 *Ferrara F, Luigiano C, Ghersi S et al.* Efficacy, safety and outcomes of ‘inject and cut’ endoscopic mucosal resection for large sessile and flat colorectal polyps. *Digestion* 2010; 82: 213–220
- 11 *Su MY, Hsu CM, Ho YP et al.* Endoscopic mucosal resection for colonic non-polypoid neoplasms. *Am J Gastroenterol* 2005; 100: 2174–2179
- 12 *Katsinelos P, Kountouras J, Paroutoglou G et al.* Endoscopic mucosal resection of large sessile colorectal polyps with submucosal injection of hypertonic 50 percent dextrose-epinephrine solution. *Dis Colon Rectum* 2006; 49: 1384–1392
- 13 *Levin B, Lieberman DA, McFarland B et al.* Screening and surveillance for the early detection of colorectal cancer and adenomatous polyps,

- 2008: a joint guideline from the American Cancer Society, the US Multi-Society Task Force on Colorectal Cancer, and the American College of Radiology. *Gastroenterology* 2008; 134: 1570–1595
- 14 *Canto MI*. Staining in gastrointestinal endoscopy: the basics. *Endoscopy* 1999; 31: 479–486
 - 15 *Horiuchi A, Nakayama Y, Kajiyama M* et al. Removal of small colorectal polyps in anticoagulated patients: a prospective randomized comparison of cold snare and conventional polypectomy. *Gastrointest Endosc* 2014; 79: 417–423
 - 16 *Ichise Y, Horiuchi A, Nakayama Y* et al. Prospective randomized comparison of cold snare polypectomy and conventional polypectomy for small colorectal polyps. *Digestion* 2011; 84: 78–81
 - 17 *Lee CK, Shim JJ, Jang JY*. Cold snare polypectomy vs. Cold forceps polypectomy using double-biopsy technique for removal of diminutive colorectal polyps: a prospective randomized study. *Am J Gastroenterol* 2013; 108: 1593–1600
 - 18 *Uraoka T, Ramberan H, Matsuda T* et al. Cold polypectomy techniques for diminutive polyps in the colorectum. *Dig Endosc* 2014; 26: 98–103
 - 19 *Vormbrock K, Mönkemüller K*. Difficult colon polypectomy. *World J Gastrointest Endosc* 2012; 4: 269–280