

Intraductal biliopancreatic imaging: European Society of Gastrointestinal Endoscopy (ESGE) technology review



Authors

Andrea Tringali¹, Arnaud Lemmers², Volker Meves³, Grischa Terheggen⁴, Jürgen Pohl³, Guido Manfredi⁵, Michael Häfner⁶, Guido Costamagna¹, Jacques Devière², Horst Neuhaus⁴, Fabrice Caillol⁷, Marc Giovannini⁷, Cesare Hassan⁸, Jean-Marc Dumonceau⁹

Institutions

Institutions are listed at end of article.

Bibliography

DOI <http://dx.doi.org/10.1055/s-0034-1392584>
Published online: 6.7.2015
Endoscopy 2015; 47: 739–753
© Georg Thieme Verlag KG
Stuttgart · New York
ISSN 0013-726X

Corresponding author

Andrea Tringali, MD PhD
Digestive Endoscopy Unit,
Catholic University
Largo A. Gemelli 8
00168 Rome, Italy
Fax: +39-06-30157220
andrea.tringali@rm.unicatt.it

This technology review expresses the current view of the European Society of Gastrointestinal Endoscopy (ESGE) on the available techniques for intraductal biliopancreatic imaging.

The three *cholangioscopy* techniques are described: the “dual-operator” and “single-operator” mother-baby approaches using dedicated instruments, and the “direct” technique using currently available ultrathin gastroscopes.

The mother-baby method is standardized and reproducible, while direct cholangioscopy is technically demanding and its safety requires further evaluation.

As well as direct visualization of the bile ducts, cholangioscopy has the further advantage of allowing targeted biopsy.

Image quality is still suboptimal for single-operator cholangioscopy, while the other techniques have achieved adequately detailed imaging.

The costs of mother-baby cholangioscopy are high and its application in clinical practice should be restricted to selected cases (i.e. indeterminate

biliary strictures/intraluminal lesions, difficult biliary stones) and to the setting of tertiary care centers.

Peroral pancreatoscopy may find an indication in situations where other imaging modalities (mainly EUS) are inconclusive (i.e. delineation of main duct intraductal papillary mucinous neoplasia extension, sampling of indeterminate main pancreatic duct strictures)

Intraductal ultrasonography (IDUS) has a poorer performance than EUS in the staging of pancreatic malignancies and can increase the risk of pancreatitis. A promising indication for IDUS could be the evaluation of indeterminate biliary strictures and ampullary tumors.

Probe-based confocal laser endomicroscopy (pCLE) of the bile ducts is a difficult and expensive technique. Appropriate training needs to be established, since interpretation of images is challenging. pCLE can be an important diagnostic tool in the setting of indeterminate biliary strictures.

Abbreviations

3D-IDUS	three-dimensional intraductal ultrasonography	IDUS	intraductal ultrasonography
CBD	common bile duct	IPMN	intraductal papillary mucinous neoplasia
CI	confidence interval	MRI	magnetic resonance imaging
CLE	confocal laser endomicroscopy	MRCP	magnetic resonance cholangiopancreatography
CT	computed tomography	NBI	narrow band imaging
DOC	double-operator cholangioscopy	OR	odds ratio
EHL	electrohydraulic lithotripsy	pCLE	probe-based confocal laser endomicroscopy
EPLBD	endoscopic papillary large balloon dilation	POPS	peroral pancreatoscopy
ERC	endoscopic retrograde cholangiography	SOC	single-operator cholangioscopy
ERCP	endoscopic retrograde cholangiopancreatography		
ESWL	extracorporeal shockwave lithotripsy		
EUS	endoscopic ultrasonography		
FNA	fine needle aspiration		

Introduction

Endoscopic retrograde cholangiopancreatography (ERCP) is a diagnostic and therapeutic invasive imaging modality of the biliopancreatic duct

tal system. It provides an “indirect” radiological visualization of the biliopancreatic system. The first direct peroral visualization of the biliopancreatic system was described in 1975 [1] and it has since become an important diagnostic tool in selected cases, when other available techniques (e.g. endoscopic ultrasonography [EUS], computed tomography [CT] scanning, magnetic resonance imaging [MRI], biopsy sampling) cannot provide a definitive diagnosis. Therapeutic goals were then pursued, mostly the extraction of biliary and pancreatic stones using electrohydraulic or laser lithotripsy. The main drawbacks of cholangiopancreatography include costs, suboptimal imaging quality, and the fragility of the devices. During the last 20 years, the development of high quality video cholangioscopes (Table 1) has partially resolved some of these problems. Intraductal biliopancreatic imaging modalities were expanded, with new and expensive techniques (Table 2) aiming at visualizing the thickness of duct walls as well as periductal structures (intraductal ultrasound, confocal laser endomicroscopy [CLE]).

This technology review expresses the current view of the European Society of Gastrointestinal Endoscopy (ESGE) about the presently available techniques for intraductal biliopancreatic imaging.

Methods

The aim of this technology review is to clarify technical aspects for those who actually perform endoscopic procedures [2]. The methodology was adapted from that used for ESGE clinical guide-

lines; notable differences include the absence of key questions and recommendations. In September 2013, the project was endorsed by the ESGE Governing Board. Different topics were each assigned to a subgroup of experts after a general discussion during a meeting held in October 2013 (Berlin, Germany).

The final search of the relevant literature was performed in November 2014 using Medline (via Pubmed), the Cochrane Library, Embase, and the internet. In March 2015, a draft prepared by A. T. was sent to all group members. After agreement on a final version, the manuscript was reviewed by two members of the ESGE Governing Board and sent to all ESGE individual members for comments. It was then submitted to the journal *Endoscopy* for publication. This technological review was issued in 2015 and will be considered for update in 2019.

Dual-operator “mother-baby” peroral cholangioscopy

Introduction

Dual-operator cholangioscopy (DOC) is commonly referred to as “mother-baby cholangioscopy”; it uses a very slim endoscope passed through the working channel of a duodenoscope. Two endoscopists are needed to control the instruments.

Equipment and technique

A biliary sphincterotomy is usually performed to facilitate passage of the cholangioscope (95% of 144 patients in a retrospective series) [3]. Then, the cholangioscope (“baby” scope) is passed through the accessory channel of the duodenoscope (“mother”

Table 1 Characteristics of available “mother-baby” cholangiopancreatoscopes.

Endoscope	Type	Operators, n	Tip diameter, mm	Working channel, mm	Image enhancement	Lumens, n	Tip deflection	Deflection angulation	Field view	Focal distance, mm	Working length, m
CHF-BP30 (Olympus)	Fiber	2	3.1	1.2	No	1	2-way	290°: up 160° down 130°	90°	1–50	1.87
FCP-9P (Pentax)	Fiber	2	3	1.15	No	1	2-way	180°: up 90° down 90°	90°	1–50	1.9
CHF-B160 ¹ (Olympus)	Video	2	4	1.2	No	1	2-way	140°: up 70° down 70°	90°	3–20	2
CHF-B260 ¹ (Olympus)	Video	2	3.4	1.2	Yes (NBI)	1	2-way	140°: up 70° down 70°	90°	3–20	2
CHF-B260 ¹ (Olympus)	Video	2	2.6	0.5	Yes (NBI)	1	2-way	140°: up 70° down 70°	90°	3–20	2
Spyglass (Boston Scientific)	Video	1	3.4	1.2	No	3 (1 working channel, 2 irrigation channels)	4-way	240°: up 60° down 60° right 60° left 60°	70°	1–50	2.3
Polyscope (Polydiagnost)	Video	2	2.7	1.2	No	1	1-way	180°	70°	2–10	1.85

NBI, narrow band imaging.

¹ Not commercially available in Europe.

Table 2 Estimated costs (in euros) of intraductal biliopancreatic imaging devices commercially available (in Europe).

Technique	Imaging console	Endoscope/catheter/optical fiber/probe
Dual-operator "mother-baby" fiber pancreatocholangioscope		
Olympus, CHF-BP30	Standard light source	16 000 €
Pentax, FCP-9P	Standard light source	18 500 €
Dual-operator "mother-baby" video pancreatocholangioscope		
Polydiagnost, Polyscope	45 000 €	Catheter (single use) 1000 € Optical fiber 10 000 €
Single-operator "mother-baby" video pancreatocholangioscope		
Boston Scientific, SpyGlass	65 000 €	Catheter (single use) 1400 € Optical fiber (20 uses) 5000 €
Direct cholangioscopy (transnasal gastroscopes)		
Olympus, GIF-N180	Standard videoprocessor	29 000 €
Pentax, EG16-K10	Standard videoprocessor	27 000 €
Fuji, EG-530NP	Standard videoprocessor	28 500 €
Intraductal ultrasonography		
(Olympus)	65 000 €	Probe (reusable) 7000 €
Confocal laser endomicroscopy		
Mauna Kea, Cellvizio	150 000 €	Probe (10 uses) 8000 €

scope), usually over a guidewire for easier biliary cannulation. Once the target area has been reached, the guidewire is removed to enhance visualization and to allow the use of the working channel. Irrigation with sterile saline is commonly used to provide a clear vision of the bile duct, while carbon dioxide has been reported to be an interesting alternative in two small comparative nonrandomized series [4,5]. Briefly, the two studies found a shorter procedure time with carbon dioxide versus saline and, in one study [4], a better image quality. Bile is removed from the bile duct through the working channel of the choledochoscope using a syringe; no significant increase in venous Pco₂ levels was recorded after the procedure [4].

Possible interventions during mother-baby cholangioscopy include forceps biopsy sampling and electrohydraulic/laser lithotripsy under direct vision [6].

Diagnostic indications

In patients with bile duct strictures and unclear filling defects, adding cholangioscopic appearance data to biopsy sampling/brush cytology under fluoroscopic or cholangioscopic guidance may improve the diagnostic yield (Table 3) [3,7–9]. Characteristics of malignancy at DOC include thick, irregular, and tortuous vessels, irregular papillogranular or nodular elevated surface, and a tendency to bleed easily. Characteristics of benign lesions include a fine network of thin vessels and a relatively flat surface, a homogeneous papillogranular surface suggesting hyperplasia, a bumpy surface indicative for inflammation, or a whitish color with convergence of folds suggesting scars.

More recently, optical image manipulation using narrow band imaging (NBI) has been introduced for video cholangioscopes. In small prospective series (<30 cases) of patients with biliary strictures or filling defects, NBI greatly improved visualization and allowed the detection of lesions not visible with white light. For example, a better definition of the mucosal structure of intraductal papillary neoplasms of the bile duct was described with NBI cholangioscopy [10]. Improved visualization of the vascular pattern with NBI cholangioscopy was also found helpful for diagnosing

indeterminate biliary strictures, and the information provided by the macroscopic appearance was judged more sensitive than brush cytology. The prospective multicenter study by Osanai et al., summarized in Table 3, used NBI.

Cholangioscopy, with or without NBI, was of little help in the evaluation of external biliary compression where the mucosa appears normal [11].

Further comparisons of NBI cholangioscopy with tissue sampling results are expected for a definition of its role. NBI cholangioscopes are not commercially available in Europe.

Therapeutic indications

Guidance for lithotripsy (electrohydraulic lithotripsy [EHL] or laser lithotripsy) is the most common indication for DOC (Fig. 1). After failure of stone extraction during ERCP, cholangioscopy-guided EHL and laser lithotripsy were reported to allow duct clearance in 77%–96% of cases in four series that included 292 patients [12–15]. Stone recurrence was reported in 16%–18% of the patients after a mean follow-up of 2 to 5 years [13–15]. Median procedure duration (cholangioscopy+EHL/laser lithotripsy) was 2 hours in a Swedish series [14]; repeated treatment sessions have been required in nearly 20% of cases [12]. Interestingly DOC-guided lithotripsy was successfully used in 50 patients with type II Mirizzi syndrome, obtaining stone clearance in 48 (96%) [15]. EHL and laser lithotripsy can be used also under fluoroscopic control; DOC-guided lithotripsy has been recommended for intrahepatic stones and stones proximal to a bile duct stricture [16].

Complications and limitations

A retrospective study that compared ERCP with versus without cholangiopancreatography (n=402 vs. n=3475, respectively) showed increased morbidity if cholangiopancreatography was performed (odds ratio [OR] 2.50, 95% confidence interval [95% CI] 1.56–3.89), in particular for cholangitis (OR 4.98, 95% CI 1.06–19.67) [17]. A proposed mechanism for the increased risk of cholangitis is the use of intermittent intraductal irrigation dur-

Table 3 Results of intrabiliary tissue sampling combined or not with double-operator cholangioscopy (DOC) for the diagnosis of malignancy in selected series.

First author, year Modality	Patients, n	Sensitivity, %	Specificity, %	Accuracy, %	Study design (data collection)
Fukuda, 2005 [7]	90				Prospective
ERC/tissue sampling ¹		57	100	78	
ERC/tissue sampling ¹ + DOC		100	86	93	
<i>P</i> value		<i>P</i> < 0.05		<i>P</i> < 0.05	
Itoi, 2010 [3]	120				Retrospective
ERC/tissue sampling ²		86	79	85	
ERC/tissue sampling ² + DOC		99	95	98	
<i>P</i> value		<i>P</i> < 0.001		<i>P</i> < 0.001	
Nishikawa, 2011 [8]	33				Prospective
DOC guided biopsy forceps		38	100	60.6	
DOC visual finding		100	91	97	
<i>P</i> value				<i>P</i> < 0.0018	
Osanai, 2013 [9]	35				Prospective
Tissue sampling ²		81	100	85	
DOC + NBI visual finding		96	80	92	

ERC, endoscopic retrograde cholangiography; NBI, narrow band imaging.

¹ Endobiliary sampling under fluoroscopic guidance using biopsy forceps (n = 24) and brush cytology (n = 66).

² Endobiliary biopsy forceps under fluoroscopic guidance and DOC-guided biopsy forceps.

ing cholangioscopy. Complications of cholangioscopy with EHL (cholangitis, hemobilia, biliary leak, bradycardia) have been reported in up to 18% of cases [12]. Therefore, patients should be carefully selected before being subjected to cholangiopancreatography. Antibiotic prophylaxis is important; additionally biliary drainage should be considered in selected cases following cholangioscopy.

The main limitations of DOC remain the need for two operators, and the cost and fragility of the equipment [18]: in a series including 21 patients the cholangioscope malfunctioned on the 22nd procedure [19].

Conclusion

Dual-operator cholangioscopy is a standardized and reproducible technique that now has good image quality. Because of costs, complexity, and procedure-related morbidity, it should be considered in selected cases only, in particular for some indeterminate biliary strictures/intraluminal lesions, and difficult biliary stones, and only in the setting of tertiary care centers. Standardization of visual diagnostic criteria for benign and malignant lesions, with and without image-enhancement technology, is expected from future studies.

Single-operator “mother-baby” peroral cholangioscopy

Introduction

Single-operator cholangioscopy (SOC) was introduced by Boston Scientific (Natick, Massachusetts, USA) with the SpyGlass direct visualization system. Its most distinctive feature is the capability for a single endoscopist to perform cholangiopancreatography using the “mother-baby” method, by securing the access and delivery catheter to the duodenoscope handle. It includes disposable and reusable parts as well as a dedicated image processor.

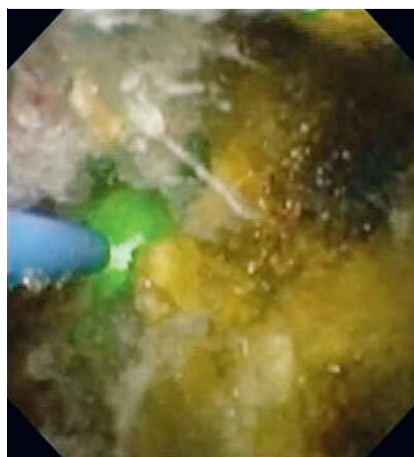


Fig. 1 “Mother–baby” dual-operator video cholangioscopy. Laser fragmentation of a common bile duct stone.

Equipment and technique

The Spyglass system includes a 10-Fr access and delivery catheter with a 1.2-mm-diameter working channel, a 0.9-mm-diameter channel for the reusable optical probe, and two dedicated 0.6-mm-diameter irrigation channels. The access catheter is introduced through a duodenoscope with a minimum working channel diameter of 4.2 mm. The tip of the catheter can be deflected by at least 30 degrees in the four directions, which is an improvement over the single-plane deflection tip of most reusable baby endoscopes. The dedicated irrigation channels contribute to obtaining a clear optical field during the procedure. A dedicated disposable 3-Fr biopsy forceps is available. SOC-guided tissue sampling and intraductal lithotripsy are possible through the working channel of the access catheter.

Other components consist of a video monitor and a travel cart housing the light source, a camera, an insulated transformer, and an irrigation pump with a footswitch.

Diagnostic applications

SOC with the SpyGlass system has a reported success rate of >90% [20–23]. The main indication for SOC is the evaluation of biliary strictures (● Fig. 2) and filling defects. The mean sensitivity of biliary sampling, using the dedicated 3-Fr biopsy forceps, for discriminating between malignant and benign biliary lesions was 68% [20–26] (● Table 4), slightly higher than those reported for brushing (59%) and biopsy (63%) in the setting of cholangiocarcinoma [27]. The sensitivity of SOC appearance was also assessed in two prospective trials and it was found to be higher (84%–95%) than that of biopsy sampling (49%–82%) [20,26]. However, the value of subjective “impressions,” as against hard data such as provided by a biopsy sample, is questionable at a stage of disease work-up that is advanced enough for performance of direct biliopancreatic imaging. Furthermore, interobserver agreement for diagnosis using SOC appearance is only fair [28]. In a prospective multicenter study, the sensitivity of SOC-directed biopsy sampling was far higher for intrinsic (66%) than for extrinsic (8%) malignant lesions [20].

Less common settings in which SOC has been used include the evaluation of cystic lesions in the biliary tract, precise mapping and delineation of cholangiocarcinoma before resection, confirmation of bile duct stone clearance, and evaluation of the biliary tract after bile duct surgery and after liver transplantation [29, 30]. The incremental information obtained through SOC compared with ERCP alone in these situations remains to be determined.

Therapeutic applications

The major therapeutic indication for SOC is lithotripsy for difficult biliary stones. SOC-guided lithotripsy has been reported as effective and safe with a success rate of 90%–100% and a decreased need for mechanical lithotripsy [20,21,31]. This technique would currently compete with endoscopic papillary large balloon dilation (EPLBD) for bile duct stone extraction. A recent meta-analysis of EPLBD has found an overall stone clearance rate of >95% with decreased use of mechanical lithotripsy [32]. Advantages of SOC over EPLBD include the possibility to treat larger biliary stones and to extract pancreatic stones (although this should be limited to highly specialized centers) [33]. A potential advantage of SOC is its ability to better assess bile duct clearance than ERCP; the latter has been reported to fail to identify residual bile duct stones in 8%–16% of cases, although the clinical significance of residual stones identified at SOC remains to be elucidated [21]. Disadvantages of SOC compared with EPLBD include the cost of the disposable devices and of the specific equipment (SOC plus lithotripsy device); thus, its most profitable use could be limited to extraction of stones that cannot be removed using EPLBD.

Other reported therapeutic uses of SOC include treatment of anastomotic biliary strictures and of biliary casts after liver transplant [34], transpapillary gallbladder drainage in acute cholecys-

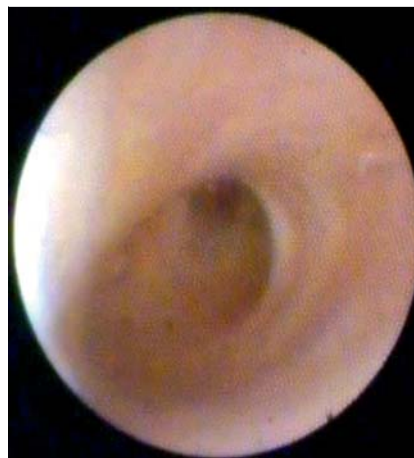


Fig. 2 Single-operator cholangioscopy. Fibrotic biliary stricture due to cholecystectomy.

titis [35], removal of foreign body [36], retrieval of migrated pancreatic stents [37], and assistance in guidewire placement.

Complications and limitations

As stated in the section on mother-baby cholangioscopy, patients should be carefully selected before being subjected to cholangio-pancreatography because of the added morbidity compared with ERCP alone [17].

Diagnostic and therapeutic SOC entailed similar incidences of serious procedure-related adverse events (7.5% and 6.1%, respectively) in a prospective multicenter cohort study that involved 297 patients [20]. The most frequent adverse event was early cholangitis (3.1%).

Limitations of the SpyGlass system include an image quality inferior to that of conventional endoscopes, the lack of virtual chromoendoscopy capability, and the small diameter of the working channel (1.2 mm). Constraints of SOC include the cost of the specific processor and of disposable components.

Conclusion

SOC is a promising technique. Improvement of image quality and careful evaluation of costs are required before any advantage over other cholangioscopy techniques can be addressed.

Direct cholangioscopy



Introduction

Direct cholangioscopy refers to the use of nonspecific endoscopes, usually ultraslim endoscopes designed for pediatric or transnasal esophagogastroduodenoscopy, to directly enter the common bile duct (CBD); it was first described in 1977.

First author, year	Patients, n	Sensitivity, % (n/n)	Study design (data collection)
Chen, 2007 [20]	20	71 (5/7)	Prospective
Chen, 2011 [21]	95	49 (22/45)	Prospective
Ramchandani, 2011 [26]	22	82 (18/22)	Prospective
Draganov, 2012 [22]	26	76 (13/17)	Prospective
Hartmann, 2012 [23]	106	57 (16/28)	Retrospective
Kalaitzakis, 2012 [24]	124	66 (35/53)	Retrospective
Manta, 2013 [25]	42	88 (37/42)	Prospective
Total	435	68 (146/214)	

Table 4 Sensitivity of single-operator cholangioscopy-directed biliary biopsy sampling for the diagnosis of malignancy in selected series.

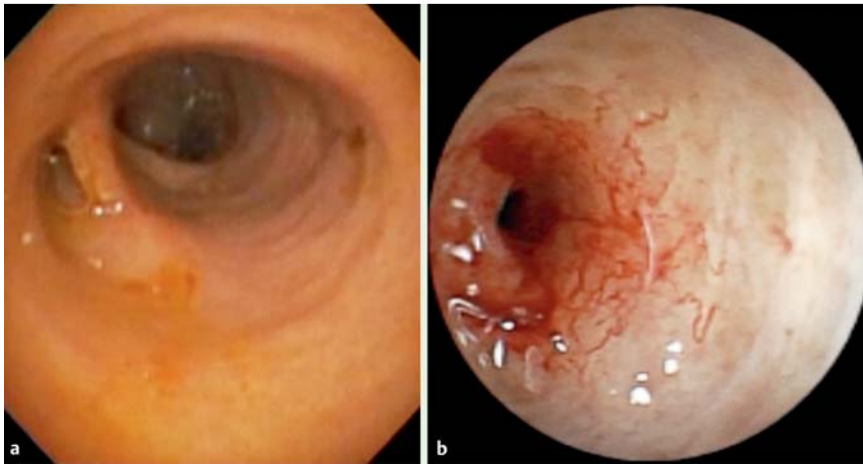


Fig. 3 Direct cholangioscopy. **a** Normal common bile duct with the cystic duct orifice. **b** Biliary stricture due to a desmoplastic cholangiocellular carcinoma with neovascularization.

Equipment and technique

Direct cholangioscopy requires previous ERCP with a large endoscopic sphincterotomy and/or sphincteroplasty. Different direct cholangioscopy techniques have been reported:

- ▶ *The tandem technique* consists of introducing a guidewire into the CBD, withdrawing the duodenoscope and then backloading the wire into an ultraslim endoscope that is advanced over the wire into the CBD under fluoroscopic guidance. Wire dislocation is frequent with this technique [38].
- ▶ *Freehand intubation* has been used in the majority of recent studies. The endoscope is manipulated to assume a “J” configuration in front of the sphincterotomy, and a guidewire or a 5-Fr balloon catheter is inserted in an intrahepatic bile duct or upstream from a stricture. The endoscope is then advanced over the guide into the bile ducts [39]. For interventional procedures, the balloon catheter must be withdrawn from the working channel of the endoscope, which may make the endoscope position unstable. Additionally, firm anchoring of the intraductal balloon can in some cases be difficult, especially in patients without intraductal stenoses or with extreme CBD dilation. A dedicated anchoring balloon was withdrawn by the manufacturer shortly after it became available, because of reports of fatal air embolism during the procedure [40].
- ▶ *Overtube balloon-assisted direct cholangioscopy* has also been reported [41]. However, the currently available overtubes are very large relative to ultraslim endoscopes, making it difficult to manipulate both the overtube and the endoscope. Therefore, further development of a more appropriate accessory is required to improve the interventional performance of direct cholangioscopy.

Technical success rates

An anchoring balloon (15 mm diameter, 5-Fr channel; MTW Endoskopie, Wesel, Germany) is recommended if the freehand intubation technique is used: in a comparative nonrandomized study, success rates with an anchoring balloon vs guidewire alone were 95.2% vs. 45.5%, respectively [38]. Similar success rates (88% and 81%) were reported with the balloon anchoring technique in smaller series of patients [42, 43, 44]. The overtube balloon-assisted direct cholangioscopy technique was reported to be successful in 10 of 12 patients (83%) [41].

Success rates were similar for direct cholangioscopy and mother-baby techniques in a randomized controlled trial [45].

Diagnostic applications

High resolution imaging (▶ **Fig. 3**) and virtual chromoendoscopy may help to discriminate neoplastic from non-neoplastic strictures on the basis of irregular vascular patterns and surface features [45]. So far however, visual criteria for malignancy, and corresponding diagnostic yields, have not been fully established. The large diameter of the working channel permits passage of a large biopsy forceps, which may increase the diagnostic yield.

Therapeutic applications

The 2.0-mm working channel of ultraslim upper gastrointestinal endoscopes used for direct cholangioscopy permits a wide array of therapeutic interventions, the most common being CBD stone removal. Small biliary stones can be removed under direct visual control using 5-Fr baskets or other accessories [46]; large stones can be treated using laser or EHL lithotripsy [38, 42, 47]. Intraductal neoplasia has been treated using argon plasma coagulation [42, 48, 49]. Direct placement of a 5-Fr stent or of a transnasal drain after selective guidewire insertion has also been reported [50]. If a complex biliary stricture cannot be traversed at ERCP, direct cholangioscopy may enable identification of the stricture site, biopsy sampling, and direct drainage [51].

Complications and limitations

The safety of direct cholangioscopy is questionable because of the occurrence of rare but severe adverse events, in particular stroke caused by leakage of air into the portal or hepatic venous system, which may pass through a patent foramen ovale to the left circulation [43, 52–54]. This complication is probably related to the increased intrabiliary pressure due to intraductal air insufflation combined with papillary obstruction by the endoscope. To lower the risk of such serious complications we strongly recommend the following safety measures, although it must be acknowledged that their efficacy has not been tested:

1. Keep gas insufflation to an absolute minimum, or even better, use carbon dioxide or saline irrigation rather than air to clear the bile duct.
2. Establish a wide papillary opening before the endoscope is inserted into the CBD. To this end, we carry out a large sphincterotomy or supplement the sphincterotomy with balloon dilation up to 10 mm.
3. If feasible, avoid mucosal trauma on the day of direct cholangioscopy, as the reported cases of air embolization occurred mainly during sphincterotomy.

	Dual-operator “mother-baby” cholangioscopy	Single-operator “mother-baby” cholangioscopy	Direct cholangioscopy
Number of endoscopists	2	1	1
Directions of steering	2	4	2–4
Separate irrigation channel	–	+	–
Diameter of the working channel, mm	1.2	1.2	2
Quality of the image	+	–	+
Virtual chromoendoscopy	–/ +	–	+
Need for separate processor	+	+	–
High procedure costs	+	+	–
Availability	–	–	+
Ease of biliary access	+	+	–
Stability	+	+	–
Passage of strictures	+	+	–
Deep intrahepatic access	+	+	–
Wide range of accessories	–	–	+
Air embolism	–	–	+

Table 5 Comparison of the three different cholangioscopy techniques currently available.

Anchoring balloons may also involve a specific risk as, in an animal study, overinflation of the anchoring balloon resulted in biliary perforation [55]. The device was later voluntarily withdrawn from the market by the manufacturer, but these reported adverse events should prompt investigators to be very cautious in ensuring that anchoring balloons are not overinflated.

In the largest series published so far [42], the incidence of post-procedural cholangitis was 10% although patients were treated with periprocedural prophylactic antibiotics.

In most cases direct cholangioscopy is limited to the examination of the CBD only, as the endoscope cannot be entered into small diameter bile ducts [45]. On the other hand, direct cholangioscopy is less costly than mother-baby technologies as no purchase of a dedicated cholangioscopy system is required, the system is more robust, and the endoscope may be used for esophagogastroduodenoscopy. Advantages and limitations of direct cholangioscopy compared with mother-baby technologies are listed in **Table 5**.

Conclusion

Direct cholangioscopy is a technically demanding technique limited to the examination of the CBD, and its safety needs further investigation. Prospective comparisons of direct cholangioscopy versus mother-baby technologies are expected to identify the optimal application of each technique.

Pancreatoscopy

Introduction

Since the introduction of fiberoptic cholangiopancreatography, technological refinements have permitted the development of new ultrathin devices that do not require pancreatic sphincterotomy for their introduction, as well as of larger devices with a working channel that allows the passage of biopsy forceps and that have four-way tip deflection that improves maneuverability within the duct. Electronic pancreatoscopes with improved optical resolution (**Fig. 4**) or NBI modality allow the detection and characterization of the vascular pattern of tumors and of mucosal appearances.

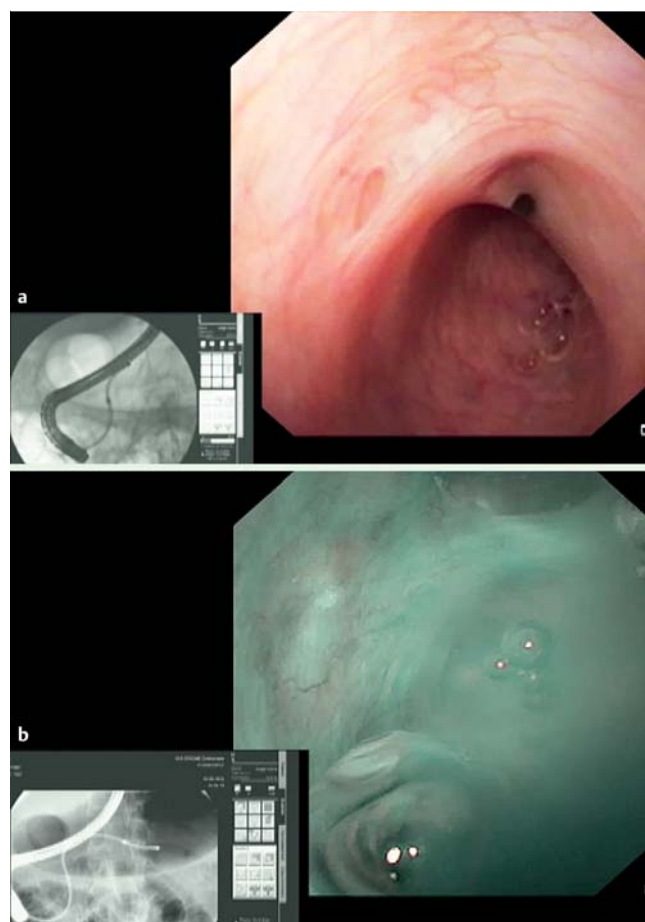


Fig. 4 Peroral video pancreatoscopy. **a** Normal main pancreatic duct. **b** Narrow band imaging mode enhancing abnormal vessels in the cystic portion of a main duct intrapapillary mucinous neoplasm (IPMN) at the tail of the pancreas.

Equipment and technique

The technical characteristics of different fiberoptic endoscopes used for peroral pancreatoscopy (POPS) and cholangioscopy are listed in **Table 1**. The 2.6- to 4-mm-diameter pancreatoscopes can be passed through the 4.2-mm working channel of a therapeutic duodenoscope. The 1.2-mm working channel of the pancreatoscope permits use of a 0.035-inch guidewire, a 3-Fr biopsy

forceps, EHL, or laser lithotripsy. Video adapters convert the fiberoptic image to a video format. Video pancreatoscopes with a large external diameter (5.2 mm) cannot be passed through duodenoscopes but thinner models (2.6 mm) are under investigation [56,57].

The introduction of the endoscope through the papilla is similar to that described for mother-baby cholangioscopy, most commonly through the major papilla although it may also be possible through the minor papilla [58]. In the absence of a patulous orifice typical of intraductal papillary mucinous neoplasia (IPMN), a pancreatic sphincterotomy might be necessary, depending on the device diameter [59]. After introduction of the pancreatoscope into the main pancreatic duct, a guidewire might be necessary to reach the caudal portion of the main pancreatic duct. The main pancreatic duct is often examined under irrigation with saline to clear the view and under fluoroscopy to locate lesions [59]. In some reports, secretin (100IU, intravenous) was used to stimulate the exocrine function and thus clear the view [60].

The Spyglass system, initially used for cholangioscopy, can provide better maneuverability within the main pancreatic duct than other endoscopes used for POPS.

Recently, direct POPS has been described, that uses ultraslim 4.9-mm gastroscopes, employing two techniques:

- ▶ A 5-Fr anchoring balloon catheter is inflated in the main pancreatic duct in patients with suspected IPMN [61].
- ▶ An overtube is used to prevent stomach loop formation during insertion of the ultraslim gastroscope over a guidewire left in the main pancreatic duct [62]. In a variation of the technique, the overtube was punctured at 65 cm from its end to allow passage of the ultraslim gastroscope [63].

Diagnostic applications

Intraductal papillary mucinous neoplasia (IPMN)

IPMNs are mucin-producing tumors that involve the pancreatic duct mucosa and may present various degrees of malignant potential. They can be classified into three types: main duct, branch duct, and mixed-type IPMNs. The distinction between these different types is usually made at MRI; it helps to define adequate patient management [64].

POPS has been used to detect features associated with high risk of malignancy (protruding lesions, some vascular patterns); to define the extent of main pancreatic duct lesions prior to surgery, in order to select the parts of the pancreas to be resected; or to collect samples. The literature shows that:

- ▶ POPS has been reported in patients with IPMN in 6 series with a total of 185 patients [65–70]; the success rate was >90% for the SpyGlass system [65, 69].
- ▶ Pancreatic sphincterotomy was not required in most recent series using mother-baby pancreatoscopy [66,67,70], while it was required in 38%–93% of SpyGlass cases [65,69].
- ▶ Mild to moderate pancreatitis following POPS was reported in 0–17% of cases [65,67,68,70]; one death due to pancreatitis and respiratory failure has been reported [65].
- ▶ Various endoscopic features associated with malignancy at pancreatoscopy have been described. In the largest series published to date, protruding lesions were classified into five groups according to their appearance at POPS, and this allowed discrimination of malignant from benign IPMNs with an accuracy of 88% for main duct IPMNs and 67% for branch duct IPMNs [66]. Recently developed video pancreatoscopes with NBI allow better identification of malignant IPMN features, such as small protrusions and vessels [67]. The role of NBI-

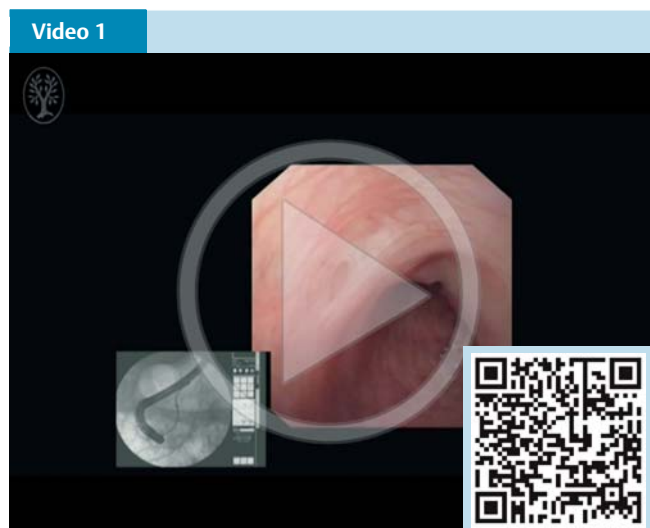
assisted pancreatoscopy needs to be evaluated in large series (▶ **Video 1**).

- ▶ Pancreatoscopy can be useful to assess main duct IPMN extent preoperatively: a few cases of POPS-aided identification of the excision margins have been reported [67,69], and a technique for a “POPS guided tattoo” may be developed in the near future. Intraoperative pancreatoscopy has been reported in a few cases; it seemed effective in identifying the resection margins [71] and in discovering skip lesions along the main pancreatic duct [72].

A prospective study of 44 patients with IPMN found that POPS affected clinical decision-making in 76% of cases, improving diagnosis accuracy compared to multidetector CT scan [65]. In the case of surgery for IPMN, the utility of preoperative POPS/IDUS versus peroperative frozen sections has not been compared.

Indeterminate strictures of the main pancreatic duct

Distinct duct patterns have been associated with main pancreatic duct strictures of various etiologies: coarse mucosa with friability and tumor vessels in the case of cancer; smooth stenosis without significant mucosal changes in the case of benign stricture. However, in a study that included 115 pancreatoscopy attempts, the area of interest in the main pancreatic duct could be visualized in only 56% of pancreatic cancers that were >2 cm [59]. This poor visualization rate resulted from difficulties in obtaining a frontal view of lesions >2 cm, that typically cause a long, asymmetrical, main pancreatic duct stenosis. In the same study, visualization rates for pancreatic cancers >2 cm, benign strictures, and IPMN were 75%, 80%, and 95%, respectively. Although the accuracy of POPS has not been reported in this indication, POPS might help to characterize indeterminate main pancreatic duct strictures in a few highly selected cases with inconclusive findings from EUS-guided fine needle aspiration (FNA), as suggested by different non-controlled series [59,60,73].



Pancreatoscopy with a mother-baby scope enabled preoperative diagnosis of ductal lesions in a patient with main duct IPMN. The pancreatoscope is advanced in the pancreatic duct after pancreatic sphincterotomy over the guidewire. The pancreatic duct appears normal in the head and body. The pancreatic duct appears abnormal near the cystic portion of the caudal duct: the same part of the duct is analyzed with narrow band imaging mode, enhancing abnormal vessels. Online content including video sequences viewable at: <http://dx.doi.org/10.1055/s-0034-1392584>

Sampling

Tissue sampling during POPS is technically difficult because of the limited maneuverability of the biopsy forceps in the pancreatic ducts. Recently, a few series with new pancreatoscopes and ultrathin forceps have reported the performance of pancreatic ductal biopsies under direct visualization by POPS, but data are too limited to assess the accuracy of sampling for histopathological examination [58,65].

Cytopathological examination of pancreatic juice collected during POPS, although rarely performed in Western countries, may be more useful, in particular in patients with IPMN. In a study that included 102 patients with surgically resected IPMN [74], pancreatic juice adequate for cytological diagnosis could be collected in 99% of patients. Sensitivity for the diagnosis of malignant IPMN was significantly higher if the pancreatic juice had been collected through POPS while observing the lesion, or from a position close to the lesion, compared with collection using a catheter (68% vs. 38%, respectively). Sensitivity was much lower for the diagnosis of non-IPMN pancreatic cancer (25%). Collection of pancreatic juice for cytopathological examination should be considered if POPS is performed in a patient with IPMN, in particular if EUS-FNA sampling has been non-contributive, for example because of the high viscosity of the mucus.

Therapeutic applications

Intraductal lithotripsy in patients with chronic pancreatitis

In a study that included 46 patients [75], intraductal lithotripsy was performed if a catheter could be passed upstream from obstructive main pancreatic duct stones at POPS; extracorporeal shockwave lithotripsy (ESWL) was recommended in the remaining cases. The number of stones treated by intraductal lithotripsy ranged from 2 to 4, and their median size was 8 mm; in 12 patients (26%), the stones were located in the head only. A mean of 2 POPS sessions were required to remove stones. Complete stone clearance from the main pancreatic duct was reported in 70% of patients. As ESWL is a well-established modality for removing main pancreatic duct stones that provides similar results, the role of intraductal lithotripsy will only be better defined when further studies become available.

Complications and limitations

After diagnostic and therapeutic POPS in large series, complications were reported in 10%–12% of patients and mostly consisted of mild pancreatitis [59,75].

Anatomical factors may limit the success of POPS, namely tortuous, narrow, or strictured ducts as well as obstructing stones or, in the case of IPMN, tumor location in the branch ducts [76]. The global visualization rate of the area of interest in large series reached 70%–80%, depending on the indication, as outlined in the section on indeterminate main pancreatic duct strictures. A minimum main pancreatic duct diameter of 5 mm is advocated by some authors as a requirement before POPS is attempted.

Conclusion

POPS has mostly been used in selected patients with main duct IPMN, chronic pancreatitis, or indeterminate main pancreatic duct strictures following EUS-FNA. A promising indication for POPS can be the preoperative delineation of main duct IPMN.

Intraductal ultrasonography

Introduction

Intraductal ultrasonography (IDUS) was first described in 1992. It consists of real-time ultrasonographic imaging of the biliary or pancreatic duct using a thin caliber ultrasonic probe (Table 6). High frequencies are used with IDUS, conferring high resolution at the cost of limited penetration depth (29 mm and 18 mm with the 12-MHz and 20-MHz probes, respectively).

Table 6 Ultrasound miniprobe features.

Manufacturer	Probe working length, m	Probe diameter, mm	Probe frequencies, MHz
Olympus	2.14–2.20	2–2.9	12, 15, 20, 30
Fujinon	1.70–2.20	2.6	7.5, 12, 15, 20

Equipment and technique

IDUS is performed using a thin caliber ultrasonic probe consisting of a sheath catheter, transducer, and cable. The use of wire-guided IDUS probes is strongly advised because they can be inserted without biliary sphincterotomy in virtually all cases (and without dilation in many biliary strictures). The mechanical rotation of the transducer provides a cross-sectional image of the structures around the probe (Fig. 5). An ultrasound scan is performed at least twice from the hepatic hilum to the papilla of Vater alongside the guidewire or from the tail of the pancreas to the head. Fluoroscopic control is required for precise control of probe location.

Three-dimensional IDUS (3D-IDUS) has emerged as an interesting alternative to two-dimensional IDUS [77]. Probes that allow 3D-IDUS have an immobile outer sheath and an mobile inner radial transducer; they must be connected to a specific driving unit.

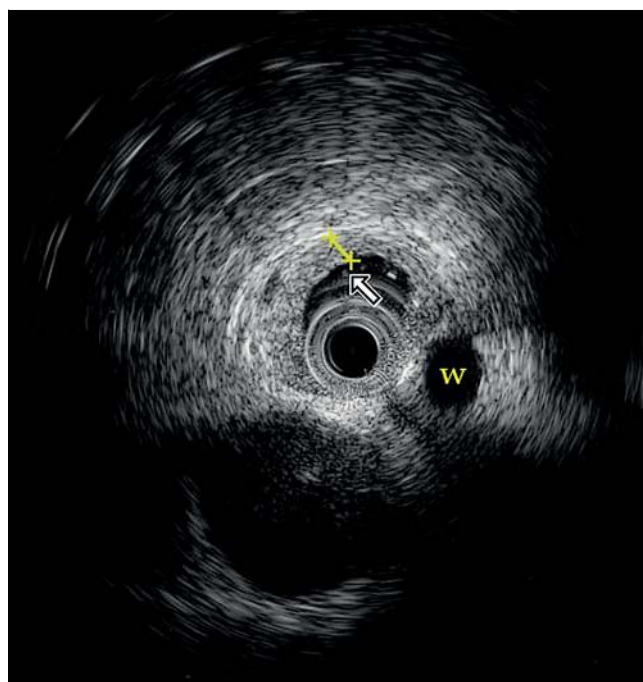


Fig. 5 Intraductal ultrasound. The 20-MHz miniprobe shows a diffuse thickening of the common bile duct (arrow) secondary to cholangiocarcinoma (infiltrating type). W, duct of Wirsung.

After insertion of the probe up to the hilum, the driving unit is activated, and this withdraws the ultrasonic transducer inside the immobile outer sheath at a constant speed. Reconstructions may be provided in real time. Electronic storage of data allows, together with standardization of the procedure, the interpretation of 3D-IDUS images after completion of the ERCP, for example by an experienced echoendoscopist even if he/she did not attend the procedure.

Indications

Choledocholithiasis

IDUS presents a high diagnostic yield for bile duct stones. In a prospective comparative study, the sensitivities of magnetic resonance cholangiopancreatography (MRCP), ERCP, and IDUS for identifying choledocholithiasis were 80.0%, 90.0%, and 95.0%, respectively [78]. IDUS can differentiate stones (echogenic foci with acoustic shadowing) from air bubbles (echoic foci with reverberation artefacts) and biliary sludge (echogenic foci without acoustic shadowing).

Studies have attempted to delineate indications where IDUS could be most useful. Stones that are small (<8 mm) and located in a large CBD (>12 mm) are the most likely to be missed at ERCP and detected at IDUS, as shown in a retrospective study [79]. Therefore, the authors suggested that patients at high risk of having CBD stones but with negative ERCP findings should be selected for IDUS (rather than performance of biliary sphincterotomy or withdrawal of an inflated balloon in the CBD if no stone is evidenced).

Evaluation of patients with idiopathic recurrent pancreatitis is another possible indication for IDUS. In a prospective study, this technique allowed identification of a cause of idiopathic recurrent pancreatitis in 42% of 31 patients; the cause was mostly CBD stones not detected at ERCP [80]. A limitation of that study was the absence of EUS prior to IDUS.

Another potential indication for IDUS in biliary stone disease is the verification of stone clearance after supposedly complete stone extraction at ERCP [81–83]. In a nonrandomized comparative study that involved 188 patients [84], 59 patients had IDUS at the end of ERCP with supposedly complete CBD stone extraction; 24% of them had small residual stones not seen on cholangiography and these stones were extracted. At 3-year follow-up, CBD stone recurrence was detected in 3.4% of these patients compared with 13.2% of historical controls who had no IDUS ($P < 0.05$).

Bile duct strictures

IDUS is highly accurate in distinguishing between benign and malignant biliary strictures [85] (Table 7). Even though it does not provide a pathological diagnosis, IDUS is more accurate than ERCP with transpapillary biopsies in distinguishing between benign and malignant strictures: in a retrospective study that compared IDUS versus combined ERCP/biliary sampling in 30 patients, IDUS presented a higher diagnostic accuracy than ERCP (90% vs. 67%), a higher specificity (92% vs. 42%) and a similar sensitivity (89% vs. 83%) [86]. Compared with EUS in a prospective study of 56 patients with indeterminate bile duct strictures, IDUS was more accurate (89% vs. 75%), more sensitive (91% vs. 75%), and more specific (80% vs. 75%). This difference was related to the proximal location and/or to the small size of some tumors that make EUS assessment difficult [87]. The superiority of IDUS compared with EUS was confirmed by another group of authors in a series of 30 patients [88]. Finally, a large retrospective study that included 234 patients with an indeterminate biliary

Table 7 Intraductal ultrasonography (IDUS) performance in the diagnosis of bile duct stenosis of uncertain etiology in a series of 397 patients [85].

Tumor	Sensitivity, %	Specificity, %	Accuracy, %
Cholangiocarcinoma	98	98	92
Pancreatic cancer	94	90	91
Ampullary cancer	81	90	89

stricture (136 of them with a final diagnosis of malignancy) confirmed these data: accuracies for the diagnosis of malignancy were IDUS 91%, transpapillary biopsy 59%, and EUS 74% [89].

IDUS features identified as independently associated with a malignant diagnosis, in a prospective study of 62 patients with an indeterminate biliary stricture, were: (i) presence of a sessile tumor (intraductal or outside of the bile duct); (ii) tumor size greater than 10.0 mm; and (iii) interrupted wall structure [90]. If none of these three features were present, the negative predictive value of IDUS for malignancy was close to 90%. On the other hand, when IDUS showed two or three of these features, a final diagnosis of malignancy was made in 97% of cases. Therefore, patients with two or three IDUS features predictive of malignancy should be managed as having a malignancy even if preoperative pathological findings are benign.

Finally, as IDUS is limited by the lack of pathological diagnosis, some investigators have performed IDUS-directed biopsy sampling (with the IDUS probe and a biopsy forceps introduced together in the working channel of the duodenoscope). Using this approach, a higher sensitivity for cancer diagnosis was obtained with IDUS-guided biopsy (87%) in comparison with fluoroscopically guided biopsy (67%) of indeterminate biliary strictures [91]. New techniques are being developed to facilitate IDUS-guided bile duct biopsy.

For T staging of cholangiocarcinoma, the accuracy of IDUS is superior to that of EUS, with the greatest difference noted for tumors located at the hilum [87]. Tamada et al. reported, in pioneer studies using various types of probes (7.5, 15, 20, and 30 MHz), a very high accuracy for T staging and for the diagnosis of vascular invasion (T staging, 82%; portal vein invasion, 100%; right hepatic artery invasion, 100%) [92]. These results were confirmed by other authors who reported accuracies close to 90% for the assessment of pancreas and portal vein invasion (the portal vein and the right hepatic artery are the most frequently invaded vessels, while the left and common hepatic arteries are less frequently invaded) [93]. Compared with angiography, IDUS yielded slightly better results for the assessment of hepatic artery and portal vein invasion (nonsignificant differences) [92]. Resectability is better predicted by IDUS than by EUS [87].

For N staging, IDUS presents a lower accuracy than EUS, even if this is not complemented with FNA (43% vs. 63%, respectively; $P < 0.05$). Because of the limited penetration depth of IDUS, this technique is currently considered to be unreliable for complete lymph node assessment [87,94]. EUS coupled with FNA of lymph nodes is more useful for this purpose [95].

The longitudinal extent of cholangiocarcinomas is a critical factor for the planning of surgical resection. IDUS coupled with biopsy sampling is likely the best technique currently available to assess this parameter. In a prospective study of 19 patients with a cholangiocarcinoma, investigated by IDUS immediately after biliary cannulation, longitudinal spread was correctly assessed by IDUS in 84% of the cases versus 47% with ERC ($P < 0.05$) [96]. Other studies have reported slightly less favorable results, in particular

with 3D-IDUS [97]. To overcome the shortcomings of IDUS, some authors have recently proposed the combination of IDUS with transpapillary biopsy sampling. In a prospective study of 44 patients with a cholangiocarcinoma investigated preoperatively, the longitudinal tumor extent was correctly assessed by IDUS on the hepatic and duodenal sides in, respectively, 77% and 61% of cases. In the same patients, the corresponding figures with IDUS plus biopsy sampling were 93% and 82%, respectively (both P values <0.05) [98].

Pancreatic malignancy

Although pancreatic adenocarcinomas located in the vicinity of biliopancreatic ducts may be visualized by IDUS, this technique is inferior to EUS for the diagnosis and staging of pancreatic cancer because of its low penetration depth.

With respect to IPMN, IDUS has been used to differentiate benign from malignant IPMNs and to guide the extent of surgical resection:

- ▶ Some old series reported that IDUS had the highest accuracy among several imaging techniques (including CT, EUS, and POPS) for distinguishing benign from malignant IPMNs [66, 99]. Nevertheless EUS, not IDUS, is currently recommended in the consensus guidelines for the management of IPMN [64]. Disadvantages of IDUS compared with EUS include the necessity to deeply cannulate the main pancreatic duct, the absence of sampling, and its low penetration depth that impedes discrimination between in situ and invasive carcinoma.
- ▶ A randomized controlled trial allocated 40 patients to standard pancreatic imaging either complemented or not with IDUS to guide the extent of surgical resection [100]. For patients allocated to complementary IDUS, the diagnostic accuracy for tumor extent of IPMN was 85% compared with 50% for controls ($P<0.05$). In a retrospective study of 24 patients with branch duct IPMN who were subjected to surgical resection, the extent of lateral spreading along the main pancreatic duct (defined as the detection of papillary protrusions within the main pancreatic duct beyond the area of the branch duct IPMN) was accurately assessed by IDUS in 92% of patients [101]. Lateral spreading was observed in patients with a main pancreatic duct of diameter ≥ 6 mm, who probably represent the population most likely to benefit from preoperative IDUS.

The usefulness of IDUS should be compared with that of intraoperative examination of frozen sections of the surgical margins, using a standardized definition of positive resection margins, before definitive recommendations may be made [102].

Cancer/adenoma of the papilla of Vater

In a study that included 72 patients with a suspected ampullary tumor, IDUS had sensitivity, specificity, and accuracy for the diagnosis of ampullary carcinoma of 87.5%, 92.5% and 90.2%, respectively [103]. IDUS accuracy for T staging was in the range 71%–86%. For N staging, accuracy was 75%. Biopsy sampling had a lower sensitivity for the diagnosis of ampullary carcinoma (68%), so the authors suggested that IDUS should be combined with biopsy sampling to predict the cases in which endoscopic treatment is potentially feasible. However the possible applications of IDUS in both adenomas and papillary cancers have not been established.

Complications and limitations

IDUS has been reported to be an independent risk factor for post-ERCP pancreatitis (hazard ratio 2.41, 95%CI 1.33–1.49) in a series that included 2364 ERCP procedures [104]; in this series minip-

robes were used without wire guidance, which might have contributed to the high rate of pancreatitis. In an older series of 239 patients who underwent IDUS of the pancreas, only one case of acute pancreatitis was reported, an incidence of 0.4% [105]. The main limitations of IDUS include costs, limited durability of the probe, limited penetration depth, and difficulty in evaluating intrahepatic ducts.

Conclusion

Indications for IDUS have not yet been established. This technique competes with EUS but it provides lower accuracy for the staging of pancreatic malignancies and no sampling capability. The most promising role for IDUS could be found in the evaluation of indeterminate biliary strictures and of ampullary tumors.

Confocal laser endomicroscopy



Introduction

Probe-based confocal laser endomicroscopy (pCLE) provides in vivo real-time, magnification of the mucosal layer, from a single cross-sectional plane perpendicular to the probe. A microscope transmits laser light is transmitted through a miniprobe and a distal lens sequentially scans the biliary epithelium in order to construct an image (● Fig. 6); images are displayed at 9–12 frames per second. The technique is currently available from a single company (Mauna Kea Technologies, Paris, France) [106].

Equipment and technique

The laser scanning unit may be connected to various probes. In the biliopancreatic ducts, two probes, namely the CholangioFlex and the GastroFlex probes, have been used. Microscopic images are obtained by placing the tip of the probe in contact with the duct wall, under fluoroscopic guidance or direct vision. Intravenous injection of 10% fluorescein sodium (1.0–5.0 ml) provides contrast that permits examination within approximately 10 s and for 30–45 min. Topical application of cresyl violet has been abandoned in this indication. To obtain high quality images, the probe is maintained in a stable position, as perpendicular as possible to the duct wall, avoiding trauma because bleeding may decrease image quality. The characteristics of the two probes are as follows:

- ▶ The CholangioFlex measures 0.96 mm in diameter; it may be inserted into the biliary or pancreatic ducts through a catheter or through the working channel of a cholangioscope. The probe presents a radiopaque tip; it provides a magnification of $\times 400$ with a depth of imaging from the surface of the confocal lens of 40–70 μm . The lateral resolution is 3.5 μm and the total field of view of an image is 325 \times 325 μm .
- ▶ The GastroFlex presents a higher lateral resolution (1 μm) but it is larger (diameter 2.6 mm) and must be inserted into the CBD using the freehand technique, usually alongside a guide-wire. Use of the Gastroflex in the bile duct has been reported by only a few authors, because it does not respond to movements of the duodenoscope erector [107].

Interpretation criteria

The Miami Classification consists of 18 criteria used as a standardized terminology for describing pCLE findings in the biliary as well as the pancreatic ducts; it has been developed on the basis of consensus by six investigators [108, 109]. Five of these criteria, namely the detection of white bands $>20\mu\text{m}$, of dark

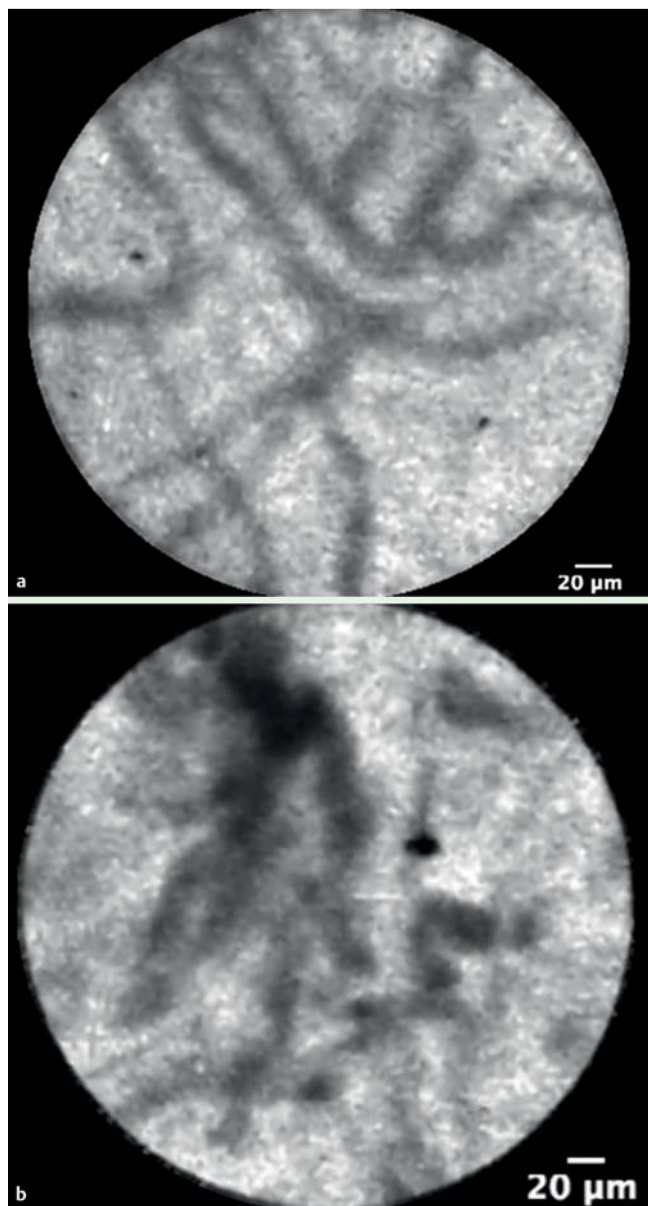


Fig. 6 Confocal biliary endomicroscopy. **a** Normal bile duct epithelium (reticular network with thin dark branching band <20 µm). **b** Malignant cholangiocarcinoma (reticular structure with thick dark band)

bands >40 µm, of dark clumps, of epithelial structures, or of fluorescein leakage, have been retained as indicative of malignancy. Using the presence of two among the five criteria cited above as indicative of malignancy, the authors reported sensitivity and specificity for the diagnosis of malignancy of 97% and 33%, respectively, in a review of 112 pCLE videos from 47 patients [109].

In order to increase specificity for the diagnosis of malignant biliary strictures, an additional series of criteria for inflammatory changes has been proposed in the refined Paris Classification [110]. This latter classification was prospectively validated in a recent multicenter study involving 112 patients with indeterminate biliary strictures [111]; when pCLE findings were added to ERCP assessment, the sensitivity slightly increased from 84% to 89%, while sensitivity for tissue sampling alone was 56% ($P < 0.01$).

Diagnostic performance of pCLE for the characterization of biliary strictures

The feasibility of pCLE is high: in two large series that enrolled 222 patients with successful ERCP, pCLE was technically successful in 214 patients (96%) [108, 111].

The diagnostic performance of pCLE for the characterization of indeterminate biliary or biliopancreatic strictures has been reported in three large series (each >50 patients) that evaluated 256 patients [108, 111, 112]. The accuracy for diagnosing malignant stricture was remarkably similar across studies (79%–82%), while sensitivity and specificity were 89%–98% and 67%–77%, respectively. Another study specifically assessed pCLE for the characterization of pancreatic strictures only: pCLE interpretation provided results similar to cytology/histopathology for 15 of 16 patients [113]. With respect to the impact of biliary stenting on diagnostic accuracy, a study reported that diagnostic accuracy was lower (73% vs. 87%) in patients who had biliary stenting or cholangitis prior to pCLE compared with patients with no biliary stenting/cholangitis beforehand [112]. These results need to be confirmed as the difference was not significant (P value 0.42 [two-tailed Fisher exact test]).

The impact of pCLE on management was assessed in one of the abovementioned large studies of biliopancreatic strictures: the endoscopists stated that they would refer the patients to surgery because pCLE confirmed malignancy in 12 of 89 cases (13%) [108]. Another study dedicated to main pancreatic duct strictures reported that pCLE had changed scheduled management, from total pancreatectomy to a Whipple procedure, in four of 18 patients [113]. An additional potential benefit of pCLE that has not been assessed is that it may allow better targeting of biopsy sampling.

Reproducibility

Two studies have focused on this topic. In the first study [114], video clips of indeterminate biliary strictures were sent to 6 observers at 5 institutions, 3 of whom had experience with <10 cases. Observers were asked whether each of the five malignancy criteria of the Miami Classification were met or not met, and for their final diagnosis. Interobserver agreement was classified as poor, slight, fair, moderate, substantial, or almost perfect. For all items, agreement was poor to fair, and the final diagnosis had the second worst result ($\kappa = 0.149$). Using a similar methodology, the authors then showed that a single teaching session improved interobserver agreement as well as diagnostic accuracy (from 72% to 89%). Again, most observers had little prior experience with the technique [115].

Complications

The technique appears relatively safe as no pCLE-related complications have been reported in the three abovementioned large series [108, 111, 112]. With respect to fluorescein, it may rarely cause serious adverse events such as myocardial infarction, anaphylaxis, and seizure. A survey of 16 centers monitoring the short-term safety of fluorescein for CLE procedures ($n = 2272$) found no serious adverse events. All patients experienced yellowish skin discoloration for 1–2 h, and mild adverse events occurred in 1.4% of cases (transient hypotension, injection site erythema, diffuse rash) [116].

Conclusion

In summary, pCLE in the biliopancreatic ducts is a promising technique that urgently requires confirmation with regard to rapid learning, diagnostic accuracy, and reproducibility by independent investigators, and also requires cost-benefit analysis.

ESGE technology reviews represent a consensus of best practice based on the available evidence at the time of preparation. They are not rules and should not be construed as establishing a legal standard of care or as encouraging, advocating, requiring, or discouraging any particular treatment.

Competing interests: Andrea Tringali: consulting agreement, speaking and teaching for Boston Scientific. Jürgen Pohl: consultant for Karl Storz, Boston Scientific, Walz Electronic, and research support from Fujifilm. Guido Costamagna: consultant for Olympus, Cook Inc., and Boston Scientific. Horst Neuhaus: consultant for Olympus, Cook Inc., Boston Scientific, and Fujifilm. Fabrice Caillol consultant for Mauna-Kea. Marc Giovannini consultant for Pentax and Cook Inc. Arnaud Lemmers, Volker Meves, Grischa Terheggen, Guido Manfredi, Michael Häfner, Jacques Devière, Cesare Hassan, and Jean Marc Dumonceau: nothing to disclose.

Institutions

¹ Digestive Endoscopy Unit, Catholic University, Rome, Italy

² Department of Gastroenterology, Hepatopancreatology and Digestive Oncology, Erasme University Hospital, Brussels, Belgium

³ Department of Gastroenterology and Interventional Endoscopy, Klinikum Friedrichshain, Berlin, Germany

⁴ Department of Internal Medicine, Evangelisches Krankenhaus, Düsseldorf, Germany

⁵ Department of Gastroenterology, Maggiore Hospital, Crema, Italy

⁶ Department of Internal Medicine, St. Elisabeth Hospital, Vienna, Austria

⁷ Endoscopy Unit, Paoli-Calmettes Institute, Marseille, France

⁸ Department of Gastroenterology, Nuovo Regina Margherita Hospital, Rome, Italy

⁹ Gedyt Endoscopy Center, Buenos Aires, Argentina

Acknowledgments

The authors thank Paola Cesaro for her help in writing the section on confocal laser endomicroscopy.

References

- 1 Takekoshi T, Takagi K. Retrograde pancreatocholangioscopy [in Japanese with English abstract]. *Gastroenterol Endosc* 1975; 17: 678–683
- 2 Dumonceau JM, Hassan C, Riphaus A et al. European Society of Gastrointestinal Endoscopy (ESGE) Guideline Development Policy. *Endoscopy* 2012; 44: 626–629
- 3 Itoi T, Osanai M, Igarashi Y et al. Diagnostic peroral video cholangioscopy is an accurate diagnostic tool for patients with bile duct lesions. *Clin Gastroenterol Hepatol* 2010; 8: 934–938
- 4 Ueki T, Mizuno M, Ota S et al. Carbon dioxide insufflation is useful for obtaining clear images of the bile duct during peroral cholangioscopy (with video). *Gastrointest Endosc* 2010; 71: 1046–1051
- 5 Doi S, Yasuda I, Nakashima M et al. Carbon dioxide insufflation vs. conventional saline irrigation for peroral video cholangioscopy. *Endoscopy* 2011; 43: 1070–1075
- 6 Siddique I, Galati J, Ankoma-Sey V et al. The role of choledochoscopy in the diagnosis and management of biliary tract diseases. *Gastrointest Endosc* 1999; 50: 67–73
- 7 Fukuda Y, Tsuyuguchi T, Sakai Y et al. Diagnostic utility of peroral cholangioscopy for various bile-duct lesions. *Gastrointest Endosc* 2005; 62: 374–382
- 8 Nishikawa T, Tsuyuguchi T, Sakai Y et al. Comparison of the diagnostic accuracy of peroral video-cholangioscopic visual findings and cholangioscopy-guided forceps biopsy findings for indeterminate biliary lesions: a prospective study. *Gastrointest Endosc* 2013; 77: 219–226
- 9 Osanai M, Itoi T, Igarashi Y et al. Peroral video cholangioscopy to evaluate indeterminate bile duct lesions and preoperative mucosal cancerous extension: a prospective multicenter study. *Endoscopy* 2013; 45: 635–642
- 10 Itoi T, Sofuni A, Itokawa F et al. Evaluation of peroral videocholangioscopy using narrow-band imaging for diagnosis of intraductal papillary neoplasm of the bile duct. *Dig Endosc* 2009; 21: 103–S107
- 11 Parsi MA, Jang S, Sanaka M et al. Diagnostic and therapeutic cholangiopancreatography: performance of a new digital cholangioscope. *Gastrointest Endosc* 2014; 79: 936–942
- 12 Arya N, Nelles SE, Haber GB et al. Electrohydraulic lithotripsy in 111 patients: a safe and effective therapy for difficult bile duct stones. *Am J Gastroenterol* 2004; 99: 2330–2334
- 13 Piraka C, Shah RJ, Awadallah NS et al. Transpapillary cholangioscopy-directed lithotripsy in patients with difficult bile duct stones. *Clin Gastroenterol Hepatol* 2007; 5: 1333–1338
- 14 Swahn F, Edlund G, Enochsson L et al. Ten years of Swedish experience with intraductal electrohydraulic lithotripsy and laser lithotripsy for the treatment of difficult bile duct stones: an effective and safe option for octogenarians. *Surg Endosc* 2010; 24: 1011–1016
- 15 Tsuyuguchi T, Sakai Y, Sugiyama H et al. Long-term follow-up after peroral cholangioscopy-directed lithotripsy in patients with difficult bile duct stones, including Mirizzi syndrome: an analysis of risk factors predicting stone recurrence. *Surg Endosc* 2011; 25: 2179–2185
- 16 Jakobs R, Pereira-Lima JC, Schuch AW et al. Endoscopic laser lithotripsy for complicated bile duct stones: is cholangioscopic guidance necessary? *Arq Gastroenterol* 2007; 44: 137–140
- 17 Sethi A, Chen YK, Austin GL et al. ERCP with cholangiopancreatography may be associated with higher rates of complications than ERCP alone: a single-center experience. *Gastrointest Endosc* 2011; 73: 251–256
- 18 Igarashi Y, Okano N, Ito K et al. Effectiveness of peroral cholangioscopy and narrow band imaging for endoscopically diagnosing the bile duct cancer. *Dig Endosc* 2009; 21: 101–S102
- 19 Parsi MA, Stevens T, Collins J et al. Utility of a prototype peroral video cholangioscopy system with narrow-band imaging for evaluation of biliary disorders (with videos). *Gastrointest Endosc* 2011; 74: 1148–1151
- 20 Chen YK, Parsi MA, Binmoeller KF et al. Single-operator cholangioscopy in patients requiring evaluation of bile duct disease or therapy of biliary stones (with videos). *Gastrointest Endosc* 2011; 74: 805–814
- 21 Chen YK, Pleskow DK. SpyGlass single-operator peroral cholangiopancreatography system for the diagnosis and therapy of bile-duct disorders: a clinical feasibility study (with video). *Gastrointest Endosc* 2007; 65: 832–841
- 22 Draganov PV, Chauhan S, Wagh MS et al. Diagnostic accuracy of conventional and cholangioscopy-guided sampling of indeterminate biliary lesions at the time of ERCP: a prospective, long-term follow-up study. *Gastrointest Endosc* 2012; 75: 347–353
- 23 Hartman DJ, Slivka A, Giusto DA et al. Tissue yield and diagnostic efficacy of fluoroscopic and cholangioscopic techniques to assess indeterminate biliary strictures. *Clin Gastroenterol Hepatol* 2012; 10: 1042–1046
- 24 Kalaitzakis E, Webster GJ, Oppong KW et al. Diagnostic and therapeutic utility of single-operator peroral cholangioscopy for indeterminate biliary lesions and bile duct stones. *Eur J Gastroenterol Hepatol* 2012; 24: 656–664
- 25 Manta R, Frazzoni M, Conigliaro R et al. SpyGlass® single-operator peroral cholangioscopy in the evaluation of indeterminate biliary lesions: a single-center, prospective, cohort study. *Surg Endosc* 2012; 27: 1569–1572
- 26 Ramchandani M, Reddy DN, Gupta R et al. Role of single-operator peroral cholangioscopy in the diagnosis of indeterminate biliary lesions: a single-center, prospective study. *Gastrointest Endosc* 2011; 74: 511–519
- 27 Dumonceau J-M. Sampling at ERCP for cyto- and histopathological examination. *Gastrointest Endosc Clin N Am* 2012; 22: 461–477
- 28 Sethi A, Widmer J, Shah NL et al. Interobserver agreement for evaluation of imaging with single operator choledochoscopy: what are we looking at? *Dig Liver Dis* 2014; 46: 518–522
- 29 Mou S, Waxman I, Chennat J. Peroral cholangioscopy in Roux-en-Y hepaticojejunostomy anatomy by using the SpyGlass Direct Visualization System (with video). *Gastrointest Endosc* 2010; 72: 458–460

- 30 Navaneethan U, Venkatesh PGK, Al Mohajer M et al. Successful diagnosis and management of biliary cast syndrome in a liver transplant patient using single operator cholangioscopy. *JOP* 2011; 12: 461–463
- 31 Maydeo A, Kwek BEA, Bhandari S et al. Single-operator cholangioscopy-guided laser lithotripsy in patients with difficult biliary and pancreatic ductal stones (with videos). *Gastrointest Endosc* 2011; 74: 1308–1314
- 32 Madhoun MF, Wani S, Hong S et al. Endoscopic papillary large balloon dilation reduces the need for mechanical lithotripsy in patients with large bile duct stones: a systematic review and meta-analysis. *Diagn Ther Endosc* 2014; 2014: 309618
- 33 Dumonceau JM, Delhaye M, Tringali A et al. Endoscopic treatment of chronic pancreatitis: European Society of Gastrointest Endosc (ESGE) Clinical Guideline. *Endoscopy* 2012; 44: 784–800
- 34 Wright H, Sharma S, Gurakar A et al. Management of biliary stricture guided by the Spyglass Direct Visualization System in a liver transplant recipient: an innovative approach. *Gastrointest Endosc* 2008; 67: 1201–1203
- 35 Barkay O, Bucksot L, Sherman S. Endoscopic transpapillary gallbladder drainage with the SpyGlass cholangiopancreatography system. *Gastrointest Endosc* 2009; 70: 1039–1040
- 36 Ransibrahmanakul K, Hasyagar C, Prindiville T. Removal of bile duct foreign body by using spyglass and spybite. *Clin Gastroenterol Hepatol* 2010; 8: e9
- 37 Kantsevov SV, Frolova EA, Thuluvath PJ. Successful removal of the proximally migrated pancreatic winged stent by using the SpyGlass visualization system. *Gastrointest Endosc* 2010; 72: 454–455
- 38 Moon JH, Ko BM, Choi HJ et al. Intraductal balloon-guided direct peroral cholangioscopy with an ultraslim upper endoscope (with videos). *Gastrointest Endosc* 2009; 70: 297–302
- 39 Pohl J. Direct cholangioscopy with standard ultraslim endoscopes for electrohydraulic lithotripsy of an incarcerated large bile duct stone. *Video Journal and Encyclopedia of GI Endoscopy* 2013. DOI 10.1016/S2212-0971(13)70200-0
- 40 Parsi MA, Stevens T, Vargo JJ. Diagnostic and therapeutic direct peroral cholangioscopy using an intraductal anchoring balloon. *World J Gastroenterol* 2012; 18: 3992–3996
- 41 Choi HJ, Moon JH, Ko BM et al. Overtube-balloon-assisted direct peroral cholangioscopy by using an ultra-slim upper endoscope (with videos). *Gastrointest Endosc* 2009; 69: 935–940
- 42 Meves V, Ell C, Pohl J. Efficacy and safety of direct transnasal cholangioscopy with standard ultraslim endoscopes: results of a large cohort study. *Gastrointest Endosc* 2014; 79: 88–94
- 43 Albert JG, Friedrich-Rust M, Elhendawy M et al. Peroral cholangioscopy for diagnosis and therapy of biliary tract disease using an ultra-slim gastroscope. *Endoscopy* 2011; 43: 1004–1009
- 44 Pohl J, Ell C. Direct transnasal cholangioscopy with ultraslim endoscopes: a one-step intraductal balloon-guided approach. *Gastrointest Endosc* 2011; 74: 309–316
- 45 Pohl J, Meves VC, Mayer G et al. Prospective randomized comparison of short-access mother-baby cholangioscopy versus direct cholangioscopy with ultraslim gastroscopes. *Gastrointest Endosc* 2013; 78: 609–616
- 46 Moon J, Ko B, Choi H et al. Direct peroral cholangioscopy using an ultra-slim upper endoscope for the treatment of retained bile duct stones. *Am J Gastroenterol* 2009
- 47 Pohl J, Ell C. Direct cholangioscopy: new horizons for complex intraductal treatments under direct high-resolution visualization. *Gastroenterology* 2013; 144: 270–271
- 48 Brauer BC, Fukami N, Chen YK. Direct cholangioscopy with narrow-band imaging, chromoendoscopy, and argon plasma coagulation of intraductal papillary mucinous neoplasm of the bile duct (with videos). *Gastrointest Endosc* 2008; 67: 574–576
- 49 Park DH, Park BW, Lee HS et al. Peroral direct cholangioscopic argon plasma coagulation by using an ultraslim upper endoscope for recurrent hepatoma with intraductal nodular tumor growth (with videos). *Gastrointest Endosc* 2007; 66: 201–203
- 50 Lee YN, Moon JH, Choi HJ et al. Direct biliary drainage using transnasal endoscopy for patients with severe-to-moderate acute cholangitis. *J Gastroenterol Hepatol* 2013; 28: 739–743
- 51 Waxman I, Chennat J, Konda V. Peroral direct cholangioscopic-guided selective intrahepatic duct stent placement with an ultraslim endoscope. *Gastrointest Endosc* 2010; 71: 875–878
- 52 Demaerel P, Gevers A-M, De Bruecker Y et al. Stroke caused by cerebral air embolism during endoscopy. *Gastrointest Endosc* 2003; 57: 134–135
- 53 Efthymiou M, Raftopoulos S, Antonio Chirinos J et al. Air embolism complicated by left hemiparesis after direct cholangioscopy with an intraductal balloon anchoring system. *Gastrointest Endosc* 2012; 75: 221–223
- 54 Finsterer J, Stöllberger C, Bastovansky A. Cardiac and cerebral air embolism from endoscopic retrograde cholangio-pancreatography. *Eur J Gastroenterol Hepatol* 2010; 22: 1157–1162
- 55 Waxman I, Dillon T, Chmura K et al. Feasibility of a novel system for intraductal balloon-anchored direct peroral cholangioscopy and endotherapy with an ultraslim endoscope (with videos). *Gastrointest Endosc* 2010; 72: 1052–1056
- 56 Kodama T, Sato H, Horii Y et al. Pancreatoscopy for the next generation: development of the peroral electronic pancreatoscope system. *Gastrointest Endosc* 1999; 49: 366–371
- 57 Kodama T, Tatsumi Y, Sato H et al. Initial experience with a new peroral electronic pancreatoscope with an accessory channel. *Gastrointest Endosc* 2004; 59: 895–900
- 58 Brauer BC, Chen YK, Ringold DA et al. Peroral pancreatoscopy via the minor papilla for diagnosis and therapy of pancreatic diseases. *Gastrointest Endosc* 2013; 78: 545–549
- 59 Yamao K, Ohashi K, Nakamura T et al. Efficacy of peroral pancreatoscopy in the diagnosis of pancreatic diseases. *Gastrointest Endosc* 2003; 57: 205–209
- 60 Kodama T, Koshitani T, Sato H et al. Electronic pancreatoscopy for the diagnosis of pancreatic diseases. *Am J Gastroenterol* 2002; 97: 617–622
- 61 Cheon Y, Moon J, Choi H et al. Direct peroral pancreatoscopy with an ultraslim endoscope for the evaluation of intraductal papillary mucinous neoplasms. *Endoscopy* 2012; 43: E390–E391
- 62 Prachayakul V, Aswakul P, Kachintorn U. Overtube-assisted direct peroral pancreatoscopy using an ultraslim gastroscope in a patient suspected of having an intraductal papillary mucinous neoplasm. *Endoscopy* 2011; 43: E279–E280
- 63 Sung K-F, Chu Y-Y, Liu N-J et al. Direct peroral cholangioscopy and pancreatoscopy for diagnosis of a pancreatobiliary fistula caused by an intraductal papillary mucinous neoplasm of the pancreas: a case report. *Dig Endosc* 2011; 23: 247–250
- 64 Tanaka M, Fernandez-del Castillo C, Adsay V et al. International consensus guidelines 2012 for the management of IPMN and MCN of the pancreas. *Pancreatol* 2012; 12: 183–197
- 65 Arnelo U, Siiki A, Swahn F et al. Single-operator pancreatoscopy is helpful in the evaluation of suspected intraductal papillary mucinous neoplasms (IPMN). *Pancreatol* 2014; 14: 510–514
- 66 Hara T, Yamaguchi T, Ishihara T et al. Diagnosis and patient management of intraductal papillary-mucinous tumor of the pancreas by using peroral pancreatoscopy and intraductal ultrasonography. *Gastroenterology* 2002; 122: 34–43
- 67 Miura T, Igarashi Y, Okano N et al. Endoscopic diagnosis of intraductal papillary-mucinous neoplasm of the pancreas by means of peroral pancreatoscopy using a small-diameter videoscope and narrow-band imaging. *Dig Endosc* 2010; 22: 119–123
- 68 Mukai H, Yasuda K, Nakajima M. Differential diagnosis of mucin-producing tumors of the pancreas by intraductal ultrasonography and peroral pancreatoscopy. *Endoscopy* 1998; 30: A99–A102
- 69 Nagayoshi Y, Aso T, Ohtsuka T et al. Peroral pancreatoscopy using the SpyGlass system for the assessment of intraductal papillary mucinous neoplasm of the pancreas. *J Hepatobiliary Pancreat Sci* 2014: 410–417
- 70 Yasuda K, Sakata M, Ueda M et al. The use of pancreatoscopy in the diagnosis of intraductal papillary mucinous tumor lesions of the pancreas. *Clin Gastroenterol Hepatol* 2005; 3: 53–55
- 71 Kaneko T, Nakao A, Nomoto S et al. Intraoperative pancreatoscopy with the ultrathin pancreatoscope for mucin-producing tumors of the pancreas. *Arch Surg* 1998; 133: 263–267
- 72 Yelamali A, Mansard MJ, Dama R et al. Intraoperative pancreatoscopy with narrow band imaging: a novel method for assessment of resection margins in case of intraductal papillary mucinous neoplasm. *Surg Endosc* 2012; 26: 3682–3685
- 73 Uehara H, Nakaizumi A, Tatsuta M et al. Diagnosis of carcinoma in situ of the pancreas by peroral pancreatoscopy and pancreatoscopic cytology. *Cancer* 1997; 79: 454–461

- 74 Yamaguchi T, Shirai Y, Ishihara T et al. Pancreatic juice cytology in the diagnosis of intraductal papillary mucinous neoplasm of the pancreas: significance of sampling by peroral pancreatoscopy. *Cancer* 2005; 104: 2830–2836
- 75 Attwell AR, Brauer BC, Chen YK et al. Endoscopic retrograde cholangiopancreatography with per oral pancreatoscopy for calcific chronic pancreatitis using endoscope and catheter-based pancreatoscopes: a 10-year single-center experience. *Pancreas* 2014; 43: 268–274
- 76 Yamaguchi T, Hara T, Tsuyuguchi T et al. Peroral pancreatoscopy in the diagnosis of mucin-producing tumors of the pancreas. *Gastrointest Endosc* 2000; 52: 67–73
- 77 Frossard JL, Dumonceau JM. The role of EUS in the biliary system. In: VM Shami VM, Kahaleh M eds *Endoscopic ultrasound*. New York: Humana Press; 2010: 371–390
- 78 Moon JH, Cho YD, Cha S-W et al. The detection of bile duct stones in suspected biliary pancreatitis: comparison of MRCP, ERCP, and intraductal US. *Am J Gastroenterol* 2005; 100: 1051–1057
- 79 Endo T, Ito K, Fujita N et al. Intraductal ultrasonography in the diagnosis of bile duct stones: when and whom? *Dig Endosc* 2011; 23: 173–175
- 80 Kim HS, Moon JH, Choi HJ et al. The role of intraductal US in the management of idiopathic recurrent pancreatitis without a definite cause on ERCP. *Gastrointest Endosc* 2011; 73: 1148–1154
- 81 Das A, Isenberg G, Wong RC et al. Wire-guided intraductal US: an adjunct to ERCP in the management of bile duct stones. *Gastrointest Endosc* 2001; 54: 31–36
- 82 Tamada K, Ohashi A, Tomiyama T et al. Comparison of intraductal ultrasonography with percutaneous transhepatic cholangioscopy for the identification of residual bile duct stones during lithotripsy. *J Gastroenterol Hepatol* 2001; 16: 100–103
- 83 Catanzaro A, Pfau P, Isenberg GA et al. Clinical utility of intraductal US for evaluation of choledocholithiasis. *Gastrointest Endosc* 2003; 57: 648–652
- 84 Tsuchiya S, Tsuyuguchi T, Sakai Y et al. Clinical utility of intraductal US to decrease early recurrence rate of common bile duct stones after endoscopic papillotomy. *J Gastroenterol Hepatol* 2008; 23: 1590–1595
- 85 Meister T. Intraductal ultrasound substantiates diagnostics of bile duct strictures of uncertain etiology. *World J Gastroenterol* 2013; 19: 874
- 86 Vazquez-Sequeiros E, Baron TH, Clain JE et al. Evaluation of indeterminate bile duct strictures by intraductal US. *Gastrointest Endosc* 2002; 56: 372–379
- 87 Menzel J, Poremba C, Dietl KH et al. Preoperative diagnosis of bile duct strictures—comparison of intraductal ultrasonography with conventional endosonography. *Scand J Gastroenterol* 2000; 35: 77–82
- 88 Domagk D, Wessling J, Conrad B et al. Which imaging modalities should be used for biliary strictures of unknown aetiology? *Gut* 2007; 56: 1032
- 89 Heinzow HS, Kammerer S, Rammes C et al. Comparative analysis of ERCP, IDUS, EUS and CT in predicting malignant bile duct strictures. *World J Gastroenterol* 2014; 20: 10495–10503
- 90 Tamada K, Tomiyama T, Wada S et al. Endoscopic transpapillary bile duct biopsy with the combination of intraductal ultrasonography in the diagnosis of biliary strictures. *Gut* 2002; 50: 326–331
- 91 Jong Ho M. The usefulness of IDUS-guided transpapillary bile duct biopsy for the diagnosis of malignant biliary strictures. *Endoscopy* 2011; 43
- 92 Tamada K, Ido K, Ueno N et al. Assessment of hepatic artery invasion by bile duct cancer using intraductal ultrasonography. *Endoscopy* 1995; 27: 579–583
- 93 Inui K, Miyoshi H, Yoshino J. Bile duct cancers: what can EUS offer? Intraductal US, 3D-IDUS? FNA – is it possible? *Endoscopy* 2006; 38: 47–549
- 94 Tamada K, Ido K, Ueno N et al. Preoperative staging of extrahepatic bile duct cancer with intraductal ultrasonography. *Am J Gastroenterol* 1995; 90: 239–246
- 95 Gleeson F, Rajan E, Levy M et al. EUS-guided FNA of regional lymph nodes in patients with unresectable hilar cholangiocarcinoma. *Gastrointest Endosc* 2008; 67: 438–443
- 96 Tamada K, Nagai H, Yasuda Y et al. Transpapillary intraductal US prior to biliary drainage in the assessment of longitudinal spread of extrahepatic bile duct carcinoma. *Gastrointest Endosc* 2001; 53: 300–307
- 97 Inui K, Yoshino J, Okushima K et al. Intraductal EUS. *Gastrointest Endosc* 2002; 56: 58–S62
- 98 Noda Y, Fujita N, Kobayashi G et al. Prospective study of intraductal ultrasonography before biliary drainage (IDUS-BD), transpapillary biopsy (TPB) and peroral cholangioscopy (POCS) in assessment of the longitudinal extent of bile duct cancer. *Gastrointest Endosc* 2008; 67: AB156–AB157
- 99 Cellier C, Cuillerier E, Palazzo L et al. Intraductal papillary and mucinous tumors of the pancreas: accuracy of preoperative computed tomography, endoscopic retrograde pancreatography and endoscopic ultrasonography, and long-term outcome in a large surgical series. *Gastrointest Endosc* 1998; 47: 42–49
- 100 Cheon YK, Cho YD, Jeon SR et al. Pancreatic resection guided by preoperative intraductal ultrasonography for intraductal papillary mucinous neoplasm. *Am J Gastroenterol* 2010; 105: 1963–1969
- 101 Kobayashi G, Fujita N, Noda Y et al. Lateral spread along the main pancreatic duct in branch-duct intraductal papillary-mucinous neoplasms of the pancreas: usefulness of intraductal ultrasonography for its evaluation. *Dig Endosc* 2011; 23: 62–68
- 102 Painsi M, Crippa S, Scopelliti F et al. Extent of surgery and implications of transection margin status after resection of IPMNs. *Gastroenterol Res Pract* 2014; 2014: 1–10
- 103 Heinzow HS, Lenz P, Lallier S et al. Ampulla of Vater tumors: impact of intraductal ultrasound and transpapillary endoscopic biopsies on diagnostic accuracy and therapy. *Acta Gastroenterol Belg* 2011; 74: 509–515
- 104 Meister T, Heinzow H, Heinecke A et al. Post-ERCP pancreatitis in 2364 ERCP procedures: is intraductal ultrasonography another risk factor? *Endoscopy* 2011; 43: 331–336
- 105 Furukawa T, Oohashi K, Yamao K et al. Intraductal ultrasonography of the pancreas: development and clinical potential. *Endoscopy* 1997; 29: 561–569
- 106 Committee AT. Confocal laser endomicroscopy. *Gastrointest Endosc* 2014; 80: 928–938
- 107 Loeser CS, Robert ME, Mennone A et al. Confocal endomicroscopic examination of malignant biliary strictures and histologic correlation with lymphatics. *J Clin Gastroenterol* 2011; 45: 246–252
- 108 Meining A, Chen YK, Pleskow D et al. Direct visualization of indeterminate pancreaticobiliary strictures with probe-based confocal laser endomicroscopy: a multicenter experience. *Gastrointest Endosc* 2011; 74: 961–968
- 109 Meining A, Shah R, Slivka A et al. Classification of probe-based confocal laser endomicroscopy findings in pancreaticobiliary strictures. *Endoscopy* 2012; 44: 251–257
- 110 Caillol F, Filoche B, Gaidhane M et al. Refined probe-based confocal laser endomicroscopy classification for biliary strictures: the Paris Classification. *Dig Dis Sci* 2013; 58: 1784–9
- 111 Slivka A, Gan I, Jamidar P et al. Validation of the diagnostic accuracy of probe-based confocal laser endomicroscopy for the characterization of indeterminate biliary strictures: results of a prospective multicenter international study. *Gastrointest Endosc* 2015; 81: 282–290
- 112 Caillol F, Bories E, Autret A et al. Evaluation of pCLE in the bile duct: final results of EMID study: pCLE: impact in the management of bile duct strictures. *Surg Endosc* 2014; Dec 10 [Epub ahead of print]
- 113 Kahaleh M, Turner BG, Bezak K et al. Probe-based confocal laser endomicroscopy in the pancreatic duct provides direct visualization of ductal structures and aids in clinical management. *Dig Liver Dis* 2015; 47: 202–204
- 114 Talreja JP, Sethi A, Jamidar PA et al. Interpretation of probe-based confocal laser endomicroscopy of indeterminate biliary strictures: is there any interobserver agreement? *Dig Dis Sci* 2012; 57: 3299–3302
- 115 Talreja JP, Turner BG, Gress FG et al. Pre- and post-training session evaluation for interobserver agreement and diagnostic accuracy of probe-based confocal laser endomicroscopy for biliary strictures. *Dig Endosc* 2014; 26: 577–580
- 116 Wallace MB, Meining A, Canto MI et al. The safety of intravenous fluorescein for confocal laser endomicroscopy in the gastrointestinal tract. *Aliment Pharmacol Ther* 2010; 31: 548–552