

Colonoscopy through appendectomy in a colonic stenosis

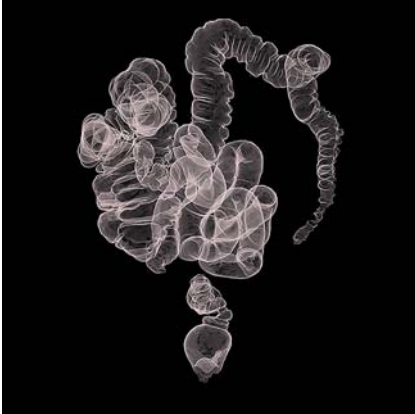

Fig. 1 Computed tomographic colonography shows colonic stenosis in a 58-year-old man presenting with acute diarrhea and a positive fecal occult blood (FOB) test result.

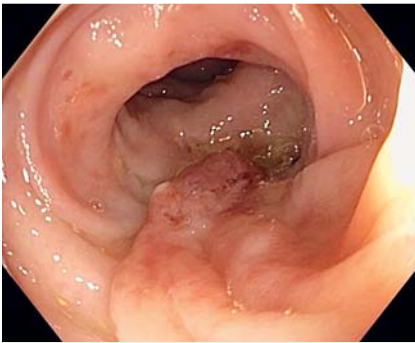


Fig. 3 Sigmoid colon polyp.

Colonoscopy is the standard method used for exploring the colon to remove polyps. However, a percentage of the colonoscopic procedures performed cannot be completed for various reasons, such as the presence of a stenosis [1,2]. Computed tomographic colonography has proved to be very useful in cases in which a colonoscopy cannot be completed, but a drawback is that therapy is not possible [3].

A 58-year-old man was referred to our hospital because of acute diarrhea and a positive fecal occult blood (FOB) test result. He had an infantile pelvic fibrosarcoma, treated with surgery and radiotherapy, and a posteriorly placed neurostimulator.

A colonoscopy was performed, during which two polyps (tubulovillous adenomas) were removed, but the colonoscope could not pass the sigmoid colon because

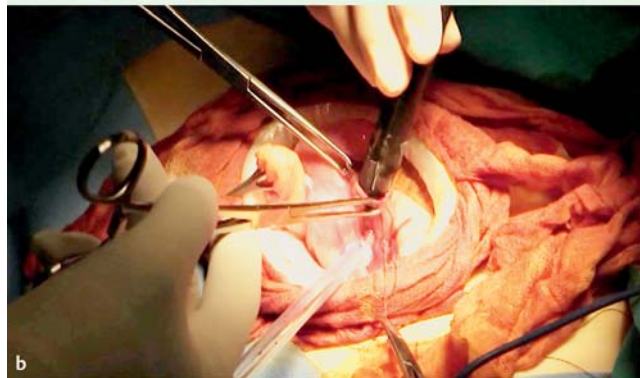
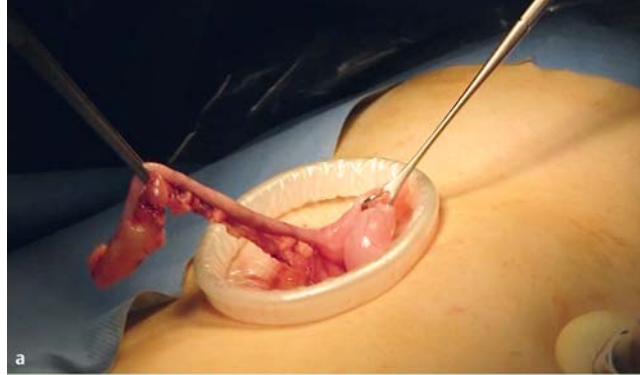


Fig. 2 Colonoscopy through appendectomy to avoid colonic segmental resection. **a** The appendix. **b** The colonoscope is introduced through the appendectomy.

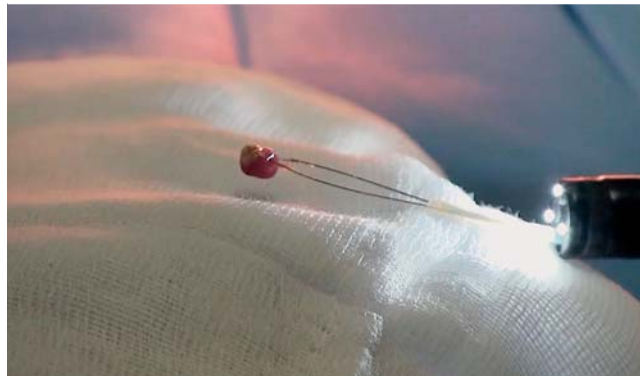
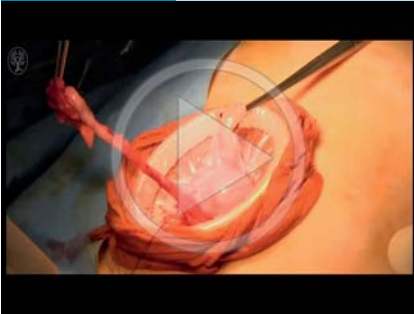


Fig. 4 A resected polyp.

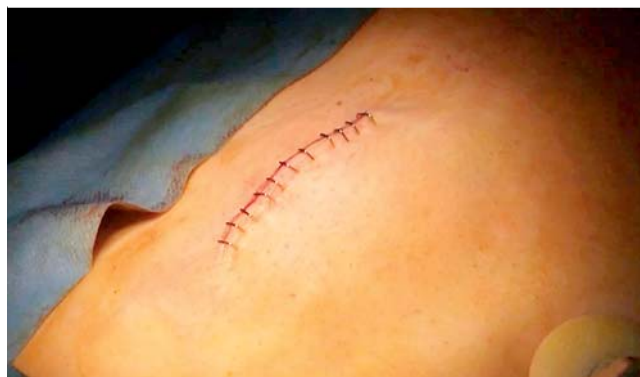

Fig. 5 Surgical suture, following a standard uncomplicated appendectomy.

Video 1



Colonoscopy through appendectomy.

of the presence of stenosis and diverticula. Computed tomographic colonography showed stenosis of the colon and two additional polyps, one in the ileocecal valve and the other in the splenic flexure. These polyps were 7 and 5 mm in size, respectively (▶ Fig. 1).

The patient underwent two more colonoscopic procedures in which a thinner endoscope was used, but the stenosis still could not be passed. Therefore, he was referred to surgery and was advised that a colonoscopy could be carried out through an appendectomy, so as to avoid colonic segmental resection.

An appendectomy was performed, through which the colonoscope was introduced (▶ Fig. 2) and reached the sigmoid colon. The existing polyps were removed: those previously seen on computed tomographic colonography (tubular adenomas) and one in the sigmoid colon (tubulovillous adenoma) (▶ Fig. 3, ▶ Fig. 4, ▶ Video 1).

After a normal, uncomplicated appendectomy (▶ Fig. 5), the patient was finally discharged.

Endoscopy_UCTN_Code_TTT_1AQ_2AD

Competing interests: None

Fernando Sábado^{1,4}, Jesús Nomdedeu², Pablo Aragón², Daniel Ahicart³, Beatriz Castelló¹, Antonio Peris¹

¹ Department of Gastroenterology, Consorcio Hospitalario Provincial de Castellón, Castellón de la Plana, Spain

² Department of Gastrointestinal Surgery, Consorcio Hospitalario Provincial de Castellón, Castellón de la Plana, Spain

³ Department of Radiology, Consorcio Hospitalario Provincial de Castellón, Castellón de la Plana, Spain

⁴ Department of Gastroenterology, University CEU Cardenal Herrera, Castellón de la Plana, Spain

References

- 1 Gawron AJ, Veerappan A, McCarthy ST et al. Impact of an incomplete colonoscopy referral program on recommendations after incomplete colonoscopy. *Dig Dis Sci* 2013; 58: 1849–1855
- 2 Shah HA, Paszat LF, Saskin R et al. Factors associated with incomplete colonoscopy: a population-based study. *Gastroenterology* 2007; 132: 2297–2303
- 3 Spada C, Stoker J, Alarcon O et al. Clinical indications for computed tomographic colonography: European Society of Gastrointestinal Endoscopy (ESGE) and European Society of Gastrointestinal and Abdominal Radiology (ESGAR) Guideline. *Endoscopy* 2014; 46: 897–915

Bibliography

DOI <http://dx.doi.org/10.1055/s-0034-1392670>
Endoscopy 2015; 47: E415–E416
 © Georg Thieme Verlag KG
 Stuttgart · New York
 ISSN 0013-726X

Corresponding author

Fernando Sábado, MD
 Department of Gastroenterology
 Consorcio Hospitalario Provincial de Castellón
 Av Doctor Clara 19
 Castellón de la Plana 12002
 Spain
 Fax: +34-964-354301
 fersabado@hotmail.com