

# Surgical Methods for the Treatment of Uterine Fibroids – Risk of Uterine Sarcoma and Problems of Morcellation: Position Paper of the DGGG

## Exstirpierende Verfahren zur Behandlung von Uterusmyomen – Uterus-sarkomrisiko und Problematik der Morcellation: Positionspapier der DGGG

### Authors

**M. W. Beckmann** (Uterus Commission of the Gynecological Oncology Working Group [Arbeitsgemeinschaft Gynäkologische Onkologie, AGO]), Guidelines Commissioner of the German Society for Gynecology and Obstetrics [Deutsche Gesellschaft für Gynäkologie und Geburtshilfe, DGGG]<sup>1</sup>, **I. Juhasz-Bösz** (Uterus Commission of the AGO, Gynecological Endoscopy Working Group [Arbeitsgemeinschaft für Gynäkologische Endoskopie, AGE])<sup>2</sup>, **D. Denschlag** (Uterus Commission of the AGO)<sup>3</sup>, **P. Gaß** (Guidelines Secretary of the DGGG)<sup>1</sup>, **T. Dimpfl** (former president of the DGGG)<sup>4</sup>, **P. Harter** (Ovary Commission of the AGO)<sup>5</sup>, **P. Mallmann** (Uterus Commission of the AGO)<sup>6</sup>, **S. P. Renner** (Financing Commission of the DGGG, President of the European Endometriosis League [Europäische Endometriose Liga, EEL])<sup>1</sup>, **S. Rimbach** (AGE)<sup>7</sup>, **I. Runnebaum** (Uterus Commission of the AGO)<sup>8</sup>, **M. Untch** (Federal Association of Leading Physicians in Gynecology and Obstetrics [Bundesarbeitsgemeinschaft Leitender Ärztinnen und Ärzte in der Frauenheilkunde und Geburtshilfe, BLFG])<sup>9</sup>, **S. Y. Brucker** (AGE)<sup>10</sup>, **D. Wallwiener** (President of the DGGG)<sup>10</sup>

### Key words

- uterine sarcoma
- morcellation
- uterine fibroid
- epidemiology
- myomectomy
- hysterectomy

### Schlüsselwörter

- Uterussarkom
- Morcellation
- Uterusmyom
- Epidemiologie
- Myomektomie
- Hysterektomie



Deutschsprachige  
Zusatzinformationen  
online abrufbar unter:  
[www.thieme-connect.de/  
ejournals/toc/gebfra](http://www.thieme-connect.de/ejournals/toc/gebfra)

**received** 6. 1. 2015  
**revised** 9. 1. 2015  
**accepted** 9. 1. 2015

### Bibliography

**DOI** [http://dx.doi.org/  
10.1055/s-0035-1545684](http://dx.doi.org/10.1055/s-0035-1545684)  
Geburtsh Frauenheilk 2015; 75:  
148–164 © Georg Thieme  
Verlag KG Stuttgart · New York ·  
ISSN 0016-5751

### Correspondence

**Dr. Paul Gaß**  
Universitätsklinikum  
Frauenklinik  
Universitätsstraße 21–28  
91054 Erlangen  
[paul.gass@uk-erlangen.de](mailto:paul.gass@uk-erlangen.de)

### Abstract

The appropriate surgical technique to treat patients with uterine fibroids is still a matter of debate as is the potential risk of incorrect treatment if histological examination detects a uterine sarcoma instead of uterine fibroids. The published epidemiology for uterine sarcoma is set against the incidence of accidental findings during surgery for uterine fibroids. International comments on this topic are discussed and are incorporated into the assessment by the German Society for Gynecology and Obstetrics (DGGG). The ICD-O-3 version of 2003 was used for the anatomical and topographical coding of uterine sarcomas, and the “Operations- und Prozedurenschlüssel” (OPS) 2014, the German standard for process codes and interventions, was used to determine surgical extirpation methods. Categorical qualifiers were defined to analyze the data provided by the Robert Koch Institute (RKI), the German Federal Bureau of Statistics (DESTATIS; Hospital and Causes of Death Statistics), the population-based Cancer Register of Bavaria. A systematic search was done of the MEDLINE database and the Cochrane collaboration, covering the period from 1966 until November 2014. The incidence of uterine sarcoma and uterine fibroids in uterine surgery was compared to the literature and with the different registries. The incidence of uterine sarcoma in 2010, standardized for age, was 1.53 for Bavaria, or 1.30 for every 100 000 women, respectively, averaged for the years 2002–2011, and 1.30 for every 100 000 women in Germany. The mean incidence collated from various surveys was 2.02 for every 100 000 women (0.35–7.02; standard deviation 2.01). The numbers of inpatient surgical procedures such as myoma enucleation, morcellation, hysterectomy or cervical stump removal to treat the indication “uterine myoma” have steadily declined in Germany across all age groups (an absolute decrease of 17% in 2012 compared to

### Zusammenfassung

In der Behandlung der Patientin mit Uterus myomatosus gibt es Diskussionen über die Art der Operationstechnik und das damit verbundene Risiko der eventuellen falschen Behandlung, wenn sich in der histologischen Aufarbeitung keine Uterusmyome, sondern ein Uterussarkom herausstellt. Die publizierte Epidemiologie von Uterussarkomen wird hier ins Verhältnis zu Zufallsbefunden bei Operationen zur Behandlung von Uterusmyomen gesetzt. Die internationalen Stellungnahmen zu diesem Thema werden diskutiert, um eine Bewertung seitens der Deutschen Gesellschaft für Gynäkologie und Geburtshilfe (DGGG) abzugeben. Zur anatomischen und topografischen Codierung der Uterussarkome wurde der ICD-O-3 in der Ausgabe von 2003 und für die Operations- und Prozedurenschlüssel der exstirpierenden Verfahren der OPS 2014 benutzt. Um die übermittelten Daten des Robert Koch-Instituts (RKI), des Statistischen Bundesamts (DESTATIS; Abteilung Krankenhausstatistik und Todesursachenstatistik), des bevölkerungsbezogenen Krebsregisters Bayern auswerten zu können, wurden eindeutige Abfragekriterien definiert. Zusätzlich wurde eine systematische Literaturrecherche in MEDLINE von 1966 bis November 2014 und bei der Cochrane Collaboration durchgeführt. Die Inzidenz von Uterussarkomen und Uterusmyomen bei Operationen der Gebärmutter wurden in den verschiedenen Registern und in der Literatur verglichen. Die altersstandardisierte Inzidenz im Jahr 2010 für Uterussarkome war für Bayern 1,53, respektive 1,30 auf 100 000 Frauen gemittelt über die Jahre 2002–2011, in Deutschland bei 1,30 auf 100 000 Frauen. Die mittlere Inzidenz aus verschiedenen Erhebungen beträgt 2,02 auf 100 000 Frauen (0,35–7,02; Standardabweichung 2,01). Stationär durchgeführte Operationen wie Myomenukleation, Morcellation, Hysterektomie oder Zervixstumpfresektion sind

2007). There has been a shift in the preferred method of surgical access from an abdominal/vaginal approach to endoscopic or endoscopically assisted procedures to treat uterine fibroids, with the use of morcellation increasing by almost 11 000 coded procedures in 2012. Based on international statements (AAGL, ACOG, ESGE, FDA, SGO) on the risk of uterine sarcoma as an incidental finding during uterine fibroid surgery and the associated risk of a deterioration of prognosis (in the case of morcellation procedures), this overview presents the opinion of the DGGG in the form of four Statements, five Recommendation and four Demands.

## Introduction

In April 2014 the US Food and Drug Administration (FDA) published a communication entitled “Laparoscopic Uterine Power Morcellation in Hysterectomy and Myomectomy” [1]. Up to this point, no overall opinion or guideline on this topic had ever been issued by an authority, organization or medical society. Prior to this, only the American Society of Gynecologic Oncology (SGO) had briefly commented on the issue in 2013 [2], followed by a more detailed comment [3] after the publication of the FDA communication. After a meeting of the “Obstetrics and Gynecological Medical Device Advisory Panel” in July 2014, the FDA communication of April 2014 was updated in November 2014 [4]. Most recently, the communication concerning the most common surgical procedure to treat benign uterine fibroids led to lively and sometimes controversial global debates [5–8]. In June 2014, one manufacturer of morcellators (Johnson & Johnson, Ethicon Inc.) stopped its “global commercialization [...]” and in August 2014 the company initiated a voluntary worldwide recall [9, 10]. At the beginning of August 2014 the Bundesinstitut für Arzneimittel und Medizinprodukte (BfArM), the Federal Institute for Drugs and Medical Devices responsible for approval and licensing in Germany, sent an official letter of enquiry to the German Society for Gynecology and Obstetrics (Deutsche Gesellschaft für Gynäkologie und Geburtshilfe, DGGG). The Society answered the letter at the end of August, publishing their response on the homepage of the DGGG [11]. The DGGG shares the opinion that, in the interests of patients and users, the Society has an obligation to compile a comprehensive opinion which will also take account of the specifics of Germany’s national healthcare system and the surgical techniques currently used in Germany. In this context, the opinion will also consider the risks and probability of incidental uterine sarcoma; however, this written opinion will not address the potential risk or probability of developing endometrial or cervical cancer subsequent to surgical procedures for the benign indication “uterine leiomyoma”.

## Data Base of the Position Paper

The anatomical classification (uterus) was done using the topographical codes and histological classification (sarcoma) which are based on the morphological codes of the International Classification of Diseases for Oncology, third edition (ICD-O-3), from 2003 [12].

bei der Indikation Uterusmyom in Deutschland gleichbleibend über alle Altersgruppen hinweg zurückgegangen (absoluter Rückgang von 17% im Jahr 2012 zum Jahr 2007). Es zeigt sich eine Verschiebung des operativen Zugangswegs von abdominal/vaginal zu endoskopisch bzw. endoskopisch assistierten zur Behandlung von Uterusmyomen mit einer ansteigenden Benutzung der Morcellation von fast 11 000 codierten Prozeduren im Jahr 2012. Nach den Veröffentlichungen von internationalen Stellungnahmen (AAGL, ACOG, ESGE, FDA, SGO) zum Risiko Uterussarkom als Zufallsbefund im Rahmen einer Myomoperation und dem damit verbundenen Risiko einer Prognoseverschlechterung (im Falle einer Morcellation) wird in dieser Übersichtsarbeit die DGGG-Stellungnahme in Form von 4 Statements, 5 Empfehlungen und 4 Forderungen dargestellt.

The coding of inpatient surgical procedures follows the Operationen- und Prozedurenschlüssel (OPS), the German code set for coding procedures and interventions, in the version from 2014. The codes used in this paper were classified either under the main category or in a subcategory, depending on the question (Table 1) [13].

To retrieve data from the Robert Koch Institute (RKI) and the population-based Cancer Register of Bavaria, 15 specific codes for gynecological sarcomas out of 88 possible codes used to encode sarcomas were selected for histological classification, based on the ICD-O-3 (Table 2). This histological classification was combined with the topographical code set for the affected organ. These include cervical intraepithelial neoplasias (C53.\*), malignant neoplasm of corpus uteri (C54.\*) and malignant neoplasm of uterus, part unspecified (C55.\*).

Data from the Health Statistics and Causes of Death Statistics of the German Federal Bureau of Statistics (DESTATIS), which are based on the DRG (Diagnosis-Related-Groups) Statistics for 2005–2012, was retrieved using a combination of topographical and morphological ICD-10-GM axes as follows: “D25.\* and OPS 2014 (5-681.2\* or 5-681.3\* or 5-681.4 or 5-681.5 or 5-682.\* or 5-683.\* or 5-684.4)” (Table 1). They described the primary surgical procedures carried out following a primary diagnosis of leiomyoma (D25.\*). These were listed according to the respective federal state in Germany, the date of the survey and the age of the patient [13, 14].

**Table 1** OPS codes used in this paper (list only includes main groups).

Code [13]	Designation (main category)	Designation (subcategory)
5-681.2*	Excision and destruction of diseased uterine tissue	<b>Enucleation</b> of a myoma
5-681.3*	Excision and destruction of diseased uterine tissue	Excision of other diseased uterine tissue
5-681.4	Excision and destruction of diseased uterine tissue	<b>Morcellation</b> of the uterus in preparation for extirpation of the uterus
5-681.5	Excision and destruction of diseased uterine tissue	Endometrial ablation
5-682.*	Subtotal extirpation of the uterus	
5-683.*	Total extirpation of the uterus (hysterectomy)	
5-684.4	Cervical stump extirpation	

**Table 2** ICD-O-3 codes used for uterine sarcomas.

Code [2]	Designation
8800/3	Sarcoma NOS
8805/3	Undifferentiated sarcoma
8890/3	Leiomyosarcoma, NOS
8891/3	Epithelioid leiomyosarcoma
8895/3	Myosarcoma
8896/3	Myxoid leiomyosarcoma
8900/3	Rhabdomyosarcoma, NOS
8901/3	Pleomorphic rhabdomyosarcoma, adult type
8910/3	Embryonal rhabdomyosarcoma
8930/3	Endometrial stromal sarcoma, NOS
8931/3	Endometrial stromal sarcoma, low grade
8933/3	Adenosarcoma
8935/3	Stromal sarcoma, NOS
8950/3	Mullerian mixed tumor
8980/3	Carcinosarcoma, NOS

A systematic keyword-based literature search was done in MEDLINE. The query searched for English or French abstracts and full publications between 1966 and November 2014 on uterine sarcomas after morcellation, hysterectomy or myomectomy procedures. The search algorithm was “((uterine sarcoma AND morcellation) OR (uterine sarcoma AND hysterectomy) OR (uterine sarcoma AND myomectomy) OR (Fibroids[MeSH] and morcellation) OR (Fibroids[MeSH] AND myomectomy) OR (Fibroids[MeSH] AND hysterectomy)) AND (“1966/01/01”[Date – Publication]; “2014/11/30”[Date – Publication])”. An additional search was done of the Cochrane Database or Library in November 2014 looking for the terms “sarcoma” or “morcellation” or “hysterectomy” or “myomectomy”.

### Basics of Uterine Sarcomas

The German S1 Guideline (AWMF registry number 015-074) on “Uterine Sarcomas” will soon be published. The Guideline will give a detailed overview of the basics of uterine sarcomas including epidemiology, diagnostics, classifications, therapy and fol-

low-up [15]. The statements quoted below in this paper are only those relevant for this opinion.

### Epidemiology

The data on the annual incidence of uterine sarcomas in the international literature ranges from 0.35 to 7.02 for every 100 000 women, depending on the investigated cohort (Table 3) [16–20].

Targeted queries of the RKI and the population-based Bavarian Cancer Register found an age-standardized incidence in 2010 (standardized for the European population) of 1.32 per 100 000 women in Germany and of 1.53 per 100 000 women in Bavaria [21]. The mean age-standardized incidence for a longer observation period (between 2002 and 2011) was 1.30 for every 100 000 women in Bavaria [22]. It is known from the literature that the overwhelming majority of the 1164 cases listed for the period 2002–2011 for Bavaria (Table 4) and the 2079 cases recorded for the period 2009–2011 across all of Germany were postmenopausal women [5, 21–23]. This means that more than 80% of women in Bavaria and Germany are older than 50 years when they receive a primary diagnosis of uterine sarcoma (Figs. 1 and 2) [21, 22].

A synopsis of age-standardized incidence rates (European or American population) resulted in a mean value of 2.02 for every 100 000 women (0.35–7.02; standard deviation 2.01) per year (Table 3). The prevalence cannot be ascertained from these individual surveys without matching the data to that from a register of residents or other sources showing changes in populations.

### Risk factors

Risk factors – some of them identified based on very small sample sizes – include age [18, 24], ethnicity [16–18, 25], prior pelvic radiotherapy [26], prior administration of anti-estrogens with partial uterine estrogen effect such as tamoxifen [27–31], and genetic predisposition (Lynch syndrome and others) [32, 33].

### Diagnostics

Despite taking a thorough patient history including the patient’s familial history, carrying out a physical exam and the use of imaging methods (cf. Preoperative Diagnosis), it is not possible to differentiate a myoma from a sarcoma; this can only be done postoperatively during the histopathological workup.

**Table 3** Overview of incidence rates of uterine sarcomas.

Region for which the data was collected	Study design	Date of publication	Period in which data was collected	Cases (n)	Incidence* 100 000/year
USA (SEER) [16]	retrospective	2006	1978 to 2001	26 758 (total) 1 861 (uterus)	0.36
USA (SEER) [17]	retrospective	2004	1989 to 1999	2 677 (uterus)	2.68 to 7.02
USA (SEER) [18]	retrospective	1986	1973 to 1981	1 452 (uterus)	1.90
Norway (Norwegian Cancer Registry) [19]	retrospective	1997	1987 to 1992	1 042 (uterus)	1.70
Europe [20]	retrospective	2012	2005 to 2008	1 558 (total) 107 (uterus)	0.35
Germany [21]	retrospective	2014	2010	813	1.32
Bavaria [21]	retrospective	2014	2010	138	1.53
Bavaria [22]	retrospective	2014	2002 to 2011	1 164	1.30
					<b>2.02 (mean)</b>

\* incidence rate standardized for age (for Europe or USA)

Abbreviation: SEER = Surveillance, Epidemiology, and End Results Program

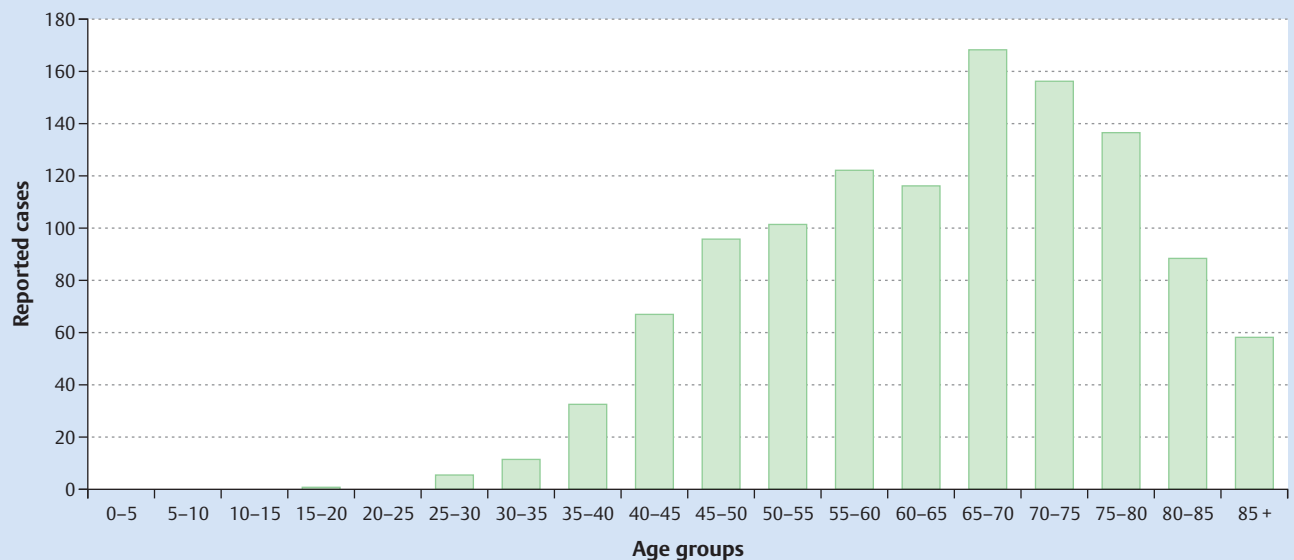


Fig. 1 Age distribution of patients with uterine sarcoma in Bavaria (2002–2011) [22].

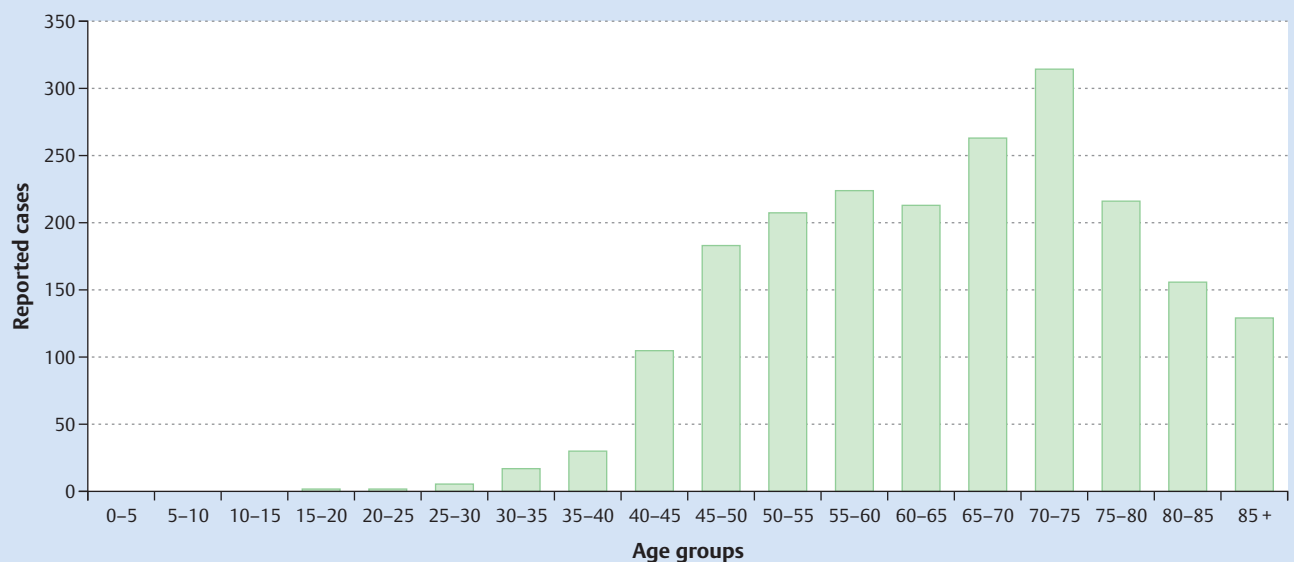


Fig. 2 Age distribution of patients with uterine sarcoma in Germany (2009–2011) [21].

### Histological classification

A sarcoma is a malignant neoplasm which develops in mesenchymal tissue. This heterogeneous tissue can consist of connective tissue, fat tissue, musculature, bones or cartilage. In gynecological oncology, the sarcoma is located in the uterus in 7% of cases [34]. In  $\frac{2}{3}$  of these cases these soft-tissue sarcomas originate in the smooth musculature of the myometrium and take the form of leiomyosarcomas (LMS). The second most common histological type is endometrial stromal sarcoma (ESS), without using the now obsolete differentiation into low-grade and high-grade types. The third most common entity is undifferentiated endometrial stromal sarcoma (UES). Rhabdomyosarcomas originating

from striated muscles or adenosarcomas of the Mullerian ducts are very rare. Carcinosarcomas, better known as malignant Mullerian mixed tumors (MMMT), are no longer classed as belonging to the entity of sarcomas but are now classed as malignancies of epithelial origin, in other word as pure carcinomas [35,36].

### Prognostic factors

The prognosis of patients with uterine sarcomas depends on the sarcoma's histological type. However, there are other factors which do not affect the prognosis quite so strongly (Table 5) [23,35,37–43]. This paper looks particularly at the risk factor “malignant disseminated ‘peritoneal’ iatrogenic tumor cell spread” [44].

**Table 4** Raw data on the incidence of uterine sarcomas (in Bavaria between 2002 and 2011) [14].

Uterine sarcoma* (n)	Population (women)	Year	8800/3	8805/3	8890/3	8891/3	8895/3	8896/3	8900/3	8901/3	8910/3	8930/3	8931/3	8933/3	8935/3	8950/3	8980/3	Raw rate	Alt. rate
87	6313308	2002	9	0	29	1	1	0	0	0	0	15	0	2	6	2	22	1.38	1.0
88	6335520	2003	4	0	31	0	1	0	0	0	0	12	2	5	5	10	18	1.39	1.1
127	6349733	2004	5	0	31	0	0	0	1	0	0	17	2	4	7	21	39	2.0	1.5
120	6360580	2005	5	0	46	0	1	0	1	0	0	14	3	4	6	13	27	1.9	1.4
117	6369876	2006	6	0	44	0	0	0	0	0	0	14	5	0	3	11	34	1.9	1.4
120	6378808	2007	5	0	30	0	0	0	2	0	0	18	6	3	1	23	32	1.9	1.4
97	6382781	2008	4	0	27	1	0	0	0	0	1	10	3	3	3	18	27	1.5	1.1
139	6377977	2009	4	0	27	0	0	0	0	1	1	24	7	4	1	37	33	2.2	1.6
128	6377292	2010	0	2	36	2	0	1	1	0	1	12	6	4	0	34	29	2.0	1.4
141	6388246	2011	0	2	44	1	0	1	1	0	0	13	7	3	2	49	18	2.2	1.5
1164	63634121		42	4	345	5	3	2	6	1	3	149	41	32	34	218	279	1.8	1.3

\* The histological codes refer to the topographical codes C54,\* and C55,\* of the ICD-O-3 [12]

## Treatment strategies

The therapeutic approach depends on the therapeutic setting (curative, palliative). In the curative setting, it is important to differentiate between obligatory surgery and facultative chemotherapy [15].

## Surgery

Irrespective of the sarcoma's histological type, the recommendation must always be surgery with non-preservation of the uterus. In principle, no morcellation should be done during organ removal of any sort because of its potential to worsen prognosis (cf. chapter: Prognostic relevance). Total abdominal hysterectomy is the surgery of choice for LMS, the most common histological type. After weighing up the benefits and risks, bilateral salpingo-oophorectomy (BSO) should always be carried out in premenopausal and postmenopausal women or when surgical findings are normal. Total abdominal hysterectomy, always accompanied with bilateral adnexectomy, is also recommended for ESS, the second most common histological type. The adnexa can be preserved in selected cases with FIGO stage I sarcoma [45]. Systematic pelvic and paraaortal lymphonodectomy is not routinely recommended for LMS and ESS [36,46].

This paper does not cover systemic therapies in the curative and palliative setting.

## Surgical Procedures for Uterine Fibroids

Surgery to treat uterine fibroids can include organ preservation or involve partial or total organ removal [47]. Three different approaches (abdominal, laparoscopic, vaginal) or a combination of the three are used for the surgical treatment of uterine fibroids (Fig. 3) [48].

A German S2k Guideline (AWMF register number 015-070) on "Indications and Methods for Hysterectomy" will also be published in the near future [49]. For this reason, we only present specific data on morcellation.

**Table 5** Overview of potential prognostic factors for uterine sarcomas [23, 35,37–43].

Clinical	Pathological	Therapeutic
<ul style="list-style-type: none"> <li>Age</li> <li>Menopausal status</li> <li>Ethnicity</li> <li>Pregnancies (number)</li> </ul>	<ul style="list-style-type: none"> <li>Histological type</li> <li>Tumor stage</li> <li>Tumor size</li> <li>Myometrial infiltration</li> <li>Nuclear atypia</li> <li>Mitotic index (MI)</li> <li>Tumor cell necrosis (TCN)</li> <li>Hyaline necrosis</li> <li>Lymph node invasion</li> <li>Lymph node involvement</li> <li>Vascular invasion</li> <li>DNA ploidy/proliferation index</li> <li>Expression of estrogen/progesterone/androgen receptors</li> <li>Wilms tumor gene 1 (WT1)</li> </ul>	<ul style="list-style-type: none"> <li>Resection margins after primary surgery</li> <li>Malignant dissemination</li> <li>Ovar-/Adnexectomy</li> <li>Lymphadenectomy</li> <li>Chemotherapy</li> <li>Radiotherapy</li> <li>Anti-hormone therapy</li> </ul>

### Minimally invasive surgical procedures

The most commonly used approach used in Germany since 2010 to remove leiomyomas is a laparoscopic approach: myoma enucleation is done in procedures with organ preservation, and subtotal or total hysterectomy is done in procedures with organ removal (● Fig. 3). Coincidental findings of uterine sarcomas therefore occur most commonly with this approach. Some of the benefits of laparoscopic hysterectomy procedures compared to abdominal hysterectomies have been evaluated and were found to be statistically significant, although they may not be economically and/or clinically relevant:

- ▶ Shorter convalescence time (mean difference [MD] of 13.6 days; 95% CI: 11.8–15.4 days;  $p = 0.004$ ) [50];
- ▶ Lower intraoperative blood loss (MD 45 ml; 95% CI: 17.9–72.7 ml) [50],
- ▶ Fewer postoperative wound infections (odds ratio 0.31; 95% CI: 0.12–0.77) [50],
- ▶ Lower postoperative pain (using the VAS) after 8 h (MD –2.4 VAS; 95% CI: –2.88 to –1.92) and 48 h (MD –1.9 VAS; 95% CI: –2.8 to –1.0) [48],
- ▶ Shorter hospital stay (MD 2 days; 95% CI: 1.9–2.2 days;  $p < 0.00001$ ) [50], and
- ▶ Better cosmesis.

Morcellation is part of the surgical technique. The morcellation of benign tissue reduces the size of the tissue pieces requiring removal, making it easier to retrieve them. Every morcellation leads to destruction of myometrial tissue. Two techniques are currently used:

1. using a scalpel or scissors, or
2. using an electromechanical device (“power morcellation”).

The above listed morcellation techniques can be used in all surgical procedures, irrespective of whether the approach is vaginal, minimally invasive. The technique may be supported using an assisted open approach with a mini-laparotomy for the incision to retrieve the fibroid to avoid a full abdominal incision [51]. The fibroid can be additionally retrieved using a specimen retrieval bag [2, 5].

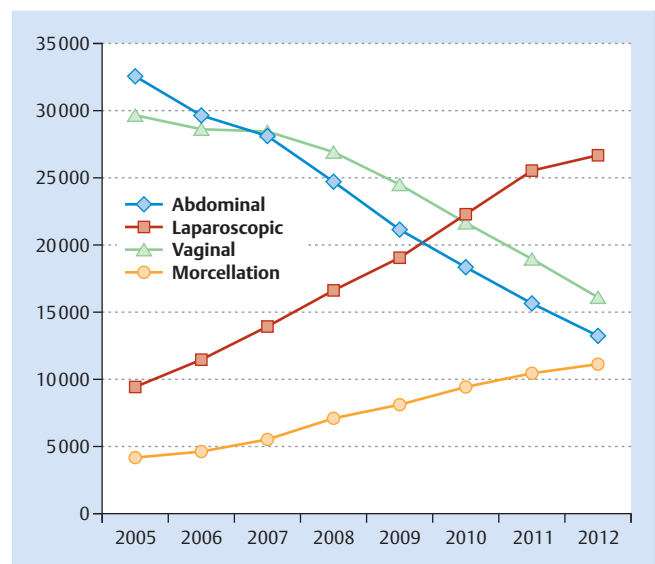
The earliest case describing morcellation was published in 1993; since then, the distribution of minimally invasive surgery has meant that the procedure has become increasingly sophisticated [52, 53]. Associated complications included injuries of the ureters, the bladder and the bowel [54].

### Preservation of the uterus

If the fibroid is removed using an minimally invasive approach with preservation of the uterus, then morcellation of the leiomyoma with preservation of the uterus during laparoscopic or hysteroscopic myomectomy of the abdomen or uterine cavity is indispensable. Supplementary or new wound surfaces are created for laparoscopic retrieval through a secondary abdominal or vaginal incision. Primary abdominal myomectomy to preserve the uterus is indicated in exceptional cases if minimally invasive surgical procedures cannot be used. Hysterotomy with incision of the myometrium occurs even with these abdominal myomectomies, with the potential for sarcoma and tumor cell dissemination.

### Removal of the uterus

Supracervical hysterectomy using a minimally invasive or open approach is indicated for partial – i.e. subtotal – uterus removal. Laparoscopy-assisted supracervical hysterectomy (LASH) in-



**Fig. 3** Total number of surgical procedures\* for uterine fibroids differentiated according to the approach used in the year of data collection (2005–2012) [14]. \* Figures for the number of operated cases were compiled based on the ICD code (D25) and the OPS codes for an abdominal (5-681.20 or 5-682.00 or 5-683.00 or 5-683.10 or 5-683.20 or 5-683.x0), laparoscopic (5-681.22 or 5-682.02 or 5-683.03 or 5-683.13 or 5-683.23 or 5-683.x3) or vaginal (5-681.26 or 5-683.01 or 5-683.11 or 5-683.21 or 5-683.x1) approach. Morcellation (5-681.4) procedures were additionally included for comparison without differentiating for the approach used.

cludes intra-abdominal destruction of myometrial tissue using a morcellator.

Total removal of the uterus can be done using a minimally invasive, open or vaginal approach. If the volume of the uterus is very large vaginal extirpation is often not possible due to the surrounding soft tissue. If vaginal retrieval is possible after total laparoscopic hysterectomy (TLH) or laparoscopy-assisted vaginal hysterectomy (LAVH) procedures intra-abdominal destruction of uterine tissue is often not necessary. Morcellation becomes necessary even vaginal approach is used, if the uterus is too large to the surrounding soft tissue. Use of a morcellator is one option; however, morcellation can also be done using an open vaginal approach.

### Surgery and other procedures to treat uterine fibroids

The data of the DRG statistics was collected for the years 2005–2012. The analysis investigated which preselected operation was used to treat uterine fibroids, grouped according to diagnosis using the main category or the subcategory (cf. ● Table 1) and depending on whether the uterus was preserved or removed.

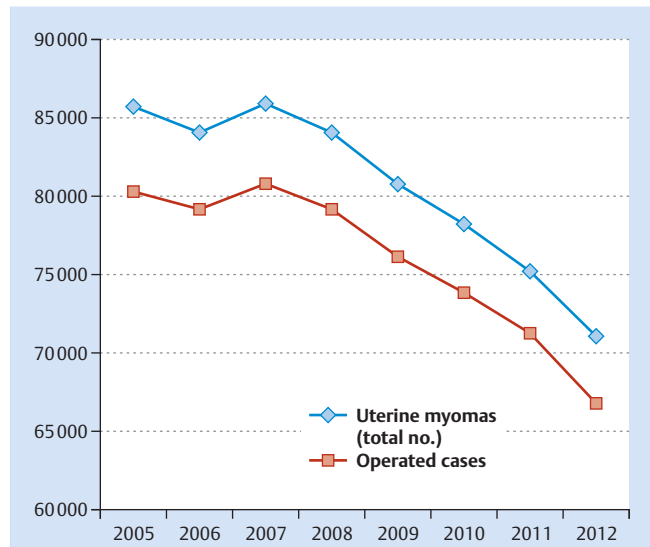
The total number of uterine fibroids coded as ICD-10 D25.\* in women operated as inpatients has continually decreased since 2007 (17% decrease in absolute numbers by 2012). This decrease is not only due to a drop in the specially selected coded surgical procedures. There has also been a reduction in the overall number of myomas classified as ICD-10-GM D25.\*. Either the absolute number of women with uterine leiomyomas has not increased, or surgical procedures are increasingly done on an outpatient basis, meaning that they are coded using a different data entry system. It is not possible to make any statements here about patients operated on an outpatient basis.

The decreased age distribution of patients operated on for uterine fibroids has remained approximately the same during the data collection period 2005–2012 (● Fig. 5) [14].

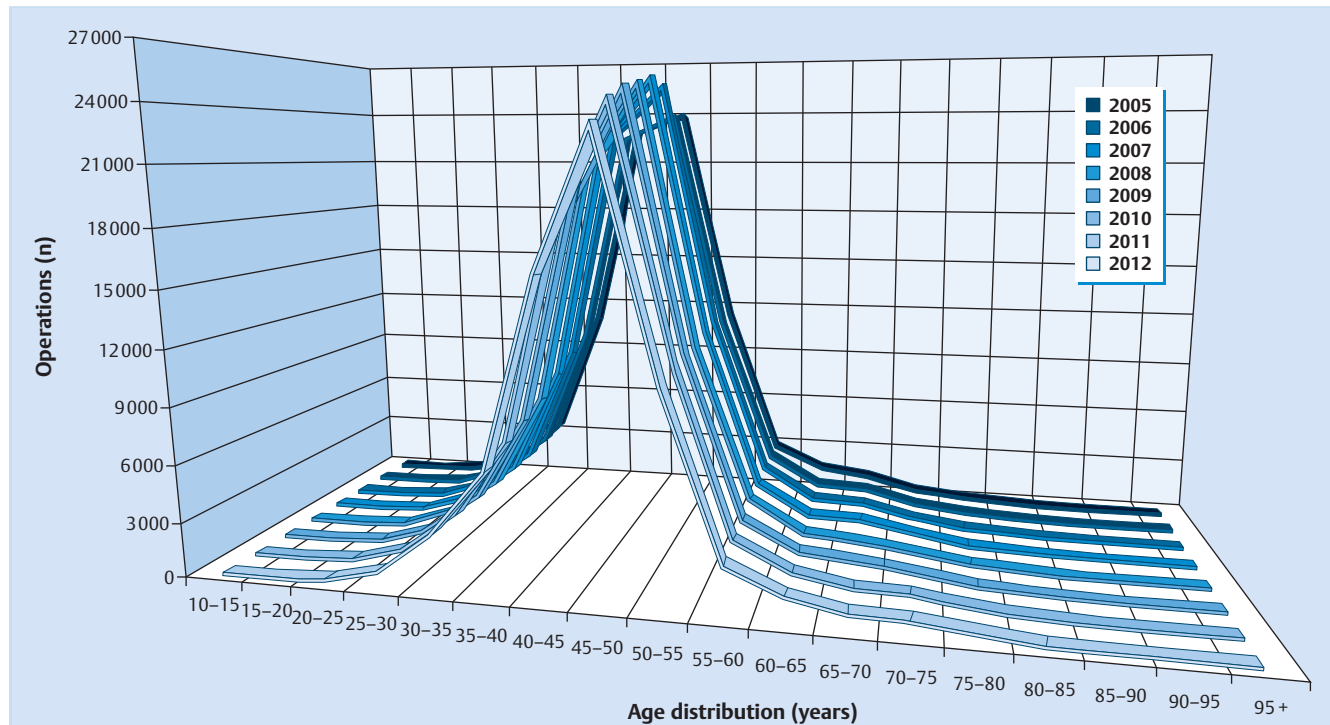
There was a linear correlation between laparoscopic subtotal hysterectomies (5-682.02) and coded morcellation procedures (5-681.4) for the primary diagnosis of uterine fibroids D25.\* (● Fig. 6). A similar correlation was found between total laparoscopic hysterectomy procedures (5-683.03 or 5-683.13 or 5-683.23 or 5-683.x3) and morcellation (5-681.4) (● Fig. 7). No correlation was found for myoma enucleation (5-681.2\*) and approach. In absolute numbers, in 2012, the last year of the survey, morcellation for uterine fibroids was carried out in 10987 cases compared to the year 2005 where the number of coded procedures was 4005; this would correspond to an increase of approximately 175% [14].

**Summary of the Basic Stance of the Position Paper**

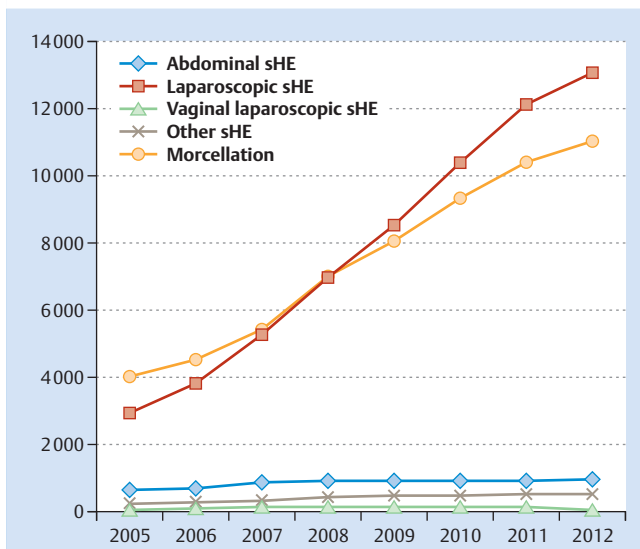
Uterine sarcoma is a very rare malignancy in women. The incidence in Germany in 2010, standardized for age, was 1.32 for every 100 000 women. Known risk factors are age, pelvic irradiation and tamoxifen use. LMS is the most common histological type, followed by ESS and UES. Rhabdomyosarcomas and adenosarcomas are very rare. MMTs are no longer classified as sarcomas but as carcinomas. There are a number of suspected prognostic factors but the scientific evidence for these is ambiguous. Primary treatment for uterine sarcomas in the curative setting should be surgery. The decision for a BSO depends on the patient's age and the histological type. Staging lymphonodectomy is not indicated.



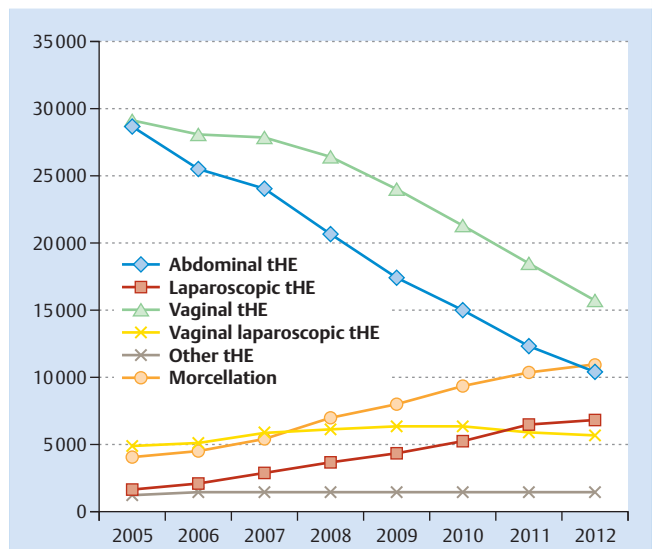
**Fig. 4** Total number of coded uterine fibroids and the chosen surgical procedures\* for every surveyed year (2005–2012) [14]. \* The figures showing the number of operated cases are compiled using the ICD code (D25) together with at least one OPS code (5-681.2\* or 5-681.3\* or 5-681.4 or 5-681.5 or 5-682.\* or 5-683.\* or 5-684.4).



**Fig. 5** Age distribution according to the number of surgical procedures\* carried out for uterine fibroids in every surveyed year (2005–2012) [14]. \* The figures showing the number of operated cases are compiled using the ICD code (D25) combined with at least one OPS code (5-681.2\* or 5-681.3\* or 5-681.4 or 5-681.5 or 5-682.\* or 5-683.\* or 5-684.4).



**Fig. 6** Total number of subtotal hysterectomy procedures\* for uterine fibroids carried out in every surveyed year (2005–2012), differentiated according to the approach [14]. \* The figures showing the number of patients who underwent subtotal hysterectomy (sHE) were compiled using the ICD code (D25) together with the OPS codes for abdominal approach (5-682.00), laparoscopic approach (5-682.02), vaginal laparoscopy-assisted approach (5-682.01) or other approaches (5-682.03 or 5-682.0x or 5-682.12 or 5-682.21 or 5-682.y). Morcellation (5-681.4) without specifying the approach used was additionally included for comparison.



**Fig. 7** Total number of total hysterectomy procedures\* for uterine fibroids carried out in every surveyed year (2005–2012), differentiated according to the approach [14]. \* The figures showing the number of patients who underwent total hysterectomy (tHE) were compiled using the ICD code (D25) and the OPS codes for abdominal approach (5-683.00 or 5-683.10 or 5-683.20 or 5-683.x0), laparoscopic approach (5-683.03 or 5-683.13 or 5-683.23 or 5-683.x3), purely vaginal approach (5-683.01 or 5-683.11 or 5-683.21 or 5-683.x1), vaginal laparoscopic assisted approach (5-683.02 or 5-683.12 or 5-683.22 or 5-683.x2) or other approaches (5-683.04 or 5-683.14 or 5-683.15 or 5-683.24 or 5-683.25 or 5-683.3 or 5-683.x4 or 5-683.y). Morcellation (5-681.4) without specifying the approach used was additionally included for comparison.

Leiomyomas can be treated with different surgical procedures. Procedures are differentiated according to the preferred approach, which can be minimally invasive (endoscopic), open surgical, vaginal, or a combination of these approaches. Surgery can involve preservation of the uterus or uterus removal. A minimally invasive approach can offer significant benefits compared to open surgery. One disadvantage can be the destruction of myometrial tissue through morcellation with an associated risk of malignant dissemination of a uterine sarcoma. In principle, all extirpating procedures used for hysterotomy, whether performed with or without morcellation, involve the risk of disseminating malignant cells in the abdominal cavity.

Analysis of the DRG statistics for the years 2005–2012 obtained from the Federal Bureau of Statistics in Germany showed that the absolute numbers of surgeries for leiomyoma carried out in hospitals have significantly decreased. The age distribution remained constant across all types of operations. Despite this decline in surgical procedures, there was a linear correlation between the increase in the absolute number of morcellations and laparoscopic subtotal and total hysterectomy procedures. As expected, the data showed a shift towards the preferred approach from abdominal/vaginal to endoscopic with a concurrent increase in the number of morcellations.

## Hypothesis

Hysterotomy as single technique and the additional morcellation during hysterectomy or myomectomy is associated with a low probability of iatrogenic spread of a previously unknown, very rare uterine sarcoma. There is a minimal risk of dissemination of sarcoma cells associated with this procedure in individual cases, which, in these cases, could worsen the patient's prognosis. There is therefore an ongoing debate about whether morcellators should no longer be used in surgical procedures for uterine leiomyomas. The FDA has generally advised against the continued use of morcellators, and this position paper of the DGGG will specifically consider the individual aspects of this advice and give its own considered opinion about the risk of mistakes when treating uterine sarcomas.

## International Opinions (Overview)

Various authorities/organizations/professional societies have reported on the incidence of uterine sarcoma as an incidental finding during extirpation procedures to treat uterine leiomyomas or hysterectomies using morcellators and made a number of general recommendations or demands (Table 6). The five opinions published to date include a statement by the American SGO published in December 2013 [2] and updated in April 2014 [3], a comment by the FDA published in April 2014 [1] and updated in November 2014 [4], statements by the American College of Obstetricians and Gynecologists (ACOG) [6] and the Advancing



Minimally Invasive Gynecology Worldwide (AAGL) published in May 2014 [5,8], and a statement submitted by European Society for Gynaecological Endoscopy (ESGE) in December 2014, which is still in press [55]; all of them advocate informing patients extensively and in detail. The information given to patients about intra-abdominal morcellation using laparoscopy or robot-assisted techniques must include mentioning of the surgical benefits of this method, all potential risks involving the spread of malignant tissue, and possible alternatives. The second general consensus is the comprehensive rejection of morcellation if there is any suspicion of uterine malignancy. The probability of a coincidental finding of a sarcoma verified on pathological examination during hysterectomy or myomectomy is between 1/204 and 1/7400, depending on the opinion [1–6,55].

As the authority responsible for licensing and approval in the United State, the FDA has a significant impact on clinical practice in the USA. After recommending in April 2014 that the indications for surgery be reviewed, the recommendations in November 2014 were more specific [1,4]. The FDA was the only institu-

tion at the time to generally advise against the use of morcellators to remove leiomyomas in the following statement: “the FDA discourages the use of laparoscopic power morcellation during hysterectomy or myomectomy for uterine fibroids” [1]. Since then, this recommendation has been rephrased and the following two contraindications have been included [4]:

1. Morcellators are contraindicated for removal of uterine tissue containing suspected fibroids in patients who are peri- or post-menopausal or are candidates for en-bloc tissue removal through the vagina or mini-laparotomy incision.
2. Morcellators are contraindicated in patients with uterine fibroids suspicious for malignancy.

The scientific basis of the first statement made by the FDA in its most recent communication is unclear.

Based on the communication of the SGO [2], which the FDA initially referenced, the AAGL and the ACOG published their own communications one month later, followed by the ESGE at the beginning of 2015 [5,6,55]. The communication of the ESGE is published. These communications are scientific reviews; they

**Table 6** Overview of national and international recommendations.

	Country	Publication (year)	Incidence (%)	Recommendation*	Demand
FDA [1,4]	USA	April 2014 November 2014	1/350 (0.29%) <sup>2,3</sup>	Review indications for surgery (e.g. young patient wanting to have children)	
				Provide comprehensive information to patients	
				Morcellation is contraindicated if patient has suspected or known malignancy, if patients requiring removal are peri- or post-menopausal, or if en-bloc vaginal or abdominal retrieval is indicated	Product information (provided by manufacturer) must state the risks for users and patients
				Consider alternatives	If hysterectomy or myomectomy is indicated, patient should ask whether morcellation is appropriate
SGO [2,3]	USA	Dec. 2013 April 2014	1/1 000 (0.10%) <sup>1,3</sup>	Provide comprehensive information to patients	
				Morcellation is contraindicated if patient has suspected or known malignancy and is not advisable for pre-cancerous lesions which require risk-reducing surgery	
				Consider alternatives	
ACOG [6]	USA	May 2014	1/500 (0.20%) <sup>2,3</sup>	Provide comprehensive information to patients	Prospective national register
				Morcellation is contraindicated if patient has suspected or known malignancy	Research to focus on better diagnostic tools
				Consider alternatives	
AAGL [5,8]	Global	May 2014	1/400–1/1 000 (0.25–0.10%) <sup>1,3</sup>	Provide comprehensive information to patients	Evaluation of specimen bags
				Morcellation is contraindicated if patient has suspected or known malignancy	
				Consider alternatives	
ESGE [55,92]	Europe	2014	1/204–1/7 400 <sup>2,3</sup> (0.49–0.014%)	Provide comprehensive information to patients	
				Morcellation is contraindicated if patient has suspected or known malignancy	
				Standardized approach based on flow chart for women > 40 years	
				In-bag morcellation could improve safety of morcellation in future	

<sup>1</sup> for hysterectomy procedures; <sup>2</sup> for hysterectomy and myomectomy procedures; <sup>3</sup> not specified for morcellation

\* only extracts of total recommendations provided for some comments

Abbreviations: HE = hysterectomy; ME = myomectomy; FDA = U.S. Food and Drug Administration; SGO = Society of Gynecologic Oncology; ACOG = The American College of Obstetricians and Gynecologists; AAGL = Advancing Minimally Invasive Gynecology Worldwide; ESGE = European Society for Gynaecological Endoscopy

are far more comprehensive, include information on the evidence and sometimes criticize the recommendations issued by the FDA in its first communication on this subject. One of the initial points of criticism was the lack of a medical weighing up of the potential risks of morcellation of leiomyomas against the well-known benefits of a minimally invasive surgical approach. The AAGL and the SGO thus do not agree with the recommendation of the FDA prescribing an inexplicably restrictive use of morcellators [3, 5, 8]. A second point of criticism was the lack of stratification of patient characteristics and a lack of information about the data underpinning the FDA's probability calculation, which gave a 1/350 probability of a coincidental finding of uterine sarcoma during hysterectomy or myomectomy [5]. The latter point of criticism was discussed in somewhat greater detail in the FDA update issued in November 2014 [4]. The limited published studies were severely criticised for their study design [3, 8].

In addition to recommendations, a number of demands were also made to the authorities, the manufacturers and the physicians. Data which could answer critical questions is currently not sufficient to make strong recommendations based on scientific literature with high levels of evidence. As with most demands, there is an urgent need for better and more robust scientific data (Table 6).

### DGGG's Consideration of Individual Points

#### ▼ Coincidental finding of uterine sarcoma

The DGGG supports the critical comments by the AAGL and the ESGE against the line of reasoning taken by the FDA regarding the coincidental finding of uterine sarcoma during hysterectomy or myomectomy. In its first analysis, the FDA describes the source of the data used for its communications as follows: "based on an FDA analysis of currently available data". This statement was included in the first communication and was amended in the most recent communication of the FDA where it now reads "The FDA conducted a review of published and unpublished scientific literature, including patients operated on from 1980 to 2011 to estimate the prevalence of unsuspected uterine sarcoma and uterine leiomyosarcoma in patients undergoing hysterectomy or myomectomy for presumed benign fibroids (leiomyoma)". This most recent statement still does not permit any conclusion to be drawn about the methodology, the literature reviewed, or the method of analysis used [1, 4, 5, 55]. Nevertheless, the frequencies given in the five communications are between 1/204 and 1/7400 (0.49–0.014%), which generally corresponds to those in other papers which have reported mean frequencies of about 1/420 (0.24%) (Table 7). However, the frequencies given in the five international communications (Table 6) refer without exception to hysterectomy or myomectomy procedures and not to the real topic of the communication, i.e. the incidence and risk associated with morcellation [1, 2, 6]. Three papers have been published which discussed the coincidental finding of uterine sarcoma in actual morcellation procedures, and the reported incidence has ranged from 1/250 to 1/545 (0.40 to 0.18%) [44, 51, 56]. This gives a mean incidence of 1/416 (0.24%) for the finding of a uterine sarcoma during morcellation carried out as part of a myomectomy or hysterectomy procedure (Table 7). A further paper on morcellation could not be evaluated because it did not include information about the basic population size and its relation to the eight detected sarcomas [57]. One evaluation published this year included 232882 patients who underwent minimally invasive

hysterectomy; morcellation was carried out in 36470 cases (15.7%). Uterine malignancy was found in 99 cases. This would correspond to an incidence of 1/368 (0.27%) based on more than 36000 morcellations. No separate evaluation was done of the histological findings or of the individual uterine sarcomas [58]. The probability for uterine sarcoma is probably much lower than the incidence reported for not otherwise specified uterine malignancies. It is generally assumed that the percentage of uterine sarcomas in uterine malignancies is 3–7% [17, 59]. The precise surgical setting in which the morcellations were carried out in this study were also not described in detail. The papers refers to 59 non robot-assisted procedures and 40 robot-assisted surgical operations [58].

The conclusion was that the data was sufficient to determine the incidence for the combined endpoint "coincidental finding of uterine sarcoma" and the therapeutic setting of "uncomplicated hysterectomy, myomectomy and/or morcellation for a mass previously assumed to be benign"; the incidence across all studies was found to be 21/8753 or 1/417 (0.24%), respectively (Table 7). Based on three selected studies out of the ten referenced papers, the probability of coincidental uterine sarcoma on morcellation was approximately 1/416 (also 0.24%) (Table 7). Based on the meeting of the Obstetrics and Gynecology Devices Panel of the FDA Medical Devices Advisory Committee on July 11, 2014, after which the FDA subsequently updated its communication [4] and the as yet unpublished ESGE communication, the reported figure is 1/7400 (0.014%) [55, 60].

There are three criticisms which need to be made about the available data for the individual methods used, because they are particularly relevant for these ten studies:

1. Not all of the papers specified the approach used; this means that there is no information about the specific surgical procedure during which the sarcoma was detected [61–63].
2. Even if the approach used is mentioned, the specific surgical procedure during which the sarcoma was detected is sometimes still lacking [61, 62].
3. Even if the primary surgical procedure is included, the figures were not calculated with reference to the total patient population [57].

Moreover, the design of individual studies was also problematic: nine of the ten articles were single-center studies. Eight of the ten articles described retrospective studies. Not a single article describing a randomized multicenter design has been published to date. In seven of the ten articles, the period of data collection commenced before the millennium, which would affect the diagnostic and technical methods used (Table 7).

In Germany, the probability of finding uterine sarcoma during a procedure for a benign preoperative indication (uterine fibroids) must be set against the increasing number of laparoscopic organ-sparing (enucleation) or organ-removing (sub-/total hysterectomy) procedures (Fig. 3) being carried out, as the total number of operations for uterine fibroids carried out in hospital continues to decrease (Fig. 4). The percentage of laparoscopic approaches increased from 13% in 2002 to 47% in 2012. In the same period, the percentage of coded morcellations (irrespective of the chosen approach) increased from 5.6% in 2002 to 19.6% in 2012. However, the calculated ratio for morcellation of uterine fibroids in laparoscopic procedures remained fairly constant for this decade at 0.39 to 0.43. This means that morcellation is carried out in every 2nd or 3rd woman with an indication of surgery for leiomyoma using neither a vaginal nor an abdominal approach.

**Table 7** Overview of all coincidental findings of uterine sarcoma during hysterectomy or myomectomy.

ID	Author	Data collection period (years)	Publication (year)	Procedure (for total patient population)	Patients (n)	Approach	Uterine sarcomas* (n% of patients)	Uterine sarcoma* (surgical procedures at the coincidental finding)	Uterine sarcoma* (relevant patient characteristics)	
1	Leibsohn [61] <sup>a,e</sup>	1983–1988	1990	hysterectomy	1 429	unknown	<b>7 (0.49%):</b> 7 LMS	not specified, but probably no morcellation at the time of data collection	Unknown	
2	Reiter [93] <sup>b,d</sup>	1986–1989	1992	hysterectomy	104	unknown	0	–	–	
3	Parker [62] <sup>b,d,e</sup>	1988–1992	1994	hysterectomy/ myomectomy	1 332	unknown	<b>3 (0.23%):</b> 2 ESS 1 LMS	not specified, but probably no morcellation at the time of data collection	Unknown	
4	Takamizawa [94] <sup>b,d</sup>	1983–1997	1999	hysterectomy	923	ABD: 892 (97%) VAG: 31 (3.4%)	<b>2 (0.22%):</b> 2 LMS	2 per ABD	<b>Age</b> #1 44; #2 47 years <b>OS:</b> #1 11 m (alive); #2 6 a (alive, recurr.)	
5	Einstein [57] <sup>b,d,***</sup>	2000–2006	2008	hysterectomy/ myomectomy/ morcellation	k. A.	VAG TLH ABD	8 (–): 5 LMS 3 ESS	5 SCH 3 morcellations (1 LASH; 1 SCH; 1 myomectomy)	<b>OS:</b> #1 30 m (alive); #2 61 m (alive); #3 31 m (alive); #4 37 m (alive); #5 22 m (alive); #6 18 m (alive); #7 28 m (alive); #8 6 m (alive, recurr.) not specified	
6	Sinha [51] <sup>a,c</sup>	1998–2005	2008	myomectomy with morcellation	505	LSK: 505 (100%)	<b>2 (0.40%):</b> 2 LMS	2 LSK myomectomy with morcellation	not specified	
7	Leung [56] <sup>b,d</sup>	1996–2005	2009	hysterectomy with morcellation	1 297	VAG: 855 (66%) ABD: 393 (30%) LAVH: 49 (4%)	<b>3 (0.23%):</b> 3 LMS	1 ABD 1 LAVH with morcellation 1 VAG with morcellation	<b>Age:</b> #1 49; #2 51; #3 47 years <b>Symptoms:</b> #1 pain; #2 and #3 pain, growth	
8	Kamikabeya [63] <sup>a,d</sup>	1987–2008	2010	hysterectomy	1 364	not specified	<b>1 (0.07%):</b> 1 LMS	1 total hysterectomy	<b>Age:</b> #1 58; #2 45 years <b>Symptoms:</b> #1 bleeding and pain; #2 bleeding	
9	Seidman [44] <sup>a,d</sup>	2005–2010	2012	hysterectomy/ myomectomy/ morcellation	1 091	LSK: 1 091 (100%)	<b>2 (0.18%):</b> 1 ESS 1 LMS	1 LSK myomectomy with morcellation 1 TLH with morcellation	<b>Age:</b> #1 48; #2 42 years <b>sPDM:</b> #1 no; #2 no <b>OS:</b> #1 34 m (alive); #2 42 m (alive)	
10	Ramm [68] <sup>b,d</sup>	2004–2009	2012	hysterectomy	708	VAG: 413 (58%) ABD: 165 (23%) LSK: 130 (18%)	<b>1 (0.14%):</b> 1 LMS	1 VAG	<b>Age:</b> #1 55 years <b>Symptoms:</b> #1 no pain, no bleeding	
<b>Overall operations (ID 1–4, 6–10)</b>							<b>21 and</b>			
<b>Operations with morcellation and consideration of individual cases (ID 6, 7, 9)</b>							<b>417 resp.</b> <b>2 500 and</b> <b>416 resp.</b>	<b>1 resp. (0.24%)*</b> <b>6 and</b> <b>1 resp. (0.24%)*</b>		

\* excluding carcinosarcomas; \*\* includes only VAG and LAVH; \*\*\* excluded because no information available on overall patient population

<sup>a</sup> single center; <sup>b</sup> bj/multicenter; <sup>c</sup> prospective; <sup>d</sup> retrospective; <sup>e</sup> no full publication available

Abbreviations: VAG = vaginal hysterectomy; TLH = total laparoscopic hysterectomy; LAVH = laparoscopy-assisted vaginal hysterectomy; ABD = abdominal hysterectomy; SCH = supracervical hysterectomy (without specifying the approach); sPDM = secondary peritoneal dissemination; OS = overall survival; recurr. = recurrence; m = months; a = years;

As the age-specific incidence of uterine sarcoma has remained approximately the same at 1.32 and 1.30 for every 100 000 women in Germany and Bavaria, respectively, and the number of laparoscopies and morcellations of leiomyomas has increased, the statistical probability of finding uterine sarcoma during surgery decreases (● **Table 4**) [14, 21, 22].

### DGGG Statement #1

The risk for coincidental uterine sarcoma during hysterectomy with hysterotomy and/or myomectomy is approximately 1/416 (0.24%). Based on an evaluation of the most recent literature it is ultimately not possible to quantify precisely the risk of uterine sarcoma after hysterotomy with or without morcellation.

### DGGG Demand #1

Every morcellation which is accompanied by coincidental finding of uterine sarcoma should be reliably documented in the Cancer Register as this will permit the probability of uterine malignancy (including uterine sarcoma) to be quantified more precisely in future. The Register should include the following items:

1. indications
2. preoperative diagnosis
3. general patient characteristics
4. surgical approach and surgical technique
5. histological data
6. progress of disease
7. precise histological description

### Preoperative diagnosis

All five communications agree that it is not possible to make an unambiguous and precise diagnosis preoperatively, nor are there any surrogate markers which are capable of differentiating preoperatively between benign leiomyoma and malignant uterine sarcoma (LMS or ESS) [1, 2, 5, 6].

The most common clinical symptoms for uterine sarcoma reported in 47 to 70% of cases were atypical vaginal bleeding and pain [34, 36, 61, 64, 65]. Another possible clinical sign is a rapid increase in uterine size. The few existing studies on this topic were unable – given the limited number of cases with uterine sarcoma in the total patient population and the retrospective design of the studies – to identify “rapid growth” as a surrogate marker of malignancy. Many patients presented with rapid uterine growth without having uterine sarcoma or had uterine sarcoma without rapid uterine growth. This clinical symptom cannot therefore be used as a confirmation of the suspicion of uterine sarcoma [43, 62, 66–68].

There are few reports on preoperative histopathological investigation for suspicion of malignancy prior to laparoscopy with planned morcellation [69]. One study investigating 63 patients carried out ultrasound-guided core-needle biopsy for previously unclear uterine mass on MRI. Malignancy was found in 12 cases (19%) and histology was benign in 51 cases (81%), 27 of which underwent surgery. Only one histological evaluation of a surgical specimen (4%) found previously undetected uterine sarcoma contrary to the preoperative findings of core-needle biopsy. This corresponds to a positive predictive value (PPV) of 100% and a negative predictive value (PNV) of 96.2% [70]. A large review of 730 patients documented 142 uterine sarcomas (20%). 72 uterine sarcomas (51%) were identified histologically prior to surgery using pipelle biopsy or fractional curettage. There was no significant difference in the method used for histological sampling between biopsies and curettage ( $p = 0.84$ ). The study did not include

detailed information on patients or whether they were a high-risk patient population [71].

Use of such well-known imaging procedures as transvaginal ultrasound (VUS) [46], computer tomography (CT) [72], magnetic resonance imaging (MRI) [46, 72–74] or positron emission tomography (PET) with CT [46] has been proposed and described. But these imaging methods have been found to have limitations, particularly in younger patients suspicious for ESS. As expected, the group of authors who compiled this paper have come to the conclusion that imaging cannot exclude uterine sarcoma (LMS or ESS), it can only confirm the suspicion [46]. It is also not possible to differentiate the various histological types (LMS, ESS, UES, adenocarcinoma, MMMT) preoperatively [74].

The usefulness of well-known tumor markers such as LDH or CA 12–5 for preoperative diagnosis is very limited [15].

Some authors have proposed carrying out a PAP test in all patients scheduled to undergo hysterectomy with morcellation [75]. This could also be used to diagnose cervical or endometrial cancer.

All relevant communications strongly advise against performing minimally invasive procedures in patients with unclear uterine findings suspicious for malignancy [1, 2, 4–6, 55].

### DGGG Recommendation #1

There are no means of obtaining an unambiguous diagnosis preoperatively, and there are no clear criteria to evaluate suspicious findings detected during preoperative examination. Thorough patient history (including risk factors and symptoms), vaginal ultrasound examination and possibly preoperative cytological and/or histological evaluation (hysteroscopy, curettage) of abnormalities could be useful, but these methods cannot entirely rule out the possibility of sarcoma. CT, MRI or PET/CT may provide useful imaging support when assessing the risk in individual patients, but they cannot rule out the presence of uterine sarcoma in any patient, too.

### DGGG Recommendation #2

If the preoperative diagnosis is unclear or doubtful, no minimally invasive procedure or morcellation should be recommended or carried out in patients where there is a suspicion of potential uterine malignancy.

### DGGG Demand #2

A prospective risk score should be developed, e.g. a nomograph, which would include the few scientifically proven items and could be used to identify groups at risk for uterine sarcoma preoperatively.

### Surgical management

Together with the patient, the treating physician should carry out a benefit/risk analysis of a minimally invasive procedure with morcellation. In addition to preoperative measures such as correct indication and diagnostic workup of suspicious uterine findings, surgical techniques must include intraoperative measures to avoid malignant peritoneal spread. These can include the use of specimen retrieval bags or the use of closed systems in general [5, 9]. Whether these methods will reduce the risk of dissemination compared to an investigated control group has only been investigated in small cohorts with limited cases numbers ( $n = 8–12$ ) and without comparable control groups [76, 77]. If specimen retrieval bags are used, then this needs to be done consistently in the interests of oncological safety [2, 5]:

1. Puncture of the specimen retrieval bag must be avoided,
2. Visualization should be extracorporeal, and should be covered access ports.

In the event of coincidental uterine sarcoma, primary surgery should be done as a two-stage procedure. If the planned procedure prior to the coincidental finding was myoma enucleation or LASH, then the entire uterus or cervix uteri should be completely removed [34,78]. A second operation should be carried out as an open surgical procedure and must include careful inspection of the entire abdomen with careful histological workup of suspicious areas because higher-stage disease with regional spread is associated with a poorer prognosis [39]. The decision for adjuvant therapy subsequent to surgery must be discussed individually with the patient. In principle, it is recommended that the patient is presented to a certified gynecological cancer center which has the appropriate expertise.

If a suspicion of malignancy arises intraoperatively, then the operation should be discontinued. Usually, if the preoperative indication was benign, the patient will not have been informed about one-stage procedures for malignancy. Intraoperative frozen section assessment is often not diagnostically conclusive and should therefore not be carried out.

### DGGG Statement #2

Because of the limited number of studies, it is not possible to give a definitive recommendation concerning the use of specimen retrieval bags.

### DGGG Recommendation #3

If the preoperative indication was benign mass and a uterine sarcoma is identified intraoperatively, surgery should consist of a two-stage open procedure. The second operation should comply with current oncological principles and be carried out in a certified oncological institution.

### Pathological evaluation

The final pathological evaluation which includes the option of additional immunohistochemical staining of the primary surgical specimen is a relevant prognostic factor and directly affects the decision for therapy [36].

### DGGG Recommendation #4

Histopathological evaluation should be done using formalin-fixed paraffin-embedded (FFPE) surgical specimens. Correct histological classification is only possible using a specimen obtained during surgery.

### Prognostic relevance

A number of factors are assumed to be prognostic factors (Table 5). But almost no studies have carried out a prospective evaluation in a multivariate model (cf. **Prognostic factors**). The prognostic relevance of the factors described in the literature is unclear, and they are therefore not necessarily synonymous with a deterioration or improvement of prognosis. Morcellation or rupture of a uterine sarcoma should receive more attention, and the issue is currently an important topic of discussion. Some studies showed a clear deterioration of prognosis after primary morcellation of a uterine sarcoma which had not been identified preoperatively [43,79–81]. One study group from Seoul carried out a retrospective single-center study of 56 patients (Group 1 morcellation: n = 25, Group 2 no morcellation: n = 31) and found a lower disease-free survival (DFS) and overall survival after mor-

cellation on univariate analysis with a 5-year survival rate of 73 vs. 46% (OR 3.07; 95% CI: 1.19–8.93; p = 0.040). This was also confirmed on multivariate analysis (OR 3.11; 95% CI: 1.07–9.06; p = 0.038) [43]. Another study reported that perioperative tumor rupture reduced the 5-year survival rate of 382 patients from 64 to 27% with a hazard ratio (HR) of 3.24 (95% CI: 2.34–4.48; p = 0.0001). On multivariate analysis the HR was 2.12 (95% CI: 1.39–3.25; p = 0.0005) for tumor rupture [79]. This was similar to intraoperative macroscopic tumor remnant, which had a HR of 3.99 (95% CI: 2.72–5.86; p = 0.0001). Other studies have confirmed the findings of a poorer prognosis after morcellation [80, 81]. But these findings were contradicted by one study which reported that the prognosis did not differ between groups [82]. Higher-stage disease did not always lead in every case to a poorer prognosis with a lower 5-year overall survival, for example from stage I (51%) to stage II (25%) LMS or from stage I (84%) to stage II (62%) ESS [39]. In patients with higher-stage disease, morcellation probably had less impact because prognosis was already poor compared to patients with early-stage uterine sarcoma and a better prognosis.

When assessing the deterioration of prognosis, studies did not differentiate between hysterotomy alone with myoma manipulation and extirpation of the myoma with morcellation. The incidence of retained benign parasitic tissue reported for the latter method was 0.12–1.2%. It is not clear whether a second operation carried out within a short space of time could solve this problem of prognosis or whether patients with residual tissue have a particularly poor prognosis [55].

### DGGG Statement #3

Dissemination of malignant tumor cells in the abdominal cavity results in a poorer prognosis. It is not possible to give precise figures about the extent of the deterioration of prognosis.

### Treatment alternatives

Alternative surgical and interventional procedures such as uterine artery embolization (UAE) or radiofrequency ablation can be offered to selected patients with uterine fibroids not suspicious for malignancy. Additional innovative procedures to treat uterine leiomyomas include non-invasive procedures such as MR-guided focussed ultrasound (MRgFUS) [83–87]. The data (case reports) on coincidental uterine sarcomas for these less common alternatives is even less conclusive [88,89].

### Information for patients

Patients should be provided with information on the benefits, risks or disadvantages, and alternatives. By giving her consent, the patient indemnifies the physician against claims for bodily harm by negligence pursuant to section 229 of the German Criminal Code (*Strafgesetzbuch* §229). The information given to the patient must also cover risks which are extremely rare but which – if they do occur – can have life-threatening implications [90]. The information on minimally invasive extirpation procedures to treat uterine fibroids should include information on the potential use of morcellation. The explanation of the advantages associated with a laparoscopic approach already largely covers the benefits of morcellation. The specific risks and disadvantages of morcellation outlined in the recommendations of the AAGL need to be listed and communicated to the patient in a modified and comprehensible form [5]. Risks include:

1. injury to adjacent organs, vessels or nerves [54];
2. dissemination of benign tissue in the abdomen and pelvis [91];

3. dissemination of potentially malignant tissue in the abdomen and pelvis which may worsen the prognosis [44];
4. histopathological evaluation of the tissue specimen may be more difficult because the specimen is fragmented;
5. a potential need for re-operation or further treatment (second operation, chemotherapy, radiotherapy) [51].

One hospital in Germany (Tübingen, personal communication) has already developed and amended an addendum to the established information sheets for all vaginal, abdominal, laparoscopic and hysteroscopic procedures (● Fig. 8). This information sheet which describes the risk of disseminating malignant tumor cells for the above listed procedures serves as a good example for the relevance of this topic.

#### DGGG Recommendation #5

During preoperative discussions the patient must be informed in detail about the benefits, risks and disadvantages of planned minimally invasive procedures without/with morcellation as well as the potential alternatives.

#### DGGG Demand #3

The informed consent forms currently used in hospitals need to be modified or supplemented by additional information sheets for patients.

#### Recall/Prohibition of Morcellators

▼ The manufacturer Ethicon Inc. (Johnson-Johnson) announced in June 2014 that it would “suspend global commercialization (sales, distribution and promotion) of its Morcellation Devices” [9]. A worldwide voluntary recall action was initiated in August 2014. The notice for the voluntary recall stated: “... the risk-benefit assessment associated with the use of these devices in hysterectomy and myomectomy procedures for removing fibroids remains uncertain. Because of this uncertainty, Ethicon believes that a product recall of Ethicon Morcellation Devices is the appropriate course of action at this time until further medical guidelines are established and/or new technologies are developed to mitigate the risk.” The notice references the FDA recommendations of April 2014 as the reason for this recall. Detailed instructions on how to proceed with the recall are appended to the recall notice [10].

#### DGGG Statement #4

Both the probability estimate and the risk assessment of a deterioration of prognosis must be completely resolved. Whether, after proper consideration of all aspects, patient safety will increase following the prohibition ban or sales ban of morcellators cannot currently be answered definitively. Benefits and risks of morcellator use must be weighed up in discussions with each individual patient. In this context, weighing up means outlining all the risks and the benefits of open versus laparoscopic procedures and weighing up one against the other.

#### DGGG Demand #4

The product information needs to be modified. Even a minimal risk is still a risk that needs to be mentioned.

#### Summary

- ▼ 1. Uterine sarcoma is a rare malignancy which affects women. The incidence in Germany standardized for age is estimated to be approximately 1.32 for every 100 000 women. Over 80% of patients are more than 50 years old.
2. A number of risk factors (age, tamoxifen use, pelvic irradiation) and various clinical, pathological and therapeutic prognostic factors have been described. A prospective risk score to identify risk groups should be developed (Demand #2).
3. According to the current scientific evidence, the incidence for the coincidental finding of uterine sarcoma for a combined endpoint (hysterectomy, myomectomy, morcellation) is estimated to be about 1/416 (0.24%). It is not possible to make a scientific statement about the risk of coincidental uterine sarcoma differentiated according to individual surgical methods (Statement #1). Register studies to estimate the risk are necessary (Demand #1).
4. There are currently no preoperative examinations or diagnostics capable of differentiating unambiguously between benign and malignant entities (Recommendation #1).
5. In patients with diagnostically unclear uterine findings suspicious for malignancy it is recommended not to use a minimally invasive approach (Recommendation #2).
6. Use of a specimen retrieval bag is not suitable to prevent malignant peritoneal dissemination definitely and deterioration of prognosis. Use of a specimen retrieval bag does not justify an uncritical use of morcellators (Statement #2).
7. In the curative setting, uterine sarcomas should be treated by primary surgery in accordance with current oncological principles (Recommendation #3).
8. Complete histopathological evaluation should be done using a formalin-fixed surgical specimen (Recommendation #4).
9. Dissemination of malignant tissue may worsen the patient's prognosis. The current data is not sufficient to arrive at a definitive conclusion which would allow an estimate of the deterioration of prognosis for the individual patient (Statement #3).
10. The patient must be provided with detailed information; procedures require the patient's informed consent (Recommendation #5). The established information sheets in German hospitals need to be modified (Demand #3).
11. It is currently not possible to state whether a prohibition and sales ban of morcellators will improve patient safety. The benefits and risks of morcellator use must be weighed up in individual discussions with the patient (Statement #4). The product information needs to be modified (Demand #4).

#### Conflict of Interest

▼ None.

## Surgical procedures of the inner female genitalia, uterus, ovaries and Fallopian tubes

### Addendum to the Perimed information sheet for all vaginal, abdominal, laparoscopic and hysteroscopic interventions

Dear patient,

Modern gynecology is characterized by the systematic use of the most modern technology; this has meant that surgical procedures to treat patients are as gentle and sparing as possible. This applies to surgery using a vaginal approach, to procedures carried out using so-called “mini-abdominal” incisions and to endoscopic surgery. This “minimally invasive” approach has been made possible by the development of a special set of instruments. The term “minimally invasive” derives from the fact that no or only small incisions are made in the body’s exterior during complex gynecological surgical procedures to reach the surgical site. For example, a greatly enlarged uterus can be removed from the abdominal cavity through the vagina or through a small incision of the abdominal wall after the uterus has previously undergone a reduction in size (morcellation). This means that no scars will be visible on the skin or the scars will be very small. The term “keyhole surgery” is often used colloquially to describe this type of surgery.

Modern surgical methods offer significant advantages compared, for example, to conventional surgery with incision of the abdominal wall. There are no external scars or external scars are very small. Surgical procedures can also be carried out in body cavities such as the stomach, intestine or uterus, without requiring a long abdominal incision through the skin. This helps to prevent long hospital stays. Moreover, this approach can significantly reduce pain and patients can be mobilized much more quickly; this offers additional benefits, not just because it reduces the risk of thrombosis. The dissection and removal of tissue structures during surgery is often done under magnification. This is particularly beneficial for patients because it allows nerves and vessels to be identified more clearly, making it easier to preserve them.

In all surgical procedures of the inner female genitalia (uterus, ovaries, Fallopian tubes) – irrespective of the surgical technique (abdominal or vaginal approach, tissue morcellation, hemisection of the uterus, surgical hysteroscopy, laparoscopy, myoma or polyp ablation, etc.) – there is always a very small risk of small or “dormant” areas of malignant tissue (tumors), which are not detected during preoperative diagnostic procedures and not found on surgery. During surgery of the vaginal or abdominal area (e.g., incision of the uterus, morcellation of myomas and/or the uterus, removal of ovarian cysts), these hidden malignant tissue areas (the risk, for example, with myomas is far less than one in a thousand) can – even if this only occurs in very rare cases – disseminate malignant cells in the body.

### Informed Consent

I confirm that I have understood the problems described above and have been informed of the very low risk of a dissemination of malignant cells during the surgical procedure planned for me; the surgery will be performed according to the most modern surgical techniques.

*Patient label:*

[Redacted area for patient label]

*Date and signature of the patient*

**Fig. 8** Example of an information sheet for coincidental uterine sarcoma developed for the Gynecological University Hospital of Tübingen.

#### Affiliations

- <sup>1</sup> Universitätsklinikum Erlangen-Nürnberg, Frauenklinik, Erlangen
- <sup>2</sup> Universitätsklinikum des Saarlandes, Klinik für Frauenheilkunde, Geburtshilfe und Reproduktionsmedizin, Homburg
- <sup>3</sup> Hochtaunus-Kliniken Bad Homburg, Frauenklinik, Bad Homburg
- <sup>4</sup> Klinikum Kassel, Frauenheilkunde und Geburtshilfe, Kassel
- <sup>5</sup> Kliniken Essen-Mitte, Gynäkologie & Gynäkologische Onkologie, Essen

- <sup>6</sup> Uniklinik Köln, Klinik und Poliklinik für Frauenheilkunde und Geburtshilfe, Cologne
- <sup>7</sup> Landeskrankenhaus Feldkirch, Gynäkologie und Geburtshilfe, Feldkirch
- <sup>8</sup> Universitätsklinikum Jena, Klinik für Frauenheilkunde und Geburtshilfe, Jena
- <sup>9</sup> HELIOS Klinikum Berlin-Buch, Klinik für Gynäkologie und Geburtshilfe, Berlin
- <sup>10</sup> Universitätsklinikum Tübingen, Frauenklinik, Tübingen

## References

- 1 U.S. Food and Drug Administration. Laparoscopic uterine power morcellation in hysterectomy and myomectomy: FDA safety communication. Online: <http://www.fda.gov/medicaldevices/safety/alertsandnotices/ucm393576.htm>; last access: 15.07.2014
- 2 Society of Gynecologic Oncology. SGO position statement: morcellation. Online: <https://www.sgo.org/newsroom/position-statements-2/morcellation/>; last access: 15.07.2014
- 3 Society of Gynecologic Oncology. Statement of the SGO to the FDA's Obstetrics and Gynecology Medical Devices Advisory Committee concerning safety of laparoscopic power morcellation. Online: <https://www.sgo.org/wp-content/uploads/2014/04/SGO-Testimony-to-FDA-on-Power-Morcellation-FINAL.pdf>; last access: 15.07.2014
- 4 U.S. Food and Drug Administration. Updated laparoscopic uterine power morcellation in hysterectomy and myomectomy: FDA safety communication. Online: <http://www.fda.gov/MedicalDevices/Safety/AlertsandNotices/ucm424443.htm>; last access: 24.11.2014
- 5 AAGL Advancing Minimally Invasive Gynecology Worldwide. AAGL practice report: Morcellation during uterine tissue extraction. *J Minim Invasive Gynecol* 2014; 21: 517–530
- 6 American College of Obstetricians and Gynecologists. Power morcellation and occult malignancy in gynecologic surgery. Online: <http://www.acog.org/Resources-And-Publications/Task-Force-and-Work-Group-Reports/Power-Morcellation-and-Occult-Malignancy-in-Gynecologic-Surgery>; last access: 15.07.2014
- 7 Bin Han Ong M. FDA Advisors Debate Ban, Black Box and Status quo of Power Morcellators. *The Cancer Letter* 2014; 40: 5–7
- 8 AAGL Advancing Minimally Invasive Gynecology Worldwide. AAGL statement to the FDA on power morcellation. Online: <http://www.aagl.org/aaglnews/aagl-statement-to-the-fda-on-power-morcellation/>; last access: 15.07.2014
- 9 Ethicon Inc. Wichtige Kundeninformation zu Ethicon Morcellations Geräten. 2014. Online: [http://www.bfarm.de/SharedDocs/Kundeninfos/DE/14/2014/2451-14\\_Kundeninfo\\_de.pdf?\\_\\_blob=publicationFile&v=1](http://www.bfarm.de/SharedDocs/Kundeninfos/DE/14/2014/2451-14_Kundeninfo_de.pdf?__blob=publicationFile&v=1); last access: 06.08.2014
- 10 Ethicon Inc. Rückruf für das Tissue Morcellation System, Ethicon. Online: <http://www.ethicon.com/sites/default/files/managed-documents/Ethicon%20Morcellation%20Devices%20Customer%20Letter%20Final.pdf>; last access: 06.08.2014
- 11 Beckmann MW, Denschlag D, Gaß P et al. 195. Stellungnahme der DGGG – Durchführung des Medizinproduktegesetzes – Gynäkologische Morcellatoren. Online: [http://www.dggg.de/leitlinienstellungnahmen/aktuelle-stellungnahmen/?eID=dam\\_frontend\\_push&docID=2607](http://www.dggg.de/leitlinienstellungnahmen/aktuelle-stellungnahmen/?eID=dam_frontend_push&docID=2607); last access: 17.10.2014
- 12 Deutsches Institut für Medizinische Dokumentation und Information. International classification of diseases for oncology. 3rd ed. Online: <http://www.dimdi.de/static/de/klassi/icdo3/index.htm>; last access: 28.06.2014
- 13 Deutsches Institut für Medizinische Dokumentation und Information. German procedure classification (OPS) 2014. Online: <http://www.dimdi.de/static/de/klassi/ops/index.htm>; last access: 28.06.2014
- 14 Statistisches Bundesamt. DRG-Statistik 2005–2012. Bonn: Eigenverlag des Statistischen Bundesamtes; 2014
- 15 DGGG. Uterine sarkoma, 2015. National German Guideline (S1). Long version. AWMF registry no. 015/074. 2014 (Manuscript submitted for publication)
- 16 Toro JR, Travis LB, Wu HJ et al. Incidence patterns of soft tissue sarcomas, regardless of primary site, in the surveillance, epidemiology and end results program, 1978–2001: an analysis of 26,758 cases. *Int J Cancer* 2006; 119: 2922–2930
- 17 Brooks SE, Zhan M, Cote T et al. Surveillance, epidemiology, and end results analysis of 2677 cases of uterine sarcoma 1989–1999. *Gynecol Oncol* 2004; 93: 204–208
- 18 Harlow BL, Weiss NS, Lofton S. The epidemiology of sarcomas of the uterus. *J Natl Cancer Inst* 1986; 76: 399–402
- 19 Nordal RR, Thoresen SO. Uterine sarcomas in Norway 1956–1992: incidence, survival and mortality. *Eur J Cancer* 1997; 33: 907–911
- 20 Mastrangelo G, Coindre JM, Ducimetière F et al. Incidence of soft tissue sarcoma and beyond: a population-based prospective study in 3 European regions. *Cancer* 2012; 118: 5339–5348
- 21 Robert Koch-Institut (RKI). Inzidenz von Sarkomen nach histologischem Typ (Deutschland). Berlin: Gesundheitsberichterstattung des Bundes; 2014
- 22 Bevölkerungsbezogenes Krebsregister Bayern. Inzidenz von Sarkomen nach histologischem Typ (Bayern). Erlangen: Bevölkerungsbezogenes Krebsregister Bayern Registerstelle; 2014
- 23 Denschlag D, Masoud I, Stanimir G et al. Prognostic factors and outcome in women with uterine sarcoma. *Eur J Surg Oncol* 2007; 33: 91–95
- 24 Norris HJ, Taylor HB. Mesenchymal tumors of the uterus. I. A clinical and pathological study of 53 endometrial stromal tumors. *Cancer* 1966; 19: 755–766
- 25 Kjerulff KH, Langenberg P, Seidman JD et al. Uterine leiomyomas. Racial differences in severity, symptoms and age at diagnosis. *J Reprod Med* 1996; 41: 483–490
- 26 Fang Z, Matsumoto S, Ae K et al. Postradiation soft tissue sarcoma: a multiinstitutional analysis of 14 cases in Japan. *J Orthop Sci* 2004; 9: 242–246
- 27 Yildirim Y, Inal MM, Sancı M et al. Development of uterine sarcoma after tamoxifen treatment for breast cancer: report of four cases. *Int J Gynecol Cancer* 2005; 15: 1239–1242
- 28 Lavie O, Barnett-Griness O, Narod SA et al. The risk of developing uterine sarcoma after tamoxifen use. *Int J Gynecol Cancer* 2008; 18: 352–356
- 29 Wysowski DK, Honig SF, Beitz J. Uterine sarcoma associated with tamoxifen use. *N Engl J Med* 2002; 346: 1832–1833
- 30 Wickerham DL, Fisher B, Wolmark N et al. Association of tamoxifen and uterine sarcoma. *J Clin Oncol* 2002; 20: 2758–2760
- 31 American College of Obstetricians and Gynecologists Committee on Gynecologic Practice. ACOG committee opinion. No. 336: Tamoxifen and uterine cancer. *Obstet Gynecol* 2006; 107: 1475–1478
- 32 Toro JR, Nickerson ML, Wei MH et al. Mutations in the fumarate hydratase gene cause hereditary leiomyomatosis and renal cell cancer in families in North America. *Am J Hum Genet* 2003; 73: 95–106
- 33 Schwartz SM, Weiss NS, Daling JR et al. Exogenous sex hormone use, correlates of endogenous hormone levels, and the incidence of histologic types of sarcoma of the uterus. *Cancer* 1996; 77: 717–724
- 34 Trope CG, Abeler VM, Kristensen GB. Diagnosis and treatment of sarcoma of the uterus. A review. *Acta Oncol* 2012; 51: 694–705
- 35 Fletcher CDM et al. WHO Classification of Tumours of soft Tissue and Bone. Genf: World Health Organization (WHO); 2013
- 36 D'Angelo E, Prat J. Uterine sarcomas: a review. *Gynecol Oncol* 2010; 116: 131–139
- 37 Prat J. FIGO staging for uterine sarcomas. *Int J Gynaecol Obstet* 2009; 104: 177–178
- 38 FIGO. Corrigendum to FIGO staging for uterine sarcomas. *Int J Gynaecol Obstet* 2009; 104: 179
- 39 Abeler VM, Røyne O, Thoresen S et al. Uterine sarcomas in Norway. A histopathological and prognostic survey of a total population from 1970 to 2000 including 419 patients. *Histopathology* 2009; 54: 355–364
- 40 Chew I, Oliva E. Endometrial stromal sarcomas: a review of potential prognostic factors. *Adv Anat Pathol* 2010; 17: 113–121
- 41 Gadducci A. Prognostic factors in uterine sarcoma. *Best Pract Res Clin Obstet Gynaecol* 2011; 25: 783–795
- 42 Rauh-Hain JA, del Carmen MG. Endometrial stromal sarcoma: a systematic review. *Obstet Gynecol* 2013; 122: 676–683
- 43 Park JY, Park SK, Kim DY et al. The impact of tumor morcellation during surgery on the prognosis of patients with apparently early uterine leiomyosarcoma. *Gynecol Oncol* 2011; 122: 255–259
- 44 Seidman MA, Oduyebo T, Muto MG et al. Peritoneal dissemination complicating morcellation of uterine mesenchymal neoplasms. *PLoS One* 2012; 7: e50058
- 45 Li AJ, Giuntoli RL 2nd, Drake R et al. Ovarian preservation in stage I low-grade endometrial stromal sarcomas. *Obstet Gynecol* 2005; 106: 1304–1308
- 46 Amant F, Coosemans A, Debiec-Rychter M et al. Clinical management of uterine sarcomas. *Lancet Oncol* 2009; 10: 1188–1198
- 47 Wallwiener D, Jonat W, Kreienberg R, Friese K, Diedrich K, Beckmann MW, Hrsg. Atlas der gynäkologischen Operationen. 7. Aufl. Stuttgart: Thieme; 2009
- 48 Bhave Chittawar P, Franik S, Pouwer AW et al. Minimally invasive surgical techniques versus open myomectomy for uterine fibroids. *Cochrane Database Syst Rev* 2014; 10: CD004638
- 49 DGGG. Indication and operative methods for hysterectomy, 2015. National German Guideline. Long version. AWMF registry no. 015/070. (Manuscript submitted for publication)



- 50 Nieboer TE, Johnson N, Lethaby A et al. Surgical approach to hysterectomy for benign gynaecological disease. *Cochrane Database Syst Rev* 2009; 3: CD003677
- 51 Sinha R, Hegde A, Mahajan C et al. Laparoscopic myomectomy: do size, number, and location of the myomas form limiting factors for laparoscopic myomectomy? *J Minim Invasive Gynecol* 2008; 15: 292–300
- 52 Steiner RA, Wight E, Tadir Y et al. Electrical cutting device for laparoscopic removal of tissue from the abdominal cavity. *Obstet Gynecol* 1993; 81: 471–474
- 53 Brucker S, Solomayer E, Zubke W et al. A newly developed morcellator creates a new dimension in minimally invasive surgery. *J Minim Invasive Gynecol* 2007; 14: 233–239
- 54 Milad MP, Milad EA. Laparoscopic morcellator-related complications. *J Minim Invasive Gynecol* 2014; 21: 486–491
- 55 Brölmann H, Tanos V, Grimbizis G et al. Options on fibroid morcellation; a literature review. *Gynecol Surg* 2014; DOI: 10.1007/s10397-015-0878-4
- 56 Leung F, Terzibachian JJ, Gay C et al. [Hysterectomies performed for presumed leiomyomas: should the fear of leiomyosarcoma make us apprehend non laparotomic surgical routes?]. *Gynecol Obstet Fertil* 2009; 37: 109–114
- 57 Einstein MH, Barakat RR, Chi DS et al. Management of uterine malignancy found incidentally after supracervical hysterectomy or uterine morcellation for presumed benign disease. *Int J Gynecol Cancer* 2008; 18: 1065–1070
- 58 Wright JD, Tergas AI, Burke WM et al. Uterine pathology in women undergoing minimally invasive hysterectomy using morcellation. *JAMA* 2014; 312: 1253–1255
- 59 Major FJ, Blessing JA, Silverberg SG et al. Prognostic factors in early-stage uterine sarcoma. A Gynecologic Oncology Group study. *Cancer* 1993; 71 (4 Suppl.): 1702–1709
- 60 Pritts EA. Obstetrics and Gynecology Devices Panel of the FDA Medical Devices Advisory Committee, July 10, 2014
- 61 Leibsohn S, d'Ablaing G, Mishell DR jr. et al. Leiomyosarcoma in a series of hysterectomies performed for presumed uterine leiomyomas. *Am J Obstet Gynecol* 1990; 162: 968–974; discussion 974–976
- 62 Parker WH, Fu YS, Berek JS. Uterine sarcoma in patients operated on for presumed leiomyoma and rapidly growing leiomyoma. *Obstet Gynecol* 1994; 83: 414–418
- 63 Kamikabeya TS, Etchebehere RM, Nomelini RS et al. Gynecological malignant neoplasias diagnosed after hysterectomy performed for leiomyoma in a university hospital. *Eur J Gynaecol Oncol* 2010; 31: 651–653
- 64 Cantú de León D, González H, Pérez Montiel D et al. Uterine sarcomas: review of 26 years at The Instituto Nacional de Cancerología of Mexico. *Int J Surg* 2013; 11: 518–523
- 65 Leung F, Terzibachian JJ, Aouar Z et al. [Uterine sarcomas: clinical and histopathological aspects. Report on 15 cases]. *Gynecol Obstet Fertil* 2008; 36: 628–635
- 66 Leung F, Terzibachian JJ. Re: "The impact of tumor morcellation during surgery on the prognosis of patients with apparently early uterine leiomyosarcoma". *Gynecol Oncol* 2012; 124: 172–173; author reply 173
- 67 Kido A, Togashi K, Koyama T et al. Diffusely enlarged uterus: evaluation with MR imaging. *Radiographics* 2003; 23: 1423–1439
- 68 Ramm O, Gleason JL, Segal S et al. Utility of preoperative endometrial assessment in asymptomatic women undergoing hysterectomy for pelvic floor dysfunction. *Int Urogynecol J* 2012; 23: 913–917
- 69 Tulandi T, Ferenczy A. Biopsy of uterine leiomyomata and frozen sections before laparoscopic morcellation. *J Minim Invasive Gynecol* 2014; 21: 963–966
- 70 Tamura R, Kashima K, Asatani M et al. Preoperative ultrasound-guided needle biopsy of 63 uterine tumors having high signal intensity upon T2-weighted magnetic resonance imaging. *Int J Gynecol Cancer* 2014; 24: 1042–1047
- 71 Bansal N, Herzog TJ, Burke W et al. The utility of preoperative endometrial sampling for the detection of uterine sarcomas. *Gynecol Oncol* 2008; 110: 43–48
- 72 Rha SE, Byun JY, Jung SE et al. CT and MRI of uterine sarcomas and their mimickers. *AJR Am J Roentgenol* 2003; 181: 1369–1374
- 73 Koyama T, Togashi K, Konishi I et al. MR imaging of endometrial stromal sarcoma: correlation with pathologic findings. *AJR Am J Roentgenol* 1999; 173: 767–772
- 74 Tirumani SH, Ojili V, Shanbhogue AK et al. Current concepts in the imaging of uterine sarcoma. *Abdom Imaging* 2013; 38: 397–411
- 75 Hagemann IS, Hagemann AR, LiVolsi VA et al. Risk of occult malignancy in morcellated hysterectomy: a case series. *Int J Gynecol Pathol* 2011; 30: 476–483
- 76 Montella F, Riboni F, Cosma S et al. A safe method of vaginal longitudinal morcellation of bulky uterus with endometrial cancer in a bag at laparoscopy. *Surg Endosc* 2014; 28: 1949–1953
- 77 Favero G, Anton C, Silva e Silva A et al. Vaginal morcellation: a new strategy for large gynecological malignant tumor extraction: a pilot study. *Gynecol Oncol* 2012; 126: 443–447
- 78 Harter P, El-Khalifaoui K, Heitz F et al. Operative and conservative treatment of uterine sarcomas. *Geburtsh Frauenheilk* 2014; 74: 267–270
- 79 Bonvalot S, Rivoire M, Castaing M et al. Primary retroperitoneal sarcomas: a multivariate analysis of surgical factors associated with local control. *J Clin Oncol* 2009; 27: 31–37
- 80 Oduyebo T, Rauh-Hain AJ, Meserve EE et al. The value of re-exploration in patients with inadvertently morcellated uterine sarcoma. *Gynecol Oncol* 2014; 132: 360–365
- 81 Perri T, Korach J, Sadetzki S et al. Uterine leiomyosarcoma: does the primary surgical procedure matter? *Int J Gynecol Cancer* 2009; 19: 257–260
- 82 Morice P, Rodriguez A, Rey A et al. Prognostic value of initial surgical procedure for patients with uterine sarcoma: analysis of 123 patients. *Eur J Gynaecol Oncol* 2003; 24: 237–240
- 83 Kamp JE, David M, Scheurig-Muenkler C et al. [Clinical outcome of magnetic-resonance-guided focused ultrasound surgery (MRgFUS) in the treatment of symptomatic uterine fibroids]. *Rofo* 2013; 185: 136–143
- 84 van der Kooij SM, Ankum WM, Hehenkamp WJ. Review of nonsurgical/minimally invasive treatments for uterine fibroids. *Curr Opin Obstet Gynecol* 2012; 24: 368–375
- 85 Gupta JK, Sinha A, Lumsden MA et al. Uterine artery embolization for symptomatic uterine fibroids. *Cochrane Database Syst Rev* 2012; 5: CD005073
- 86 Uccella S, Cromi A, Bogani G et al. Transvaginal specimen extraction at laparoscopy without concomitant hysterectomy: our experience and systematic review of the literature. *J Minim Invasive Gynecol* 2013; 20: 583–590
- 87 Brucker SY, Hahn M, Kraemer D et al. Laparoscopic radiofrequency volumetric thermal ablation of fibroids versus laparoscopic myomectomy. *Int J Gynaecol Obstet* 2014; 125: 261–265
- 88 D'Angelo A, Amso NN, Wood A. Uterine leiomyosarcoma discovered after uterine artery embolisation. *J Obstet Gynaecol* 2003; 23: 686–687
- 89 Common AA, Mocarski EJ, Kolin A et al. Therapeutic failure of uterine fibroid embolization caused by underlying leiomyosarcoma. *J Vasc Interv Radiol* 2001; 12: 1449–1452
- 90 American College of Obstetricians and Gynecologists. Informed Consent. 2012. Online: <http://www.acog.org/Resources-And-Publications/Committee-Opinions/Committee-on-Ethics/Informed-Consent>; last access: 01.08.2014
- 91 Paul PG, Koshy AK. Multiple peritoneal parasitic myomas after laparoscopic myomectomy and morcellation. *Fertil Steril* 2006; 85: 492–493
- 92 ESGE Directors and Executive Board. Statement on morcellation. Online: <http://www.esge.org/article/218>; last access: 15.07.2014
- 93 Reiter RC, Wagner PL, Gambone JC. Routine hysterectomy for large asymptomatic uterine leiomyomata: a reappraisal. *Obstet Gynecol* 1992; 79: 481–484
- 94 Takamizawa S, Minakami H, Usui R et al. Risk of complications and uterine malignancies in women undergoing hysterectomy for presumed benign leiomyomas. *Gynecol Obstet Invest* 1999; 48: 193–196