

Radial Medial Head Triceps Branch Transfer to Axillary Nerve by Axillary Approach

Acesso ao nervo axilar por via axilar anterior

José Marcos Pondé¹ Lazaro Santos² João Pedro Magalhaes² Ana Flavia D'Álmeida²

¹ Department of Neurosciences and Mental Health, Universidade Federal da Bahia (UFBA), Salvador, Bahia, Brazil

² Bahian School of Medicine and Public Health, Salvador, Bahia, Brazil

Address for correspondence José Marcos Pondé, MD, PhD, Av. Paulo VI, 111, Pituba, Salvador, BA, Brazil 41810-000

(e-mail: vesalio@terra.com.br).

Arq Bras Neurocir 2015;34:134–138.

Abstract

Objective To describe axillary approach for axillary nerve transfer with radial nerve branch in brachial plexus lesions.

Methods Six patients aged 24 to 54 (mean 30) years with traumatic superior trunk brachial plexus injury underwent axillary approach between October 2011 and April 2012. On physical examination prior to surgery, they could not perform shoulder abduction, external rotation, or elbow flexion. Surgical approach was made through axillary pathway without any muscular section. The transfer was done with the radial branch to the medial head of triceps. In addition to transfer to axillary nerve, each patient had spinal accessory nerve transferred to suprascapular nerve and ulnar nerve fascicle transferred to musculocutaneous nerve.

Conclusion The axillary approach allows easy access to axillary nerve and, therefore, is a feasible pathway to transferences involving this nerve.

Keywords

- ▶ axillary nerve
- ▶ brachial plexus
- ▶ transfer

Resumo

Objetivo Apresentar via axilar por transferência de nervo axilar com ramo de nervo radial em lesões do plexus braquial.

Métodos Seis pacientes com idade entre 24 e 54 anos (média de 30) com lesão braquial traumática do plexus no tronco superior submetidos a via axilar entre outubro de 2011 e abril de 2012. Em exame físico pré-cirúrgico, não foram capazes de executar abdução do ombro, rotação externa, ou flexão do cotovelo. Abordagem cirúrgica foi realizada por passagem axilar sem qualquer seção muscular. A transferência ocorreu com o ramo radial do tríceps medial da cabeça. Somada à transferência ao nervo axilar, cada paciente teve nervo acessório espinal transferido para o nervo supraescapular, e o fascículo do nervo ulnar transferido para o nervo musculocutâneo.

Conclusão A via axilar facilita acesso ao nervo axilar e, por isso, é um caminho factível para transferências envolvendo este nervo.

Palavras chave

- ▶ nervo axilar
- ▶ plexus braquial
- ▶ transferência



Table 1 Patients muscle strength grade in triceps

| Patient no. | Age (y) | Side involved | Interval from injury to surgery (mo) | Follow-up (mo) | Additional nerve transfers | Mechanism of injury | Abduction (degree) | Follow-up (mo) |
|-------------|---------|---------------|--------------------------------------|----------------|----------------------------|---------------------|--------------------|----------------|
| 1 | 24 | R | 9 | 2 | Ac.-S.S, Oberlin | Motorcycle | 120 | 24 |
| 2 | 24 | R | 7 | 5 | Ac.-S.S, Oberlin | Motorcycle | 120 | 18 |
| 3 | 25 | L | 6 | 3 | Ac.-S.S, Oberlin | Motorcycle | 120 | 18 |
| 4 | 28 | L | 12 | 2 | Ac.-S.S, Oberlin | Motorcycle | 90 | 22 |
| 5 | 32 | R | 3 | 6 | Ac.-S.S, Oberlin | Motorcycle | 30 | 18 |
| 6 | 54 | R | 6 | 2 | Ac.-S.S, Oberlin | Bike | 90 | 18 |

Introduction

Restoration of shoulder function is one of the most critical goals of treatment of brachial plexus injuries. Primary repair or nerve grafting for avulsion injuries of the upper brachial plexus in adults often leads to poor recovery. Nerve transfers have provided an alternative treatment with great potential for improved return of function. Many different nerves have been utilized as donor nerves for transfer to the suprascapular nerve and axillary nerve for return of shoulder function with variable results. This article presents a straightforward access to the axillary nerve by means of an unusual route combined with Oberlin surgery.

Usually the approach for transference of the axillary nerve is made by means of the posterior route to transfer a branch of the radial nerve to it.

This implies in case of the necessity in the same surgery to make the transference of the musculocutaneous nerve with an ulnar fascicle (Oberlin surgery) to make a second incision, invariably turning the side of the arm and sometimes the position of the patient.

During the axillary approach this is not necessary because the same incision can be undertaken.

Method

From October 2011 to April 2012, six men aged 24 to 54 years (mean 30) with traumatic brachial plexus injury underwent nerve transfer through anterior axillary approach. The patients were clinically and electrophysiologically evaluated; with nerve root injury confirmed in the right shoulder (four patients) and left shoulder (two patients). They had impaired shoulder abduction, external rotation, and elbow flexion. All patients had at least a grade 4 muscle strength in the triceps (► **Table 1**).

The mean time from injury to surgery was 6 months, ranging from 3 to 12 months.

Six patients with traumatic superior trunk lesion were treated with connection of a fascicle of ulnar nerve to musculocutaneous nerve (Oberlin surgery), accessory to suprascapular nerve connection, and connection of the

radial branch to the medial portion of triceps to anterior axillary branch.

The approach to the suprascapular nerve was made in the supraclavicular region with a transverse incision 2 cm above the clavicle and dissection of the superior trunk. The accessory spinal nerve was transferred in all cases to the suprascapular nerve.

The approach to the musculocutaneous nerve was made in the superior medial third of the arm with connection of a fascicle of the ulnar nerve with the biceps branch of the receptor nerve.

Under general anesthesia the patients were placed in supine position with the arm abducted and externally rotated. A longitudinal incision of approximately 10 to 15 cm in length was made along a line falling inferiorly to the biceps muscle until reaching the border of pectoral major muscle (► **Fig 1**). Dissection was performed carefully, leaving the vascular and neural structures laterally to expose the quadrangular space, which is limited downward by the latissimus dorsi and teres major muscles, upward by the teres minor muscle, laterally by the humerus, and medially by the triceps muscle.

The posterior circumflex artery is isolated, and the axillary nerve beside it, identified. Both nerves' branches to the medial head of the triceps are isolated, running closely adjacent to the radial nerve although distinctly separated from it. The radial nerve was dissected while the upper motor branch to the medial head triceps was individualized and stimulated electrically for proper identification (► **Fig 2**). It was sectioned and sutured to the anterior division of the axillary nerve under magnification with 10-0 nylon and fibrin glue.

In one patient, a connection between the medial portion of the radial nerve and the entire axillary trunk was performed, because the donor nerve was very thickened.

The patients were discharged home after 2 days of surgery.

Results

Palpable contraction of deltoid muscle was noted in all patients 4 months after surgery.

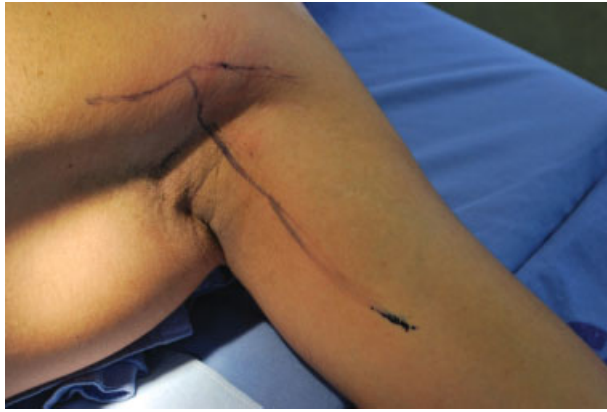

Fig. 1 Incision in the arm.

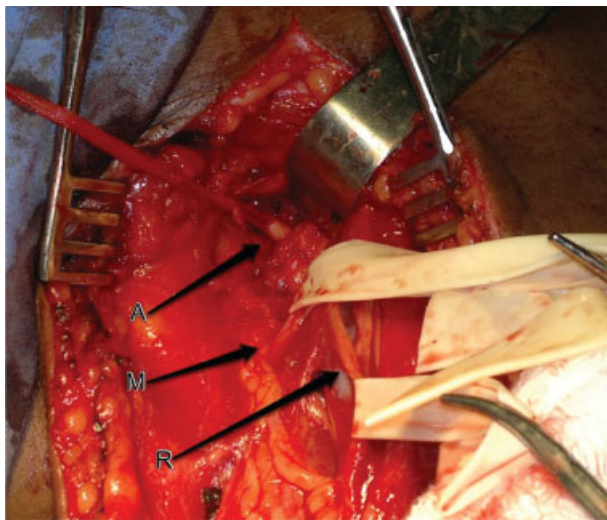


Fig. 2 Surgical approach with the axillary nerve in the left side (A), the branch of the radial to the medial head of triceps (M), and the radial nerve (R).

One patient had subcutaneous infection. He was treated with antibiotics and surgical debridement with good outcome.

Following a mean of 14 to 18 months after the surgery, all patients except 1 showed improvement in abduction of the arm above 90 degrees. Deltoid strength was M4 in all patients. Only two patients acquired external rotation of 30 and 45 degrees.

Discussion

Disruption of the C5 and C6 roots results in loss of supply to muscles innervated by the suprascapular nerve, axillary nerve, and musculocutaneous nerve. With particular regard to shoulder abduction, it is not uncommon for the axillary nerve (C5, C6) component of the posterior cord to be compromised, whereas the radial nerve (C5, C6, C7, C8, T1) component remains intact because of its more plentiful nerve root sources.¹

In cases of lesions of the upper trunk, there are usually three options: arthrodesis, nerve transfer, and tendon transfer. Arthrodesis sacrifices abduction, otherwise providing stability of the shoulder.

Satisfactory results are obtained with trapezius, sternocleidomastoid, levator scapulae, and latissimus dorsi transfer, but local nerve transfers are preferred to avoid biomechanical alterations.^{2,3} The main priorities in nerve transfer are elbow flexion and arm abduction.⁴⁻⁸ Procedures have used donors to axillary nerve from the intercostal nerves^{9,10} thoracodorsal nerve,¹⁰ medial pectoral nerve,^{10,11} long thoracic nerve,¹⁰ phrenic nerve,⁹ distal accessory nerve,⁹ ipsilateral C7 root,¹² contralateral C7,¹³ suprascapular nerve,¹⁴ and hypoglossal nerve.¹⁵ Usually, the transfer of radial branches to axillary nerve are carried out by means of the posterior approach with an incision between the deltoid and triceps.¹

The anterior approach was described using the deltopectoral groove pathway¹⁵ with few reports of transaxillary approach.¹⁶ The section of muscle can be necessary in both usually described surgical approaches. In the anterior approach, the minor pectoralis muscle is sectioned closely to the coracoid process to access the infraclavicular plexus. In the posterior approach, the incision is made in the posterolateral surface of the arm and sometimes is necessary to proceed the section of teres major muscle increasing the quadrangular space for a better nerve cooptation between the radial branch and the axillary nerve.^{1,8} Consequently the axillary approach is a straightforward access to the axillary region without any muscular section.

A natural route across the armpit is done, improving the quality of this approach, with less tissue aggression. The radial nerve branch to the medial portion of the triceps is sectioned the more distant as possible, bringing it in the opposite direction upward the axillary nerve. The connection is carried out without any tension. We attended the policy of bringing more proximal as possible the receptor nerve and leaving more distant as possible the donor nerve.

All the patients operated upon by this approach were also submitted to Oberlin technique¹⁷ and spinal accessory to suprascapular transfer. To suprascapular reinnervation, another incision should be made usually in the supraclavicular lesion or over the scapulae in the posterior approach.

When the Oberlin surgery is not intended, we usually prefer the posterior approach, following the scientists' recommendation.^{17,18}

An anatomical study previously done showed the feasibility of the proceeding and the same authors operated upon three patients by means of this technique.¹⁶

Eighteen months after surgery, all three patients had recovered deltoid strength to a score of M4 on the Medical Research Council scale and had improved abduction strength by 50%.¹⁶

Reinnervation of suprascapular nerve alone seems to yield better results than reinnervation of the axillary nerve in the same situation.¹

Both approaches work with the objective of reinnervating the supraspinatus and deltoid muscle, respectively.

Leechavengvongs et al¹⁸ believe that the difference in the results between suprascapular and axillary nerve transfer may be because that nerve transfer to the axillary nerve always requires a longer nerve graft than that is necessary to accessory-suprascapular nerve coaptation.

In our opinion, this is a matter of discussion because similar results of reinnervation of suprascapular nerve were obtained through an anterior supraclavicular approach or a posterior approach with different distances to the end motor plaque.

In the paper of Jerome that describes an approach across the deltopectoral groove, a longer distance between the radial branch and the axillary nerve than in the posterior approach, the mean value of abduction was 133 degrees.

Many authors report good results with double transfers.^{9,11,17-19}

Nath and Mackinnon²⁰ called attention to a favorable outcome of a motor transfer nerve like the use of the radial branch to the triceps for the following reasons:

1. Proximity to neuromuscular junction of the deltoid muscle
2. Negligible deficit of function following donor nerve section
3. Pure motor donor nerve
4. It has many axons
5. Synergistic function

Some authors argue that the long portion of the triceps contributes substantially to the shoulder joint physiology. The long head of the triceps is generally the largest of the three, and in contrast to the other two heads, it provides some stability of humeroscapular adduction as it originates from the infraglenoid tubercle of the scapula. This is why Mackinnon et al prefer the medial branch instead of long head branch.

Neither sections of the medial or lateral or long head motor branch decrease muscle strength.^{4,18,21}

According to Zhang and Nuber the uniarticular triceps lateral and medial heads contribute 70 to 90% to isometric elbow extension. The anconeus contributes 15% at lesser degrees of elbow extension. The long head becomes active only with forceful elbow extension.^{22,23}

According to Bertelli et al,¹⁶ the triceps long head function is dependent on shoulder position and that is particularly active when the shoulder is fully abducted. Their preference is to use the long head motor branch.

There is no consensus regarding what division of the axillary nerve must be reinnervated. The anterior branch contains all fibers that innervate the anterior and middle deltoid muscle. The posterior branch contains fibers that supply the posterior deltoid in 90% of cases.¹⁸ Nerve fibers to the teres minor and cutaneous sensory fibers are also found in the posterior branch.

External shoulder rotation is a critical element of function and an important goal of reconstruction. The teres minor provides two important functions: glenohumeral capsular stability and external rotation. After crossing the quadrangular space, two branches of the axillary nerve are soon individualized, one to deltoid muscle and the other to teres minor muscle. Given the importance of the innervated

muscle by the teres minor for shoulder stability and external rotation, Mackinnon et al include teres minor in the reconstructive effort.

Conclusion

The axillary approach described herein is a safe and reliable route to surgery for axillary nerve transfer in brachial plexus injury. Our primary indication is an attempt to do simultaneously transference of ulnar to musculocutaneous nerve in the arm, using the same incision.

References

- 1 Colbert SH, Mackinnon S. Posterior approach for double nerve transfer for restoration of shoulder function in upper brachial plexus palsy. *Hand (NY)* 2006;1(2):71-77
- 2 Hallock GG. The triceps muscle flap for axillary contracture release. *Ann Plast Surg* 1993;30(4):359-362
- 3 Sundine MJ, Malkani AL. The use of the long head of triceps interposition muscle flap for treatment of massive rotator cuff tears. *Plast Reconstr Surg* 2002;110(5):1266-1272, discussion 1273-1274
- 4 Bertelli JA, Ghizoni MF. Reconstruction of C5 and C6 brachial plexus avulsion injury by multiple nerve transfers: spinal accessory to suprascapular, ulnar fascicles to biceps branch, and triceps long or lateral head branch to axillary nerve. *J Hand Surg Am* 2004;29(1):131-139
- 5 Bertelli JA, Ghizoni MF. Improved technique for harvesting the accessory nerve for transfer in brachial plexus injuries. *Neurosurgery* 2006;58(4, Suppl 2):ONS-366-ONS-370, discussion ONS-370
- 6 Mackinnon SE, Novak CB. Nerve transfers. New options for reconstruction following nerve injury. *Hand Clin* 1999;15(4):643-666, ix
- 7 Mackinnon SE, Novak CB, Mykатыn TM, Tung TH. Results of reinnervation of the biceps and brachialis muscles with a double fascicular transfer for elbow flexion. *J Hand Surg Am* 2005;30:978-985
- 8 Oberlin C, Béal D, Leechavengvongs S, Salon A, Dauge MC, Sarcy JJ. Nerve transfer to biceps muscle using a part of ulnar nerve for C5-C6 avulsion of the brachial plexus: anatomical study and report of four cases. *J Hand Surg Am* 1994;19(2):232-237
- 9 Chuang DC-C, Lee GW, Hashem F, Wei F-C. Restoration of shoulder abduction by nerve transfer in avulsed brachial plexus injury: evaluation of 99 patients with various nerve transfers. *Plast Reconstr Surg* 1995;96(1):122-128
- 10 Samardzic M, Grujicic D, Antunovic V. Nerve transfer in brachial plexus traction injuries. *J Neurosurg* 1992;76(2):191-197
- 11 Samardzic M, Grujicic D, Rasulic L, Bacetic D. Transfer of the medial pectoral nerve: myth or reality? *Neurosurgery* 2002;50(6):1277-1282
- 12 Gu YD, Cai PQ, Xu F, Peng F, Chen L. Clinical application of ipsilateral C7 nerve root transfer for treatment of C5 and C6 avulsion of brachial plexus. *Microsurgery* 2003;23(2):105-108
- 13 Siqueira M, Martins R. Lesões do Plexo Braquial 2011 Rio de Janeiro Brasil DILIVROS404 P.
- 14 Malessy MJA, Hoffmann CFE, Thomeer RTWM. Initial report on the limited value of hypoglossal nerve transfer to treat brachial plexus root avulsions. *J Neurosurg* 1999;91(4):601-604
- 15 Jerome JT. Anterior deltopectoral approach for axillary nerve neurotisation. *J Orthop Surg (Hong Kong)* 2012;20(1):66-70
- 16 Bertelli JA, Kechele PR, Santos MA, Duarte H, Ghizoni MF. Axillary nerve repair by triceps motor branch transfer through an axillary

- access: anatomical basis and clinical results. *J Neurosurg* 2007; 107(2):370-377
- 17 Merrell GA, Barrie KA, Katz DL, Wolfe SW. Results of nerve transfer techniques for restoration of shoulder and elbow function in the context of a meta-analysis of the English literature. *J Hand Surg Am* 2001;26(2):303-314
 - 18 Leechavengvongs S, Witoonchart K, Uerpaiojkit C, Thuvasethakul P. Nerve transfer to deltoid muscle using the nerve to the long head of the triceps, part II: a report of 7 cases. *J Hand Surg Am* 2003;28(4):633-638
 - 19 Lurje A. Concerning surgical treatment of traumatic injury of the upper division of the brachial plexus (Erb's-type). *Ann Surg* 1948; 127(2):317-326
 - 20 Nath RK, Mackinnon SE. Nerve transfers in the upper extremity. *Hand Clin* 2000;16(1):131-139, ix
 - 21 Witoonchart K, Leechavengvongs S, Uerpaiojkit C, Thuvasethakul P, Wongnopsuwan V. Nerve transfer to deltoid muscle using the nerve to the long head of the triceps, part I: an anatomic feasibility study. *J Hand Surg Am* 2003;28(4): 628-632
 - 22 Zhang LQ, Nuber GW. Moment distribution among human elbow extensor muscles during isometric and submaximal extension. *J Biomech* 2000;33(2):145-154
 - 23 van Groeningen CJ, Erkelens CJ. Task-dependent differences between mono- and bi-articular heads of the triceps brachii muscle. *Exp Brain Res* 1994;100(2):345-352