

CERVICO-FACIAL HEMANGIOMAS; THE TREATMENT THAT ELUDES US

S.M. Sharma

Professor & H.O.D, Dept.of Oral and Maxillo Facial Surgery
A.B. Shetty Memorial Institute of Dental Sciences,
Nitte University, Deralakatte, Mangalore - 575 018

Abstract

Cervicofacial hemangiomas treated from January 2001 to December 2009 was clinically evaluated. This retrospective clinical study consisted of 42 females and 20 males with the age ranged from 20 days to 55 years. The lesions were present with-in first month in 45 patients (72.6%). Two patterns of tumor growth were evident: focal and diffuse. There were 59 focal hemangiomas (80.8%) and 14 diffuse hemangiomas (19.2%). Complications noted at the time of first consultation include residual skin changes in the in 35 patients (56.5%), obstruction of orifices in 14 patients (22.6%), ulceration in 6 patients (9.7%), and infection occurred in 2 patients (3.2%). Overall, there is reduction in size and improvement in color and texture of lesion following intervention in each group. No significant difference in outcome was observed in between groups with respect to change in size and texture. However, improvement in color showed statistically significant difference and combined treatment modality and surgical treatment was found to be better.

Keywords : Hemangioma, cervicofacial, management, challenges in treatment, .

Introduction

The most common congenital deformity observed in infants and children are the Cervico-facial Vascular anomalies. They frequently involve the head, neck, and oral cavity.¹ In 1982, Mulliken & Glowacki² classified childhood vascular lesions as either hemangiomas or malformations. This classification was ground breaking and has served as a cornerstone for the proper identification, investigation, and management of vascular birthmarks. More specifically, hemangiomas were differentiated from vascular malformations by their clinical appearance, histopathologic features, and biologic behaviour.

Hemangioma is the most common tumor in infancy, with a perinatal incidence of 1% to 3%^{3,4} and affecting 10% of infants by one year of age^{5,6}. They are speculated to affect 4% to 12% of white children.⁵ The incidence seems to be lower in Asian infants and is low in children of African decent⁷. Up to 30% of preterm infants with low birth weight (<1000g) may have hemangioma⁸. A predilection for the female sex has been reported, with a ratio of 2:1 to 5:1⁹⁻¹¹.

The hallmark of hemangiomas is rapid growth during the first several months of the child's life. When involution occurs, the process is usually completed by the child's seventh year. Therefore, a strong opinion developed in the mid-20th century that appropriate treatment for hemangioma was no treatment, this became known as benign neglect¹². However, symptomatic problems such as ulceration, bleeding, infection, and residual skin changes which may be disfiguring require early intervention¹³. Also children begin to develop self awareness at 18 to 24 months of age¹⁴. Therefore, the psychosocial impact on a child with facial hemangiomas or its resultant scar cannot be underestimated¹⁵. The past decade has witnessed a revolution in the understanding and treatment of these vascular lesions. Previous complacency in treatment is changing to a more proactive approach to circumvent immanent aesthetic sequelae. Williams et al¹⁶ developed a useful approach to the management of hemangiomas based on the stage of the lesion (proliferative or involutive phase), type of lesion (superficial, deep, compound) and the management of residual deformity. Freiden et al¹⁷ stated major goals of management of hemangioma of infancy

are (1) to prevent or reverse any life-threatening complications of hemangiomas; (2) to prevent permanent disfigurement left by residual skin changes following involution; (3) to minimize the psychosocial distress from the presence of hemangiomas for both patient and family; (4) to avoid overly aggressive, potentially scarring procedures or toxic therapies for the treatment of those hemangiomas that are likely to have an excellent prognosis without therapy; and (5) to prevent or adequately treat ulcerated hemangiomas so that scarring, infection, and pain are minimized.

A number of treatment modalities are available for the management of hemangiomas. These include observation, compression¹⁸, corticosteroids - systemic¹⁹⁻²⁴, intralesional²³⁻²⁶ and topical therapy²⁷; sclerotherapy²⁸, interferon α -2a²⁹, laser therapy^{30,31}, vincristine³², becaplermin gel³³, and β -blockers^{34,35}. Surgical treatment includes intratumoral ligation³⁶, tobacco-pouch suture technique³⁷, and excision³⁸⁻⁴⁵. The question is how to identify those lesions that are most likely to require treatment and also which treatment modality is best suited for a particular individual. Therefore, a study that will characterize various features of hemangiomas, discussing various therapeutic options with emphasis on the timing of intervention, and also focusing on correlation between various managements of hemangiomas remains elusive.

Material and methods

A retrospective clinical study of patients with confirmed diagnosis of Cervicofacial hemangiomas reported from January 2001 to December 2009 was done in the department of Oral and Maxillo-Facial surgery. The following information was recorded from each patient's medical records, operative notes, investigations and clinical photographs: i) Age, ii) Sex, iii) Onset of hemangiomas, iv) Anatomic location, v) Size of hemangioma, vi) Complications noted at the time of consultation, vii) Type of treatment, and viii) Time period

of treatment.

Each patient was then assigned to different treatment groups based on type of treatment done, like: group I, steroid treatment (figure 1); group II, sclerotherapy (figure 2); group III, surgical treatment (figure 3); group IV, combined therapy (figure 4).

Final results for each patient were assessed on available pretreatment data and present post treatment outcome based on: I) Reduction in size of tumor, II) Improvement in texture, and IV) Improvement in color. The results were analyzed by a single observer using the following scales: 1) poor (0 to 25 percent), 2) fair (26 to 50 percent), 3) good (51 to 75 percent), and 4) excellent (76 to 100 percent). Results of each of these parameters were summarized by groups. Finally, comparison of the outcomes between groups was analyzed by means of Chi-square statistical test. $p < 0.05$ was considered to be statistically significant.

Results

Over a period of eight years from January 2001 to December 2009, 62 patients with 73 hemangiomas were reviewed. The age of these patients ranged from 20 days to 55 years with the average being 9 years and 6 months. The gender distribution was 42 females and 20 males with the ratio being 2.1:1. The lesions were present at birth in 7 patients (11.3%), within first month in 45 patients (72.6%), and after first month in 10 patients (16.1%). The involved area of hemangiomas in each group was as follows: group I, 0.25 to 120 cm²; group II, 3.0 to 140 cm²; group III, 1.0 to 180 cm²; group IV 3.0 to 225 cm². The mean and median for each group, respectively, were group I, 6.2 cm² and 6 cm²; group II, 20.5 cm² and 24 cm²; group III, 12.3 cm² and 15.5 cm²; group IV, 21.2 cm² and 22 cm².

Two patterns of tumor growth were evident: focal and diffuse. There were 59 focal hemangiomas (80.8%) and

14 diffuse hemangiomas (19.2%). Focal hemangiomas were mapped to 15 sites of occurrence, the most common being lateral upper lip in 15 patients (25.4%), lower lip in 14 patients (23.7%), mid-cheek in 7 patients (11.9%), and nasal tip in 5 patients (10.2%) (Table 1). The most common sites for segmental hemangiomas were maxillary segment in 6 patients (42.9%), mandibular segment in 5 patients (35.7%), and frontonasal segment (21.4%) (Table 2).

Complications noted at the time of first consultation include residual skin changes in the form of fibro-fatty masses of tissue in 35 patients (56.5%). Obstruction of orifices was present in 14 patients (22.6%). They were the eye (3), mouth (5), and nose (6). Ulceration was seen in 6 patients (9.7%). Infection occurred in 2 patients (3.2%) & was secondary to previous ulceration (Table 3).

Management of the hemangiomas and mean age of treatment in each group is summarized in Table 4. The time period of treatment ranged from 1 month to 4 years

2 months with the mean period in each group as follows: group I – 1 year 8 months, group II – 1 year 2 months, group III – 1 year 4 months, and group IV – 2 years 6 months.

The final results of each of the three parameters are also summarized by group (Table 5). Statistically no significant difference was obtained in reduction in size of tumor ($p=0.683$). With respect to improvement in texture, also no statistically significant difference was observed ($p=0.152$). However improvement in color resulted in statistically significant difference ($p=0.006$). Comparison of treatment outcome with respect to improvement in color amongst the groups yielded significant difference in outcome between group III (surgical treatment) and group II (sclerotherapy) ($p=0.037$), as well as between group IV (combined modality treatment) and group III ($p=0.005$). Surgical treatment was found to be better compared to sclerotherapy and combined modality treatment was better when compared to surgical treatment alone.

Distribution of focal	Frequency	Percentage
Lateral forehead over eyebrow	1	1.7
Nasal bridge/ glabella	3	5.1
Lateral nasal bridge	2	3.4
Directly beneath eye	1	1.7
Nasolabial fold	1	1.7
Mid cheek	7	11.9
Nasal (alar)	2	3.4
Nasal tip	5	8.5
Columella	2	3.4
Philtrum	3	5.1
Lateral upper lip	15	25.4
Lateral lower lip	14	23.7
Chin	1	1.7
Preauricular area	1	1.7
Ear	1	1.7

Table 1: Distribution of focal hemangiomas

Segmental hemangiomas	Count	Percentage
Frontonasal	3	21.4
Maxillary	6	42.8
Mandibular	5	35.7

Table 2: Distribution of segmental hemangiomas

	Group I (n= 11)	Group II (n=9)	Group III (n=22)	Group IV (n=20)	Total (n=62)
Fibro-fatty tissue	0	5	16	14	35
Obstruction	4	2	3	4	13
Ulceration	3	1	1	1	6
Infection	1	0	0	1	2
Number (%) of patients	8(72.7)	8(88.9)	20(91)	20(100)	56(90.3)

Table 3: Complications noted at the time of first consultation

Group		Number (n=62)	Percentage (100%)	Minimum age	Maximum age	Mean age
I	Steroid treatment			20 days	1 year	5 months
					4 months	
	1. Oral administration	3	4.8			
	2. Intralesional administration	8	12.9			
II	Sclerotherapy	9	14.5	2 years	35 years	12 years
				1 month		
III	Surgical treatment	22	35.5	1 year	55 years	8 years
				6 months		6 months
IV	Combined modality			1 year	38 years	14 years
				6 months		6 months
	1. Sclerotherapy + surgical treatment	14	22.6			
	2. Steroid treatment + surgical treatment	6	9.7			

Table 4: Management of hemangiomas of infancy

Type	Group	Poor	Fair	Good	Excellent
Volume	I	2	3	4	2
	II	1	3	3	2
	III	2	6	8	6
	IV	0	3	8	9
Color	I	1	3	7	0
	II	2	1	5	1
	III	0	11	7	4
	IV	0	1	14	5
Texture	I	0	7	3	1
	II	1	4	4	0
	III	0	8	12	2
	IV	0	4	13	3

Table 5: Final outcome of the number of patients in each group

Discussion

The management of hemangiomas has been a subject of intense controversy for many decades. They are remarkably heterogeneous in terms of size, location, rate of growth and involution. Despite, the benign and trivial nature of most hemangiomas, a significant minority, cause functional compromise, or permanent disfigurement. They are also notoriously unpredictable early in infancy: some barely grow, while others blossom forth into huge tumors. Therefore, the treatment of vascular lesions has undergone a revolution in clinical practice in the past decades which remains elusive. Earlier intervention and advanced therapeutic modalities have permitted the patient and family, the opportunity to remove the hemangioma earlier and more effectively and, thereby, to mitigate the aesthetic

and psychological impact that the hemangiomas may otherwise have.

The aim of this study was to characterize hemangiomas depending upon the onset, gender distribution, anatomic location, and associated complications as well as to evaluate the treatment outcomes following various managements. The ratio of female to male in our group of patients was 2.1: 1, and was similar to the ratio generally reported in the literature of 2:1 to 5:1^{2,9,10,11,44}.

The age of these patients ranged from 20 days to 55 years with the average being 9 years and 6 months. Achauer et al⁴⁴ reported patients from 1 day to 59 years with the average age being 4 years and 7 months. The average age in present group was more because patients reported to our hospital after the complications had developed.

Hemangiomas usually appear soon after birth in 60% to 70% of patients². In this study also, majority of the hemangiomas arise soon after birth within first month in 72.6% of patients. Thus, it can be concluded that infantile hemangioma usually arise after birth in majority.

Waner et al⁴⁶ mapped sites of occurrence of facial infantile hemangiomas and analyzed two patterns of tumor growth: focal (177 lesions [76.3%]) and diffuse (55 lesions [23.7%]). Hagstrom et al⁴⁷ described four primary segments – frontotemporal, maxillary, mandibular and frontonasal involved in segmental infantile hemangiomas. In present study among 73 hemangiomas, there were 59 focal hemangiomas (80.8%) and 14 diffuse hemangiomas (19.2%). The focal hemangiomas were mapped to 15 sites of occurrence, the most common being lateral upper lip in 15 patients (25.4%), lower lip in 14 patients (23.7%), mid-cheek in 7 patients (11.9%), and nasal tip in 5 patients (10.2%). The segmental hemangiomas are maxillary segment in 6 patients (42.9%), mandibular segment in 5 patients (35.7%) and frontonasal segment (21.4%). Thus it can be concluded that infantile hemangiomas involving face have two distinct patterns of involvement with focal type predominating.

Our study demonstrates non treatment rate of complications at initial consultation was of 90%. This large rate of complications noted at the time of first consultation is definitely due to the fact that these patients seek treatment after complications had developed. Residual skin changes in the form of fibrofatty masses of tissue in 35 patients (56.5%).

Obstruction of orifices was present in 14 patients (22.6%). They were the eye (3), mouth (5), and nose (6). Ulceration was seen in 6 patients (9.7%). Infection occurred in 2 patients (3.2%) and was secondary to previous ulceration. Thus, it can be concluded that obstruction and ulceration are the most common

indication for management of hemangiomas during proliferative phase.^{16,17}

Our study showed that reduction in size of tumor in steroid treatment group was excellent in 2, good in 4, fair in 3, and poor in 2 patients. With regards to improvement in color good outcome was observed in 7, fair in 3, and poor in 1 patient. Improvement in texture was excellent in 6, good in 32, fair in 23, and only 1 patient had poor result. Also, the mean age of treatment in this group was 5 months. Hence, steroids resulted in improved outcome if treatment is recommended during proliferative phase.¹⁹⁻²⁷

Most of the patients in our study received sclerotherapy, surgical treatment or combined approach, as they reported to us during involuting or involuted phase and with residual skin changes. In 9 patients who received sclerotherapy, reduction in volume was excellent in 2, good in 3, fair in 3, and poor in 1 patient. Improvement in color was excellent in 1, good in 5, fair in 1, and poor in 2 patients and improvement in texture was good in 4, fair in 4, and poor in 1 patient. The mean age of treatment in this group was 12 years. In a study by Kane et al²⁸, sclerotherapy with sodium tetradecyl sulfate was used solely in 12 patients and resulted in a favorable outcome. Surgery and combined modality approach resulted in improved outcome in majority of patients either in proliferative, involuting or involuted phase. This is similar to studies done by Kane et al²⁸, Achauer et al⁴⁴, Demiri et al⁴⁵.

Comparison of treatment between groups yielded no significant difference in outcome with respect to change in size and texture. However, improvement in color showed statistically significant difference and combined treatment modality and surgical treatment was found to be better. This indicates that proper selection of a particular treatment modality during course of hemangioma is important for a favorable outcome.

Conclusion

The successful treatment of cervicofacial hemangiomas is guided by an understanding of tumour natural history and ultimately judged by an improvement in function and appearance of the patient. Given their inherent heterogeneity, developing a rationale for interventions can be challenging; however, management of these lesions should ultimately be determined on the individual basis. Safe, active intervention is possible

during all stages of development of hemangiomas. Therefore, treatment should be started early in the course of hemangioma as it will be more successful in preventing scarring, disfigurement, and life or function threatening sequelae and also in alleviating psychosocial burden of disease carried by the child and the family. It should, however be kept in mind that whatever action is undertaken should in no way result in a worse outcome than that which is seen with natural involution.

Group I: Steroid treatment

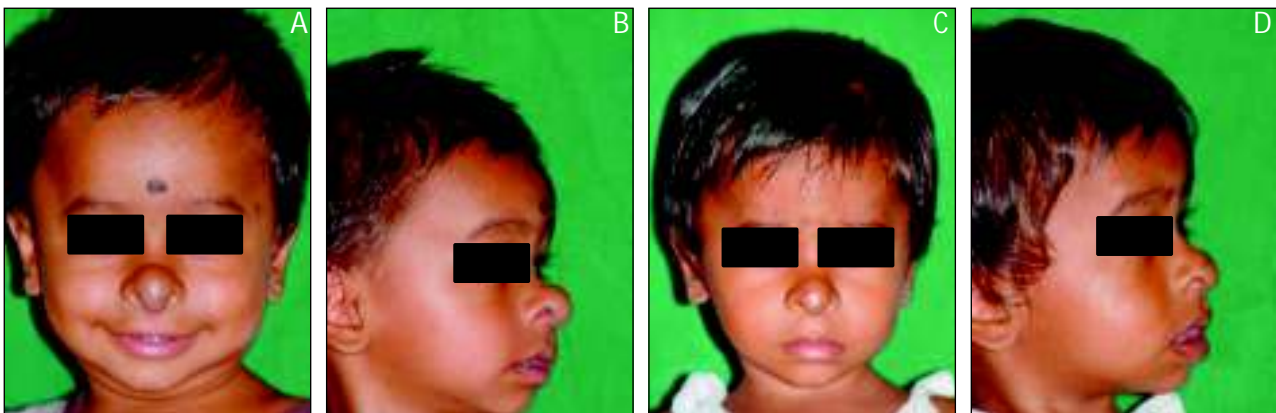


Figure 1: Pretreatment photographs of a child with hemangioma at tip of nose in A) frontal view and B) lateral view. Post steroid treatment follow – up photographs of same patient in C) frontal view and D) lateral view.

Group II: Sclerotherapy

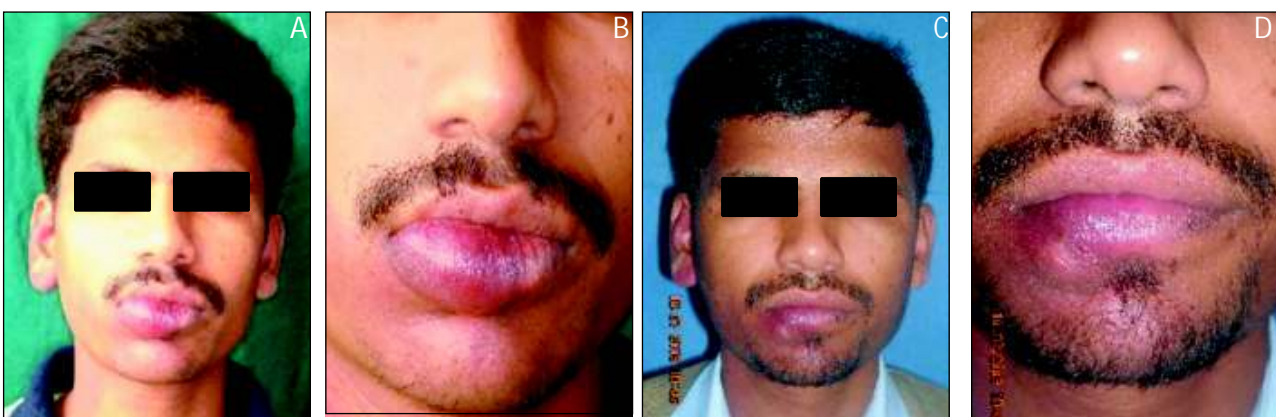


Figure 2: Pretreatment photographs of a patient with hemangioma on lateral portion of lower lip in A) frontal view and B) close-up view. Post sclerotherapy follow – up photographs of same patient in C) frontal view and D) close-up view.

Group III: Surgical treatment

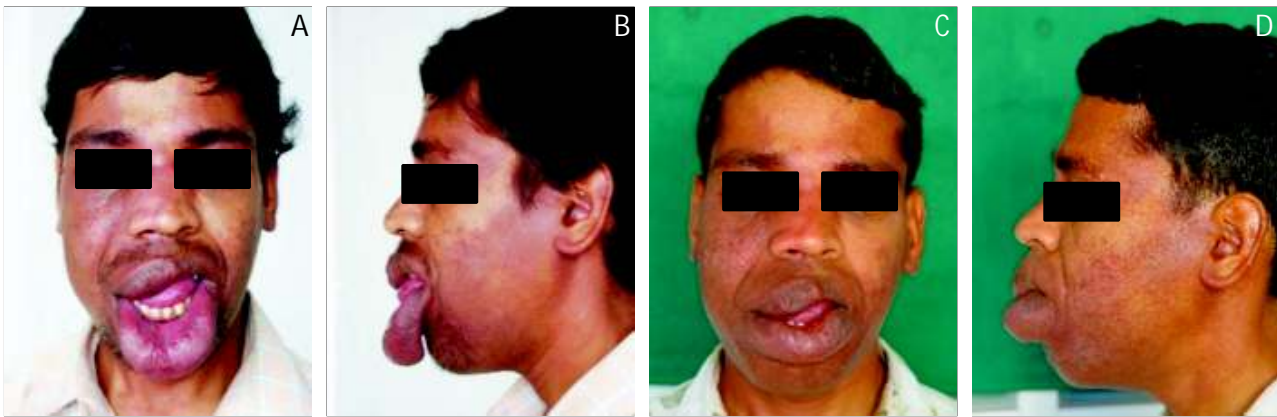

Figure 3: Pretreatment photographs of a patient with massive hemangioma involving lower lip and lateral upper lip in A) frontal view and B) profile view. Follow – up photographs of same patient following surgical treatment in C) frontal view and D) profile view.

Group IV: Combined treatment

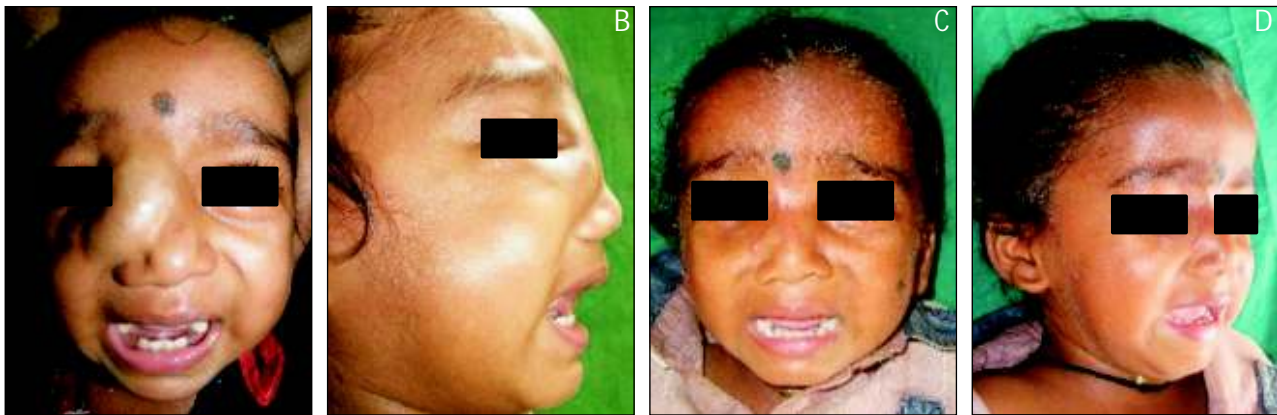

Figure 4: Pretreatment photographs of a child with hemangioma at the base of nose in A) frontal view and B) profile view. Follow – up photographs of same patient following steroid treatment and surgical resection in C) frontal view and D) lateral view.

References

- Mulliken JB, Young AE. Vascular birthmarks: hemangiomas and malformations. Philadelphia: Saunders; 1988.
- Mulliken JB, Glowacki J. Hemangiomas & vascular malformations in infants and children: a classification based on endothelial characteristics. *Plast Reconstr Surg* 1982;69:412-20.
- Pratt AG. Birthmarks in infants. *Arch Dermatol* 1967;67:302-305.
- Jacobs AH, Walton RG. The incidence of birthmarks in the neonates. *Pediatrics* 1976;58:218-222.
- Holmdahl K. Cutaneous hemangiomas in premature and young infants. *Acta Paediatr Scand* 1955;44:370-9.
- Jacobs AH. Strawberry hemangioma: The natural history of the untreated lesion. *Calif Med*. 1957;86: 8–10.
- Amir J, Metzker A, Krikler R. Strawberry hemangioma in preterm infants. *Pediatr Dermatol* 1986;3:331–332.
- Hidano A, Nakajima S. Earliest features of the strawberry mark in the newborn. *Br J Dermatol* 1972;87:138-144.
- Bowers, R. E., Graham, E. A., and Tomlinson, K. M. The natural history of the strawberry nevus. *Arch Dermatol* 1960;82:667-80.
- Cheung, D. S., Warman, W. L., and Mulliken, J. B. Hemangioma in twins. *Ann Plast Surg* 1997;38:269-74.
- Enjolras, O., and Gelbert, F. Superficial hemangiomas: Associations and management. *Pediatr. Dermatol* 1997;14:173-9.
- Bivings L. Spontaneous regression of angiomas in children: twenty-two years observation covering 236 cases. *J Pediatr* 1954;45:643-647.
- Finn MC, Glowacki J, Mulliken JB. Congenital vascular lesions: clinical application of a new classification. *Journal of Pediatric Surgery* 1983;18:894-900.
- Dieterich-Miller CA, Cohen BA, Liggett J. Behavioral adjustment and selfconcept of young children with hemangiomas. *Pediatr Dermatol* 1992;9:241-245.
- Williams EF, Hochman M, Rodgers BJ, Brockbank D, Shannon L, Lam S. A psychological profile of children and families afflicted with hemangiomas. *Arch Facial Plast Surg*. 2003;5:229-234.
- Williams EF, Stanislaw P, Dupree M, Mourtizkos K, Mihm M, Shannon L. Hemangiomas in infants and children: an algorithm for intervention. *Arch Facial Plastic Surgery* 2000;2:103-111.
- Frieden IJ, Eichenfield LF, Esterly NB, et al. American Academy of Dermatology guidelines of care for hemangiomas of infancy. *J Am Acad Dermatol* 1997;37:631-637.
- Miller SH, Smith RL, Shochat SJ. Compression treatment of hemangiomas. *Plast Reconstr Surg* 1976;58:573-9.
- Katz HP. Thrombocytopenia associated with hemangiomata: Critical analysis of steroid therapy. In XI International Congress of Pediatrics. Tokyo 1965:336-337.
- Zarem HA, Edgerton MT. Induced resolution of cavernous hemangiomas following prednisolone therapy. *Plast Reconstr Surg* 1967;39:76-83.

21. Bennett ML, Fleischer AB, Chamlin SL, Frieden IJ. Oral corticosteroid use is effective for cutaneous hemangiomas. An evidence based evaluation. *Arch Dermatol* 2001;137:1208-1213.
22. Sadan N, Wolach B. Treatment of hemangiomas of infants with high doses of prednisone. *J Pediatr* 1996;128:141-146.
23. Jalil S, Akhtar J, Ahmed S. Corticosteroids therapy in the management of infantile cutaneous hemangiomas. *J Coll Physicians Surg Pak* 2006;16:662-5.
24. Pope E, Krafchik BR, Macarthur C, et al. Oral versus high-dose pulse corticosteroids for problematic infantile hemangiomas: a randomized, controlled trial. *Pediatrics* 2007;119:e1239-47.
25. Kushner BJ. The treatment of periorbital infantile hemangioma with intralesional corticosteroid. *Plast Reconstr Surg* 1985;76(4):517-26.
26. Chen MT, Yeong EK, Horng SY. Intralesional corticosteroid therapy in proliferating head and neck hemangiomas: a review of 155 cases. *Journal of Pediatric Surgery* 2000;35(3):420-423.
27. Garzon MC, Lucky AW, Hawrot A, Frieden IJ. Ultrapotent topical corticosteroid treatment of hemangiomas of infancy. *J Am Acad Dermatol* 2005;52:281-6.
28. Kane WJ, Morris S, Jackson IT, Woods JE. Significant hemangiomas & vascular malformations of the head & neck: Clinical management and treatment outcomes. *Annals of Plastic Surgery* 1995;35:133-143.
29. White CW, Sondheimer HM, Crouch EC, Wilson H, Fan LL. Treatment of pulmonary hemangiomas with recombinant interferon alfa-2a. *N Engl J Med* 1989;320:1197-200.
30. Waldorf HA, Lask GP, Geronemus RG. Laser treatment of telangiectasias. In: Alster TS, Apelfberg DB, eds. *Cosmetic Laser Surgery*. New York: Wiley-Liss; 1996:93-109.
31. Waner M, Suen JY, Dinehart S. Treatment of hemangiomas of the head and neck. *Laryngoscope* 1992;102:1123-1132.
32. Fawcett SL, Grant I, Hall PN, et al: Vincristine as a treatment for a large haemangioma threatening vital functions. *Br J Plast Surg* 2004;57:168-171.
33. Metz BJ, Rubenstein MC, Levy ML, Metry DW. Response of ulcerated perineal hemangiomas of infancy to becaplermin gel, a recombinant human platelet derived growth factor. *Arch Dermatol* 2004;140:867-870.
34. Leaute-Labreze C, Dumas de la Roque E et al. Propranolol for severe hemangiomas of infancy. *N Engl J Med* 2008;358:2649-2651.
35. Buckmiller LM, Munson PD, Dyamenahalli U, Dai Y, Richter GT (2010). Propranolol for infantile hemangiomas: Early experience at a tertiary vascular anomalies center. *Laryngoscope* 2009;119(10):2051-54.
36. Popescu V. Intratumoral ligation in the management of orofacial cavernous hemangiomas. *Journal of Maxillofacial Surgery* 1985;13:99-107.
37. Oji C, Chukwunke F, Mgbor N. Tobacco-pouch suture technique for the treatment of vascular lesions of the lip in Enugu, Nigeria. *British Journal of Oral and Maxillofacial Surgery* 2006;44:245-247.
38. Pitanguy I, Machado BH, Radwanski HN, Amorim NF. Surgical treatment of hemangiomas of the nose. *Ann Plast Surg* 1996;36(6):586-592.
39. Faguer K, Dompmartin A, Labbe D, Barrellier MT, Leroy D, Theron J. Early surgical treatment of Cyrano-nose haemangiomas with Rethi incision. *Br J Plast Surg* 2002;55(6):498-503.
40. Waner M, Kastenbaum J, Scherer K. Hemangiomas of the nose: Surgical management using modified subunit approach. *Arch Facial Plast Surg* 2008;10(5):329-334.
41. Zide BM, Glat PM, Stile FL, Longaker MT. Vascular lip enlargement, I: hemangiomas—tenets to therapy. *Plast Reconstr Surg* 1997;100:1664-1673.
42. Mulliken JB, Rogers GF, Marler JJ. Circular excision of hemangioma and purse-string closure: the smallest possible scar. *Plast Reconstr Surg* 2002;109:1544-1554.
43. Mcheika JN, Renauldb V, Duportb G, Vergnesc P, Levarda G. Surgical treatment of haemangioma in infants. *British Journal of Plastic Surgery* 2005;58:1067-1072.
44. Achauer BM, Chang CJ, Vander Kam VM. Management of hemangioma of infancy: review of 245 patients. *Plast Reconstr Surg* 1997;99(5):1301-1308.
45. Demiri EC, Pelissies P, Genin-Etcheberry T, Tsakoniatis N, Martin D, Baudet J. Treatment of facial haemangiomas: the present status of surgery. *British Journal of Plastic Surgery* 2001;54:665-674.
46. Waner M, North PE, Scherer KA, et al. The non-random distribution of facial hemangiomas. *Arch Dermatol* 2003;139:869-875.
47. Haggstrom AN, Lammer EJ, Schneider RA, et al. Patterns of infantile hemangiomas: new clues to hemangioma pathogenesis and embryonic facial development. *Pediatrics* 2006;117:698-703.