

Case Report

INTRA-ARTICULAR SYNOVIAL HEMANGIOMA OF KNEE OVERLYING POSTERIOR CRUCIATE LIGAMENT - A CASE REPORT

Dileep K.S.¹, Sandeep V. Kanakaraddi², Vidyasagar J.V.S.³, Radha S.⁴, Akshatha Rao Aroor⁵,

^{1&2}Clinical Fellow, Faculty of Arthroscopy and Sports Medicine, ³Head of the Department
Department of Orthopaedics, Kamineni Hospitals, Hyderabad, Andhra Pradesh, India

⁴Consultant Pathologist, Vijaya Diagnostic Center, Hyderabad, Andhra Pradesh, India

⁵Assistant Professor, Department of Medicine, K.S. Hegde Medical Academy,
Nitte University, Deralkatte, Mangalore - 575 018, Karnataka, India.

Correspondence:

Dileep K.S.,

Assistant Professor, Department of Orthopaedics, K.S. Hegde Medical College Hospital, Deralakatte, Mangalore - 575 018
Ph.+91 824 2204471. E-mail : dileepsri@hotmail.com

Abstract :

Hemangioma of synovium is a rare benign tumor that can arise from any surface lined by synovium. Intra-articular synovial hemangioma is most common in the knee joint. The diagnosis is difficult as the signs and symptoms are nonspecific. We hereby report a hitherto unreported case of synovial hemangioma of knee overlying posterior cruciate ligament, its MRI findings and discuss the appropriate management

Keywords : posterior cruciate ligament, hemangioma, synovium, knee

Introduction :

Hemangioma of synovium is an uncommon benign tumor that can arise from any surface lined by synovium(1). Intra-articular synovial hemangioma is most common in the knee. Fewer than 200 synovial hemangiomas have been reported so far(2) but intra-articular synovial overlying posterior cruciate ligament has not been reported so far according to pubmed search. We report a case of intra-articular capillary hemangioma of synovium overlying posterior cruciate ligament, its MR imaging findings and discuss appropriate management.

Case report :

A 29-year-old male patient presented to our clinic with history of intermittent pain and swelling of left knee of 1-year duration. He had symptoms of pseudolocking associated with this. There was no history of injury, pain in other joints, fever or constitutional symptoms. There was no history of bleeding diathesis. On examination, severe

wasting of quadriceps muscle with moderate knee effusion and fullness of popliteal fossa was noticed. There was diffuse tenderness of left knee with features of synovitis. Tests for menisci, cruciate or collateral ligaments could not be performed because of pain. Routine haematological examination was normal and Mantoux test was negative. Radiological examination revealed soft tissue density in the posterior aspect of knee suggesting a mass or synovial lesion. MR imaging localized a hyperintense soft tissue mass on T2-weighted images attached to anterior aspect of posterior cruciate ligament pushing the ligament further posteriorly as a mass effect. At diagnostic arthroscopy a 1.5 X 1.5 cm reddish brown mass of thickened synovium attached to the anterior aspect of posterior cruciate ligament pushing it further posteriorly was noted. A total excision of mass was done arthroscopically and the tissue was sent for histopathological examination. Posterior cruciate ligament was confirmed to be intact on probing. Biopsy confirmed the diagnosis of capillary hemangioma of synovium. On a followup of 6 months postoperatively, the patient was totally asymptomatic without features of recurrence and has regained full range of movements.

Access this article online

Quick Response Code



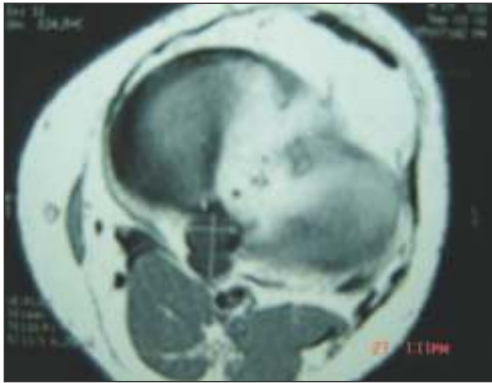


Fig 1: MRI showing soft tissue mass on T2 images overlying the anterior aspect of posterior cruciate ligament.

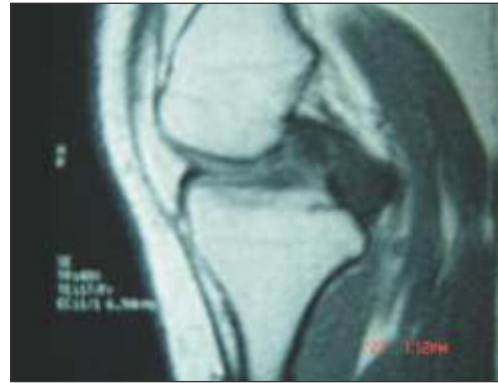

Fig 2: MRI showing soft tissue mass on T2 images overlying anterior aspect of posterior cruciate ligament.

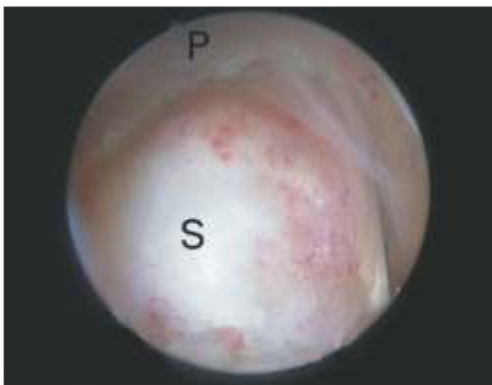

Fig 3: arthroscopy showing hemangiomatous mass overlying anterior aspect of posterior cruciate ligament. S-synovial hemangioma, P-posterior cruciate ligament

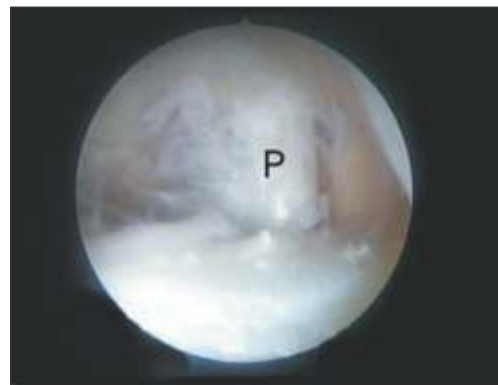


Fig 4. Arthroscopy picture after total excision of the mass with intact posterior cruciate ligament. P-posterior cruciate ligament.

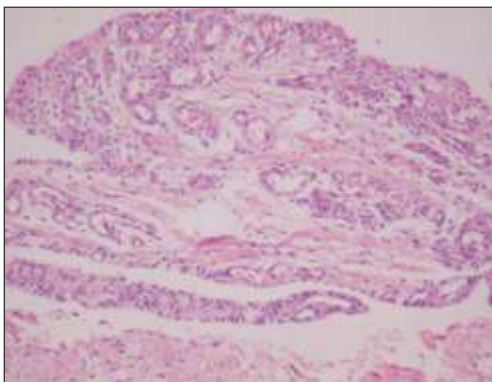


Fig 5: Hematoxylin and Eosin stained section shows a flattened synovium with lobules of capillary-sized vascular channels below.

Discussion :

Intra-articular synovial hemangioma of knee is a rare benign tumor first described by Bouchut in 1965(2). It can arise from any synovium-lined surface(1). In 97% of cases, it is located in the knee joint, but it has also been reported in other joints such as elbow, ankle and wrist(3). Synovial

hemangioma overlying the posterior cruciate ligament has not been reported previously.

Children and adolescents are commonly affected although in a large study, patient age ranged from 9 to 49 years(4). Males are more often affected than females. Although pain is the post predominant symptom, patient can also present with pseudolocking as in our case. Devaney et al. examined 20 patients in their study and reported that the symptoms are usually pain and swelling (31%), pain alone (#1%), painless mass (#1%) and recurrent intra-articular hemorrhage (5%)(4). Other symptoms include recurrent nontraumatic hemarthrosis, intermittent tender palpable mass and limited range of motion. Signs are often minimal but may include atrophy of the quadriceps muscle, joint effusion and restricted range of movement.

Because of nonspecific signs and symptoms, diagnosis can be difficult and delayed unless the clinician is aware of the

disease. A delayed diagnosis causes loss of function, infiltration into surrounding tissues, excision of mass more difficult and later arthropathy due to recurrent hemarthrosis. The differential diagnosis include pigmented villonodular synovitis, synovial osteochondromatosis, loose bodies, osteochondral fractures, ligament rupture, osteochondritis dissecans, juvenile rheumatic arthritis, xanthoma and malignant tumors. The MRI usually shows mass of high-signal intensity and T2-weighted images without extensive mass effect(3) but in our case a hyperintense soft-tissue mass on T2-weighted images attached to the anterior aspect of posterior cruciate ligament with a mass effect of stretching the ligament posteriorly was noted. Intra-articular, pedunculated, well-circumscribed, apparently encapsulated lesions are best treated by arthroscopic total

excision of mass. Arthroscopy also aides in the assessment of ligament to which it may be attached. In cases of diffuse joint involvement, difficulty in excision and recurrences can occur(2). Biopsy confirms the diagnosis. About 50% of synovial hemangiomas are cavernous type and rest are capillary, arteriovenous, and pure venous. The histology in our case showed a capillary type of hemangioma.

Conclusion :

Intra-articular synovial hemangioma of knee is a rare benign tumour. Hemangioma overlying the posterior cruciate ligament has not been reported previously. Pain is the predominant symptom but can also present as internal derangement of knee. The diagnosis can be difficult unless the clinician is aware of the disease. Localized lesion is best treated with arthroscopic total excision.

References :

1. Meislin RJ, Parisien JS. Case report of arthroscopic excision of synovial hemangioma of the knee. *Arthroscopy* 1990;6:64-67.
2. Akgun I, Kesmezacar H, Ogut T, Dervisoglu S. Intra-articular hemangioma knee. *Arthroscopy* 2003;19(3):E17
3. Llauger J, Monohil JM, PAalmer J, Clolet M. Synovial hemangioma of knee: MRI findings in two cases. *Skeletal Radiology* 1995;24:579-581.
4. Devaney K, Vinh TN, Sweet DE. Synovial hemangioma: a report of 20 cases with differential diagnostic considerations. *Hum Pathol* 1993;24:737-745.