

# Epigastric Hernias in Children: A Personal Series and Systematic Review of the Literature

Georges K. Tinawi<sup>1</sup> Mark D. Stringer<sup>1</sup>

<sup>1</sup>Department of Paediatric Surgery, Wellington Children's Hospital, Wellington, New Zealand

Eur J Pediatr Surg 2022;32:139–145.

**Address for correspondence** Mark D. Stringer, MS, FRCS, FRACS, Department of Paediatric Surgery, Wellington Children's Hospital, Wellington Hospital, Riddiford Street, Newtown, Wellington 6021, New Zealand (e-mail: mark.stringer@ccdhb.org.nz).

## Abstract

Epigastric hernias are relatively uncommon in children, and there is a paucity of literature on their incidence, presenting features, natural history, and surgical outcomes. A systematic review was conducted according to PRISMA guidelines. Articles describing the incidence, outcome, and interventions for pediatric epigastric hernias, both open and laparoscopic, were analyzed. Eight relevant articles published between 1975 and 2019 were included in the analysis. Of 81 children, 58% were females, 35% were symptomatic and 8% were multiple. All hernias contained preperitoneal fat only and were repaired using standard open surgery or laparoscopic techniques. No recurrences were recorded. In a personal series of 37 hernias in 36 children of median age 4 years, there were no recurrences; however, this series included two children with a recurrent or persistent epigastric hernia after surgery by others. Epigastric hernias in children are relatively uncommon. They typically contain only preperitoneal fat but more than a third are symptomatic. Standard open repair can be undertaken with minimal morbidity. Laparoscopic repair takes longer and provides a marginal cosmetic benefit.

## Keywords

- ▶ abdominal wall hernia
- ▶ ventral hernia
- ▶ minimally invasive surgery

## Introduction

Epigastric hernias are relatively uncommon in children. Typically, they consist of a protrusion of preperitoneal fat through a fascial defect in the linea alba that produces a visible and palpable midline lump between the xiphoid process and the umbilicus. Most are asymptomatic but they can cause localized discomfort, particularly with exercise, and may become acutely painful if incarcerated. Standard repair is via a short transverse epigastric incision, but in recent years several authors have advocated laparoscopic repair. There have been remarkably few studies on pediatric epigastric hernias and the etiology, prevalence, natural history, and indications for surgery are not well described. We undertook a systematic review to describe what is currently known about these hernias and report our own experience.

## Materials and Methods

### Systematic Review

This was conducted according to the Preferred Reporting Items for Systematic Reviews and Meta-Analyses (PRISMA) statement.<sup>1</sup>

### Identification of Studies

The literature search was undertaken using MEDLINE, EMBASE, and the first ten pages of Google Scholar using the following keywords: “epigastric” or “linea alba,” and “hernia,” and “children” or “pediatric.” The search was completed on the 28th February 2020. Reference lists of all relevant articles were searched for additional studies.

received  
June 11, 2020  
accepted after revision  
September 21, 2020  
published online  
November 10, 2020

© 2020. Thieme. All rights reserved.  
Georg Thieme Verlag KG,  
Rüdigerstraße 14,  
70469 Stuttgart, Germany

DOI <https://doi.org/10.1055/s-0040-1719056>.  
ISSN 0939-7248.

### Inclusion/Exclusion Criteria

All English language articles documenting incidence, treatments, or outcomes for epigastric hernias in children aged 17 years or younger were included. Review articles providing no novel patient data, studies of other types of ventral abdominal wall hernias, and studies with no specific data on epigastric hernias were excluded. Given the limited literature on pediatric epigastric hernias, case reports that reported novel findings were included.

### Study Selection and Data Extraction

One author (G.K.T.) screened abstracts of potentially relevant studies and both authors independently reviewed all relevant full text articles using a standardized data-extraction template.

### Outcomes

The prevalence, sex distribution, age and symptoms at presentation, operative technique and findings, and clinical outcomes were analyzed.

### Personal Series

A retrospective review of the senior author's (M.D.S.) experience during the 7-year period between June 2013 and July 2020 was undertaken. Our policy is to offer elective repair after the age of 1 year. Age, sex, clinical features, operative details, concomitant pathology, and outcomes were reviewed. All patients were clinically reviewed 3 to 6 months postoperatively and advised to return if they developed any future problems.

## Results

### Systematic Review

Seventeen articles were selected for full-text assessment (→Fig. 1), and eight reports were included in the final analysis. Five were retrospective reviews of an institutional cohort,<sup>2–6</sup> two were small case series,<sup>7,8</sup> and one was a case report<sup>9</sup> (→Table 1). Another case report of a giant congenital epigastric hernia in a 6-month-old boy who also had a congenital right lumbar hernia appears to describe a unique and different pathology and was not included.<sup>10</sup> Studies were published between 1975 and 2019 and collectively reported a total of 81 patients (47 females) ranging in age from birth to 17 years at presentation. There was considerable heterogeneity between the studies in relation to patient selection, operative technique, and follow-up.

Only one study indirectly estimated the frequency of epigastric hernias in children; Coats et al from Missouri concluded that epigastric hernias accounted for 4% of all pediatric hernias presenting to their institution over a 14-year period.<sup>2</sup>

Six studies reported on symptoms (→Table 1).<sup>2,4,6–9</sup> The most detailed study included 40 patients, 15 (38%) of whom had epigastric pain or a tender epigastric lump, although more than half of this cohort were too young to reliably report symptoms.<sup>2</sup> All children had a palpable midline epigastric lump, which was initially overlooked in a few.<sup>2</sup>

Hernias were variably reducible. Bugenstein and Phibbs reported two children with chronic recurrent abdominal pain that they eventually attributed to an epigastric hernia.<sup>7</sup> The size of the palpable epigastric lump and distance from the umbilicus were inconsistently reported, but all lesions were less than 20 mm.

Almost all reported children underwent surgical repair (→Table 1); two were lost to follow-up during a period of observation.<sup>2</sup> All operated hernias were found to contain preperitoneal fat protruding through a defect in the linea alba. The mean width of the linea alba fascial defect was recorded as 7 mm in one study (range = 2 mm–2.5 cm) and did not correlate with age.<sup>2</sup>

In publications up to 2,000, a standard open repair was used, but subsequent reports have focused on laparoscopic repair for all cases<sup>3,5</sup> or for those not accessible through an umbilical incision.<sup>4</sup> Laparoscopic repair has been performed using a variety of techniques including two separate ports,<sup>3,5</sup> and “single incision” with either two ports,<sup>4,6,8</sup> or one.<sup>9</sup> Operative times for laparoscopic repair varied considerably from a mean of 25 minutes<sup>4</sup> up to 80 minutes.<sup>8</sup>

Multiple epigastric hernias and concomitant abdominal wall hernias were identified in a small proportion of children. In total, 12 of the 81 patients (15%) had a concomitant umbilical hernia at presentation,<sup>2,5,8</sup> and six (8%) of the 79 children that underwent operative repair were found to have two or three separate linea alba defects at the time of surgery.<sup>2,5</sup>

The duration of follow-up varied greatly (→Table 1), but no postoperative complications or recurrent epigastric hernias were reported.

### Personal Series

During a 7-year period, the senior author repaired 37 epigastric hernias in 36 children (→Table 2). At least eight hernias had been noticed at or soon after birth. Two of the 36 children were referred for the treatment of a recurrent or persistent epigastric hernia after a previous repair by another surgeon (6 years and 5 months before) and one child had two synchronous epigastric hernias.

All repairs were undertaken as day-case procedures and combined with an umbilical hernia repair in six children and an inguinal herniotomy in one. One child stayed overnight because of postoperative upper respiratory tract symptoms, but no other postoperative complications were recorded. The width of the fascial defect in the linea alba was measured in 18 children and was a median of 3 mm (range = 2–5 mm). No child developed a recurrence after a median interval of 4.2 years. One 8-year-old girl required subsequent surgery for a second epigastric hernia at a site separate to the original hernia repair.

## Discussion

Relatively little is known about the prevalence, etiology, and natural history of epigastric hernias in children. In common with other systematic reviews, the heterogeneity of the data limits the analysis, but some conclusions and recommendations are possible.

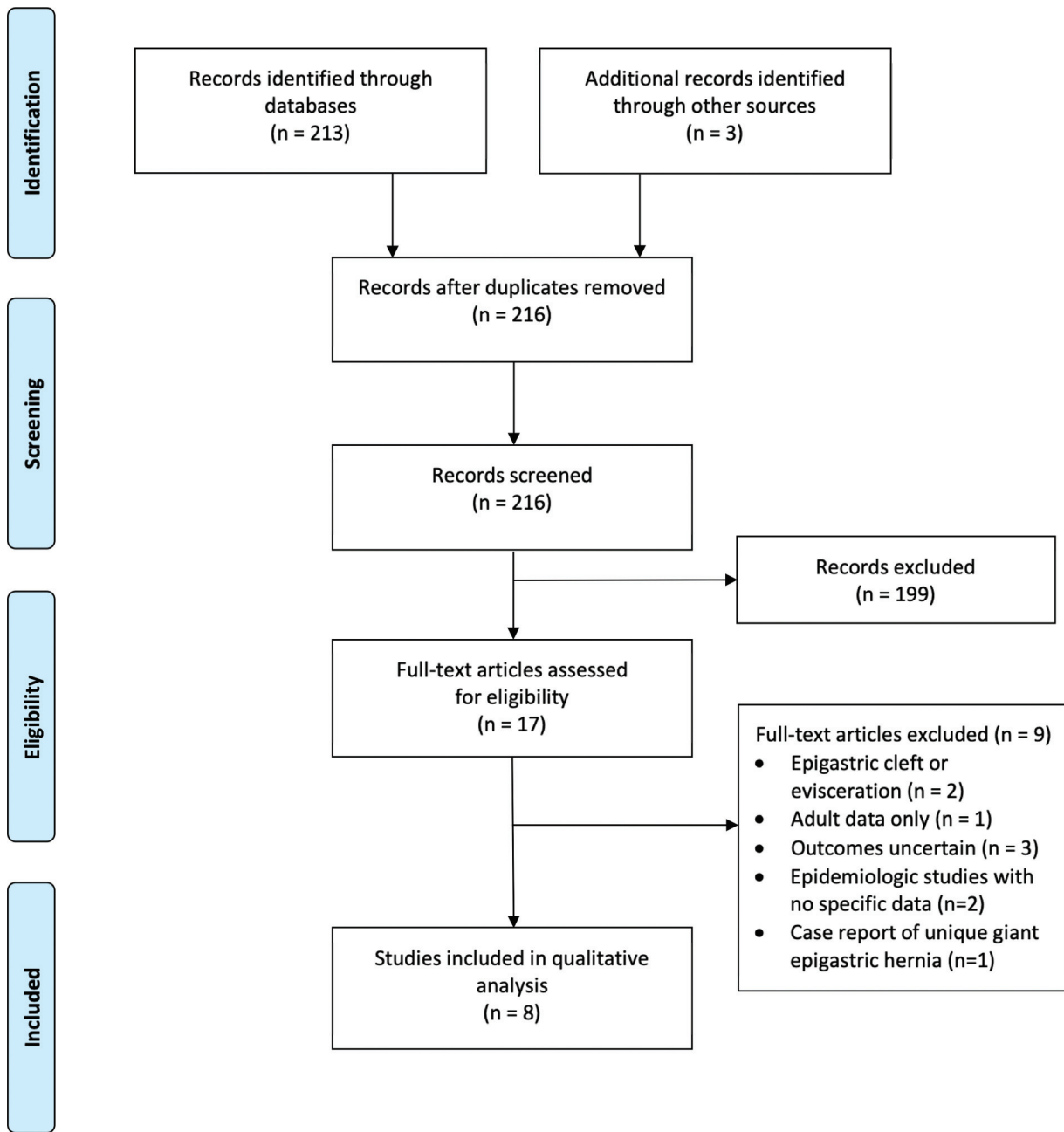


Fig. 1 PRISMA flow chart.

### Prevalence

The prevalence of epigastric hernias in children is unknown and many may go undetected. Adult autopsy studies are not a useful guide since epigastric hernias in adults may also be acquired. A national 5-year study from Denmark comprising 2,412 patients undergoing epigastric hernia repair found a bimodal distribution with a small peak in childhood and a much larger peak in middle-aged adults; the 5-year prevalence rate of repaired epigastric hernias in individuals younger than 20 years was no greater than 0.02% of the population.<sup>11</sup> An older report from a children's hospital in the United Kingdom identified only one acute referral with an epigastric hernia during a 3-year period in contrast to 338 acute referrals with an inguinal or umbilical hernia.<sup>12</sup> Al-

though previous reports have suggested a male or female bias,<sup>4,6</sup> the sex incidence of epigastric hernias in children is probably similar,<sup>11</sup> as seen in our series.

### Pathogenesis

Epigastric hernias in children are mostly, if not exclusively, congenital. In contrast, epigastric hernias in adults may be congenital<sup>13</sup> or acquired<sup>14</sup>; it is not known if the latter develop from a focal congenital weakness or defect in the linea alba or if they arise de novo. In adults, numerous risk factors for the development of an epigastric hernia have been identified including obesity, chronic cough, smoking, physical straining, chronic steroid use, pregnancy, diabetes mellitus, and increasing age.<sup>14,15</sup>

**Table 1** Published series of pediatric epigastric hernia (case report excluded)

Study (year)	n	Sex M:F	Presentation	Age at presentation	Age at surgery	Surgica approach	Operative findings	Follow-up	Outcomes
Bugenstein and Phibbs (1975) <sup>7</sup>	2	1:1	Recurrent abdominal pain and tender epigastric midline lump	8 and 9 y	8 and 9 y	Open	Preperitoneal fat	Unknown	No complications or recurrence Symptoms resolved
Coats et al (2000) <sup>2</sup>	40	15:25	18 (45%) asymptomatic reducible lump 15 (38%) epigastric pain >on exercise or tender epigastric lump 7 (18%) asymptomatic nonreducible lump 5 had concomitant umbilical hernia	Mean = 4.3 ± 5.2 y (range 0–17) 12 (30%) at birth–1 mo 8 (20%) = 1–23 mo 9 (23%) = 2–5 y 7 (17%) = 6–12 y 4 (10%) = 13–18 y	38 had surgery (age not stated)	Open	Preperitoneal fat Fascial defect 7 ± 6 mm Multiple hernias in five children	Unknown	No complications or recurrence
Albanese et al (2006) <sup>3</sup>	13	6:7	Not reported Six had concomitant umbilical hernia	Not stated	Mean = 2 y	Laparoscopic	Preperitoneal fat; “incarcerated” in nine	6–35 mo	No complications or recurrence
Babsail et al (2014) <sup>4</sup>	5	0:5	Intermittent pain	Not stated	Median = 6.4 y (4.4–12.6)	Laparoscopic	Preperitoneal fat; “incarcerated”	4–18 mo	No complications or recurrence
Moreira-Pinto and Correia-Pinto (2015) <sup>5</sup>	10	5:5	Symptoms not reported	Not stated	Median = 6.6 y (1.9–11.8)	Laparoscopic	Preperitoneal fat three defects in one	2–12 mo	No complications or recurrence
Deie et al (2016) <sup>8</sup>	2	1:1	Visible lump >year in both 1 had concomitant umbilical hernia	3 mo and 7 y	3 and 7 y	Laparoscopic	Preperitoneal fat	2 y	No complications or recurrence
Jun et al (2019) <sup>6</sup>	8	5:3	Epigastric lump ± localized discomfort with exercise Nausea and vomiting in some	Not stated	Mean = 1.8 y (2 mo–4 y)	Laparoscopic	Preperitoneal fat	1–12 mo	No complications or recurrence

Abbreviations: mo, months; y, years.

**Table 2** Results from a personal series of children with repaired epigastric hernias (2013–2020)

No. of patients (hernias)	36 (37 hernias)
Male:Female	19:17
Median age at surgery (range)	4 (1.5–12) y
Presenting features	20 asymptomatic Nine localized discomfort (often worse with exercise) Two acute pain and tenderness Five not documented
Concomitant pathology	Six umbilical hernia One inguinal hernia
Operative findings	Median defect size 3 mm (range = 2–5 mm) ( <i>n</i> = 18)
Outcomes	No recurrence

The linea alba is composed of a trilaminar meshwork of overlapping oblique and transverse collagen fibers.<sup>16</sup> Four main theories on the pathogenesis of epigastric hernias have been proposed. First, a congenital weakness in the linea alba created by a perforating blood vessel<sup>13,17</sup>; however, in children there is rarely a significant vessel visible within the protruding fat. Second, a congenital weakness due to a variable pattern of decussating fibers that make up the linea alba<sup>18</sup>; this is not supported by biopsy or cadaver studies.<sup>13,14,16,19</sup> Third, an acquired defect in the linea alba due to forceful contraction of tendinous fibers from the diaphragm inserting into the posterior aspect of the linea alba, for example, from coughing<sup>18</sup>; this does not account for epigastric hernias that are present at birth. Finally, alterations in the collagen and elastin composition of the linea alba,<sup>20</sup> or the thickness and density of its fibers,<sup>16,19</sup> factors which may also be important in the pathogenesis of adult epigastric hernias.

### Clinical Features

In children, epigastric hernias are typically small and not true hernias since they contain only preperitoneal fat. In contrast, epigastric hernias in adults may be large with a peritoneal sac which may contain omentum or even bowel.<sup>13,15,17</sup> There is one report of an infant with a giant congenital epigastric hernia containing viscera, but this child also had a lumbar hernia suggesting a more generalized abdominal wall weakness.<sup>10</sup> Epigastric hernias in children are usually recognizable as a visible and palpable subcutaneous lump overlying the linea alba above the umbilicus (→ Fig. 2A); occasionally, the lump lies slightly to one or other side of the midline or there may be more than one hernia. The lump may or may not be reducible. The majority of epigastric hernias are asymptomatic at presentation. Just over one third of cases in our series complained of localized discomfort or pain, similar to the proportion in the only other study reporting more than 30 pediatric cases.<sup>2</sup> Vague or recurrent chronic abdominal symptoms have been attributed to the hernia, but this is difficult to prove.<sup>7</sup> Diagnosis is easily made by clinical examination. Confirmation by ultrasound imaging<sup>6</sup> is rarely required. In children, a concomitant umbilical hernia may be present<sup>2,3,8</sup> as noted in our series (→ Fig. 2B).

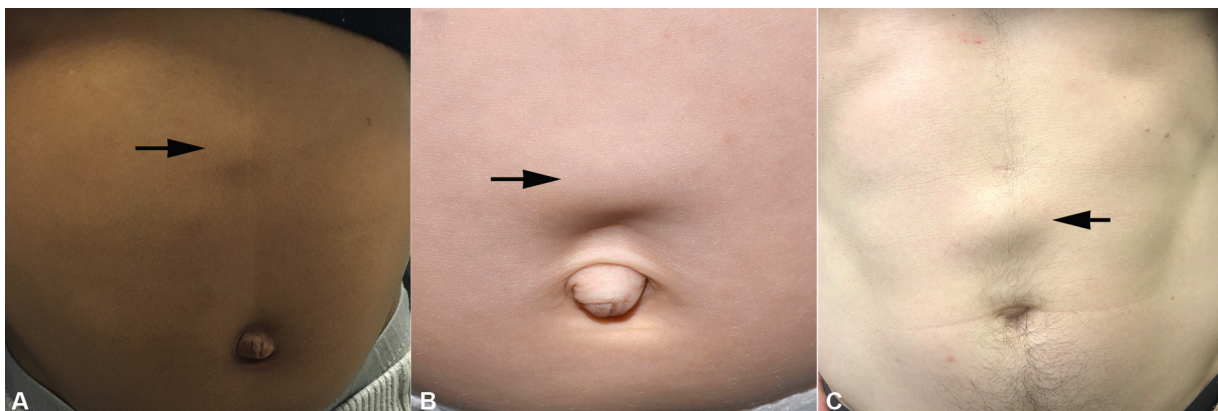
### Natural History

Several authors have suggested that epigastric hernias in children are capable of healing spontaneously,<sup>8,9,21</sup> but others dispute this.<sup>4</sup> We have never encountered such a case.

### Management

Untreated epigastric hernias may become larger (→ Fig. 2C) and/or painful. Thus, elective repair is often recommended, even in asymptomatic cases.<sup>2</sup> Others restrict repair to symptomatic<sup>4</sup> or persistent hernias<sup>8</sup> (→ Table 3). Similarly divergent advice exists with adult epigastric hernias.<sup>22,23</sup>

Day-case operative repair is generally straightforward provided the site of the hernia is marked accurately before general anesthesia. At operation, distinguishing herniated preperitoneal fat from subcutaneous fat can be difficult, but the former often appears yellower and is seen as a discrete



**Fig. 2** (A) A 3-year-old boy with a typical epigastric hernia (arrow). (B) A 18-month-old infant with an epigastric (arrow) and small umbilical hernia. (C) A 45-year-old man with an asymptomatic epigastric hernia since birth (arrow). The small scar visible above the hernia is from a laparoscopic port site for a previous cholecystectomy.

**Table 3** Information regarding epigastric hernias on children's hospital websites

Hospital	Source	Latest access date	Prognosis/Outcome information	Management recommendation
Children's Hospital of Orange County United States	<a href="https://blog.chocchildrens.org/hernias-children/">https://blog.chocchildrens.org/hernias-children/</a>	12/9/20	"They can cause some discomfort and they do not go away on their own"	"When we find them, we fix them"
Children's Hospital of Philadelphia United States	<a href="https://www.chop.edu/news/recognizing-and-caring-hernias">https://www.chop.edu/news/recognizing-and-caring-hernias</a>	10/9/20		"Surgery is required to fix this type of hernia"
Children's Hospital of Wisconsin United States	<a href="https://kidshealth.org/CHW/en/parents/epigastric-hernias.html?WT.ac=p-ra">https://kidshealth.org/CHW/en/parents/epigastric-hernias.html?WT.ac=p-ra</a>	12/9/20		"Many are small, cause no symptoms, and do not need treatment. Larger ones that do cause symptoms will not heal on their own, but surgery can fix the problem"
Children's Minnesota United States	<a href="https://www.childrensmn.org/educationmaterials/childrensmn/article/18005/epigastric-hernia/">https://www.childrensmn.org/educationmaterials/childrensmn/article/18005/epigastric-hernia/</a>	12/9/20	"Children with epigastric hernias do well. Recurrence of the hernia is rare"	"Call the clinic if your child feels pain in the hernia"
Great Ormond Street Hospital England	<a href="https://www.gosh.nhs.uk/conditions-and-treatments/conditions-we-treat/umbilical-and-epigastric-hernia">https://www.gosh.nhs.uk/conditions-and-treatments/conditions-we-treat/umbilical-and-epigastric-hernia</a>	5/9/20		"Epigastric hernias are usually repaired only if they are causing discomfort or getting in the way of normal everyday life and activities"
Nemours Children's Hospital United States	<a href="https://kidshealth.org/en/parents/epigastric-hernias.html">https://kidshealth.org/en/parents/epigastric-hernias.html</a>	4/9/20	"Many are small, cause no symptoms, and do not need treatment. Larger ones that do cause symptoms will not heal on their own, but surgery can fix the problem." "Epigastric hernias do not go away without treatment"	"Doctors may repair them with surgery if a hernia causes symptoms"
PennState Health Children's Hospital United States	<a href="https://childrens.pennstatehealth.org/surgery/patient-care-and-treatment/hernia-problems-in-children">https://childrens.pennstatehealth.org/surgery/patient-care-and-treatment/hernia-problems-in-children</a>	30/8/20	"An epigastric hernia will not resolve on its own. An epigastric hernia is more annoying than dangerous"	"Most people will choose to have them repaired"
Royal Children's Hospital, Australia	<a href="https://www.rch.org.au/kidsconnect/prereferral_guidelines/Epigastric_hernia_prereferral/">https://www.rch.org.au/kidsconnect/prereferral_guidelines/Epigastric_hernia_prereferral/</a>	11/9/20	"...does not close spontaneously." "Usually asymptomatic and virtually never becomes infected"	"Refer to outpatient department general surgery when there are symptoms or for cosmetic concerns"
Seattle Children's Hospital United States	<a href="https://www.seattlechildrens.org/pdf/PE2110.pdf">https://www.seattlechildrens.org/pdf/PE2110.pdf</a>	6/9/20	"This type of hernia will not close on its own..." "If not repaired, the hernia may get bigger or become painful"	"...must be repaired with surgery within a few months after finding it or sooner if your child is in pain"
The Children's Hospital, Oxford University Hospitals England	<a href="https://www.ouh.nhs.uk/patient-guide/leaflets/files/39032Pher-nia.pdf">https://www.ouh.nhs.uk/patient-guide/leaflets/files/39032Pher-nia.pdf</a>	12/9/20	"An epigastric hernia is not usually a serious problem, but it may become painful or tender due to trapped fat" "Surgery is the only way to repair an epigastric hernia; it will not go away on its own"	"We would usually recommend that an epigastric hernia is repaired with a simple operation, especially if it is causing symptoms or is very prominent"

lump emerging through a distinct defect in the linea alba. In children, epigastric hernias within 1 to 2 cm of the umbilicus can be repaired via a periumbilical incision, while others are repaired by a short transverse incision directly over the swelling. Complications are rare but include wound infection, hypertrophic scarring, and recurrence. Recurrence after open epigastric hernia repair in adults may be as high as 10 to 15%, depending on the body habitus and the technique used, for example mesh or suture repair.<sup>15</sup> Although long-term data in children are lacking, recurrence appears to be rare.

In recent years, several publications have advocated laparoscopic repair of pediatric epigastric hernias.<sup>3-6,8,9</sup> Purported advantages include quicker surgery,<sup>6</sup> improved cosmesis,<sup>3-5</sup> reduced postoperative pain,<sup>6</sup> and the identification of multiple linea alba defects.<sup>6</sup> No study has compared open versus laparoscopic repair of epigastric hernias in children. Further, laparoscopic repair carries a small risk of a trocar injury, it involves stripping away peritoneum at the site of the hernia (with the theoretical risk of intra-abdominal adhesions), is more expensive and has a marginal cosmetic benefit. Port placement has included two 3-mm ports in the left flank,<sup>3</sup> a 5-mm subumbilical and additional 3-mm port,<sup>4,5</sup> a single 5-mm subumbilical port,<sup>9</sup> and a 2-cm vertical umbilical incision with or without an additional 3-mm port.<sup>6,8</sup> Operative times have ranged from 25<sup>3,4</sup> to 80 minutes.<sup>8</sup> Endotracheal intubation is generally used for laparoscopy,<sup>6</sup> whereas open repair can be performed with a laryngeal mask. Recent guidelines in adults have recommended open repair for small epigastric hernias but suggested that laparoscopic repair may be beneficial for hernias larger than 4 cm and in patients with multiple defects or at higher risk of postoperative wound infection.<sup>24</sup>

## Conclusion

This systematic review and personal series of epigastric hernias in children attempts to summarize what is currently known about this topic. There are some major gaps in our knowledge, particularly around the etiology, pathogenesis, and natural history of epigastric hernias. The role of laparoscopic repair remains questionable.

### Conflict of Interest

None declared.

## References

- Moher D, Liberati A, Tetzlaff J, Altman DGPRISMA Group. Preferred reporting items for systematic reviews and meta-analyses: the PRISMA statement. *PLoS Med* 2009;6(07):e1000097
- Coats RD, Helikson MA, Burd RS. Presentation and management of epigastric hernias in children. *J Pediatr Surg* 2000;35(12):1754-1756
- Albanese CT, Rengal S, Bermudez D. A novel laparoscopic technique for the repair of pediatric umbilical and epigastric hernias. *J Pediatr Surg* 2006;41(04):859-862
- Babsail AA, Abelson JS, Liska D, Muensterer OJ. Single-incision pediatric endosurgical epigastric hernia repair. *Hernia* 2014;18(03):357-360
- Moreira-Pinto J, Correia-Pinto J. Scarless laparoscopic repair of epigastric hernia in children. *Hernia* 2015;19(04):623-626
- Jun Z, Na J, Zhen C, et al. Single-incision laparoscopic approach for linea alba hernia in children. *J Minim Access Surg* 2019;15(01):42-45
- Bugenstein RH, Phibbs CM Jr. Abdominal pain in children caused by linea alba hernias. *Pediatrics* 1975;56(06):1073-1074
- Deie K, Uchida H, Kawashima H, et al. Operative procedures of single-incision laparoscopic repair of pediatric epigastric hernia have become simple and feasible with the use of a novel suture-assisting needle. *J Pediatr Surg Case Rep* 2016;4:22-26
- Tatekawa Y, Yamanaka H, Hasegawa T. Single-port laparoscopic repair of an epigastric hernia using an epidural needle. *Int J Surg Case Rep* 2013;4(03):262-264
- Ameh EA. Giant congenital epigastric hernia. *West Afr J Med* 1999;18(02):151-152
- Burcharth J, Pedersen MS, Pommergaard HC, Bisgaard T, Pedersen CB, Rosenberg J. The prevalence of umbilical and epigastric hernia repair: a nationwide epidemiologic study. *Hernia* 2015;19(05):815-819
- Golby M. Acute abdominal wall hernias in infants and children. *Am J Surg* 1967;114(06):888-893
- Lang B, Lau H, Lee F. Epigastric hernia and its etiology. *Hernia* 2002;6(03):148-150
- Ponten JE, Somers KY, Nienhuijs SW. Pathogenesis of the epigastric hernia. *Hernia* 2012;16(06):627-633
- Ponten JE, Leenders BJ, Charbon JA, Nienhuijs SW. A consecutive series of 235 epigastric hernias. *Hernia* 2015;19(05):821-825
- Axer H, Keyserlingk DG, Prescher A. Collagen fibers in linea alba and rectus sheaths. I. General scheme and morphological aspects. *J Surg Res* 2001;96(01):127-134
- Moschcowitz AV. Epigastric hernia without palpable swelling. *Ann Surg* 1917;66(03):300-307
- Askar OM. Aponeurotic hernias. Recent observations upon para-umbilical and epigastric hernias. *Surg Clin North Am* 1984;64(02):315-333
- Korenkov M, Beckers A, Koebke J, Lefering R, Tiling T, Troidl H. Biomechanical and morphological types of the linea alba and its possible role in the pathogenesis of midline incisional hernia. *Eur J Surg* 2001;167(12):909-914
- Fachinelli A, Trindade MR, Fachinelli FA. Elastic fibers in the anterior abdominal wall. *Hernia* 2011;15(04):409-415
- Pentney BH. Small ventral hernias in children. *Practitioner* 1960;184:779-781
- Muschaweck U. Umbilical and epigastric hernia repair. *Surg Clin North Am* 2003;83(05):1207-1221
- Kokotovic D, Sjølander H, Gögenur I, Helgstrand F. Watchful waiting as a treatment strategy for patients with a ventral hernia appears to be safe. *Hernia* 2016;20(02):281-287
- Henriksen NA, Montgomery A, Kaufmann R. European and Americas Hernia Societies (EHS and AHS), et al. Guidelines for treatment of umbilical and epigastric hernias from the European Hernia Society and Americas Hernia Society. *Br J Surg* 2020;107(03):171-190