

# International multicenter comparative trial of transluminal EUS-guided biliary drainage via hepatogastrostomy vs. choledochoduodenostomy approaches

## Authors

Mouen A. Khashab<sup>1</sup>, Ahmed A. Messallam<sup>1</sup>, Irene Penas<sup>2</sup>, Yousuke Nakai<sup>3</sup>, Rani J. Modayil<sup>4</sup>, Carlos De la Serna<sup>2</sup>, Kazuo Hara<sup>3</sup>, Mohamad El Zein<sup>1</sup>, Stavros N. Stavropoulos<sup>4</sup>, Manuel Perez-Miranda<sup>2</sup>, Vivek Kumbhari<sup>1</sup>, Saowanee Ngamruengphong<sup>1</sup>, Vinay K. Dhir<sup>6</sup>, Do Hyun Park<sup>7</sup>

## Institutions

Institutions are listed at the end of article.

## Bibliography

**DOI** <http://dx.doi.org/10.1055/s-0041-109083>  
Published online: 15.1.2016  
Endoscopy International Open 2016; 04: E175–E181  
© Georg Thieme Verlag KG  
Stuttgart · New York  
E-ISSN 2196-9736

## Corresponding author

**Mouen A. Khashab, M.D.**  
Associate Professor of Medicine  
Director of Therapeutic  
Endoscopy  
Johns Hopkins Hospital  
1800 Orleans St, Suite 7125 B  
Baltimore, MD 21205  
Phone: (443) 287-1960  
[mkhasha1@jhmi.edu](mailto:mkhasha1@jhmi.edu)

**Background and study aims:** Endoscopic ultrasound-guided biliary drainage (EUS-BD) can be performed entirely transgastrically (hepatogastrostomy/EUS-HG) or transduodenally (choledochoduodenostomy/EUS-CDS). It is unknown how both techniques compare. The aims of this study were to compare efficacy and safety of both techniques and identify predictors of adverse events.

**Patients and methods:** Consecutive jaundiced patients with distal malignant biliary obstruction who underwent EUS-BD at multiple international centers were included. Technical/clinical success, adverse events, stent complications, and survival were assessed.

**Results:** A total of 121 patients underwent EUS-BD (CDS 60, HG 61). Technical success was achieved in 112 (92.56%) patients (EUS-CDS 93.3%, EUS-HG 91.8%,  $P=0.75$ ). Clinical success was attained in 85.5% of patients who underwent EUS-CDS group as compared to 82.1% of patients who underwent EUS-HG ( $P=0.64$ ). Adverse events occurred more commonly in the EUS-HG group (19.67% vs. 13.3%,  $P=0.37$ ). Both plastic

stenting (OR 4.95, 95%CI 1.41–17.38,  $P=0.01$ ) and use of non-coaxial electrocautery (OR 3.95, 95%CI 1.16–13.40,  $P=0.03$ ) were independently associated with adverse events. Length of hospital stay was significantly shorter in the CDS group (5.6 days vs. 12.7 days,  $P<0.001$ ). Mean follow-up duration was  $151 \pm 159$  days. The 1-year stent patency probability was greater in the EUS-CDS group [0.98 (95%CI 0.76–0.96) vs 0.60 (95%CI 0.35–0.78)] but overall patency was not significantly different. There was no difference in median survival times between the groups ( $P=0.36$ )

**Conclusions:** Both EUS-CDS and EUS-HG are effective and safe techniques for the treatment of distal biliary obstruction after failed ERCP. However, CDS is associated with shorter hospital stay, improved stent patency, and fewer procedure- and stent-related complications. Metallic stents should be placed whenever feasible and non-coaxial electrocautery should be avoided when possible as plastic stenting and non-coaxial electrocautery were independently associated with occurrence of adverse events.

## Introduction

Endoscopic ultrasonography (EUS) has evolved from a diagnostic to a therapeutic modality [1] and is increasingly used in the treatment and/or palliation of gastrointestinal and pancreaticobiliary diseases, including EUS-guided biliary drainage (EUS-BD). In patients with normal, non-obstructed upper gastrointestinal anatomy, selective bile duct cannulation by experts at endoscopic retrograde cholangiopancreatography (ERCP) is successful in over 90% of cases. When bile duct access is not possible due to failed cannulation, altered upper gastrointestinal tract anatomy, distorted ampulla, gastric outlet obstruction (GOO), periampullary diverticulum, or in-situ enteral stents, EUS-BD is increasingly

used as a minimally-invasive alternative to surgery or radiology [2–15].

EUS-BD can be performed by one of three methods. First, a rendezvous technique (RV) may be considered whereby a wire is placed into an intrahepatic or extrahepatic bile duct, passed through the papilla, and retrieved by a duodenoscope for transpapillary interventions. Second, direct transluminal stenting (TL) using a transgastric (hepatogastrostomy [HG]) or transduodenal approach (choledochoduodenostomy [CDS]) may be performed without accessing the papilla [16, 17]. A third approach that has not been extensively reported is EUS-guided antegrade transpapillary (or trans-anastomotic) biliary stent placement [18, 19].

## License terms



EUS-BD using either a RV or TL techniques requires needle puncture via an intrahepatic or an extrahepatic route. The optimal access route is optimal for either technique has not yet been established. The primary aim of this study was to compare the efficacy of the EUS-HG and EUS-CDS techniques. Secondary aims were to compare the safety of both techniques and to identify predictors of adverse events.

## Patients and methods

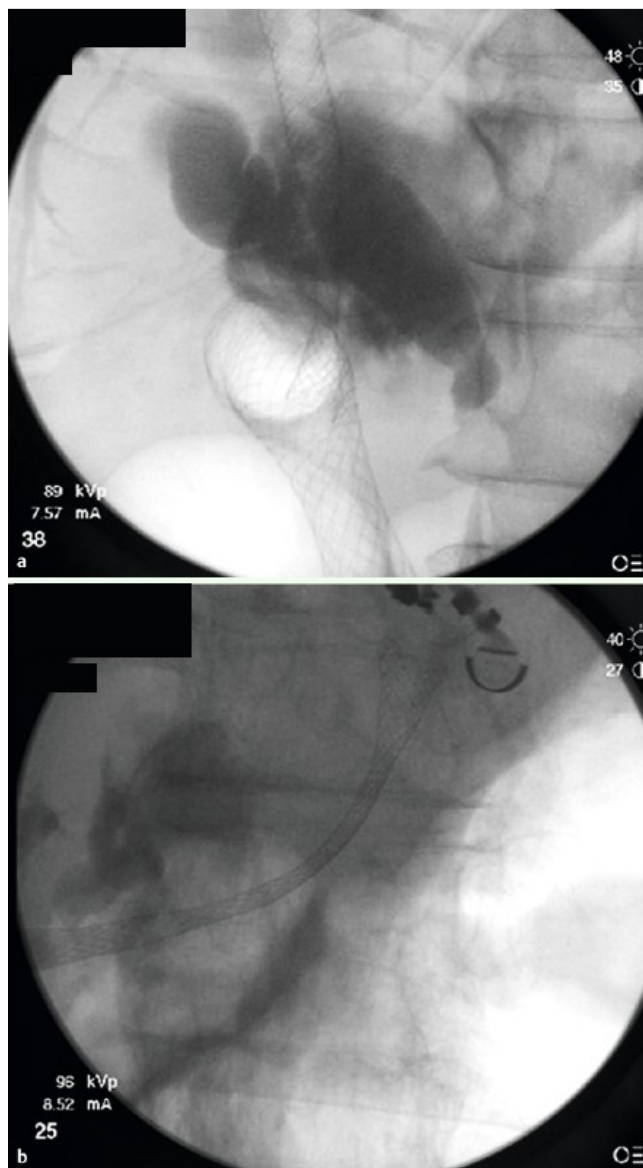
This was an international, multicenter, retrospective comparative cohort study at 7 tertiary centers (2 United States, 1 European, 4 Asian). All participating sites represented tertiary centers with busy pancreaticobiliary services where more than 1000 ERCPs are performed annually, with >90% success of biliary cannulation. All procedures were performed by experienced therapeutic endoscopists who each had performed more than 20 successful EUS-BD procedures. The endoscopy and/or billing databases at all centers were searched for patients who underwent EUS-BD for relief of distal malignant biliary obstruction after at least one failed ERCP between July 2008 and April 2014. Patients with malignant biliary obstruction and failed ERCP at all participating centers were initially referred for EUS-BD. Patients who failed EUS-BD were sent for percutaneous transhepatic biliary drainage (PTBD). Only patients with distal malignant biliary obstruction were included in this study. Patients were excluded if they had benign biliary strictures, proximal (<2 cm from the hilum) malignant biliary strictures, and/or altered anatomy precluding either EUS-HG or EUS-CDS. This retrospective study was approved by the Institutional Review Boards for Human Research and complied with Health Insurance Portability and Accountability Act (HIPAA) regulations at each participating institution.

## Definitions

Technical success was defined as successful stent placement in the desired location as determined endoscopically and/or radiographically. Clinical success was defined as reduction in serum total bilirubin by 50% at 1 week or less than 3 mg/dL at 2 weeks after the procedure. Coaxial electrocautery was defined as the usage of a 6-French (F) cystotome for dilation, while non-coaxial electrocautery was defined as usage of freehand needle knife to obtain access. Procedure-related complications were recorded and included peritonitis, bile leak, cholangitis, bleeding, pancreatitis, intraperitoneal stent migration, subcapsular liver hematoma, pneumoperitoneum, perforation, retained sheared wire, and procedure-related death. All hospitalizations, procedures, and/or surgeries needed to treat procedure-related complications were tracked and recorded. Adverse events were graded according to the ASGE lexicon's severity grading system [20]. Stent occlusion was defined as recurrence of jaundice with endoscopic/radiographic evidence of stent occlusion after initial successful EUS-BD. Stent patency duration was defined as the time between stent placement and its occlusion.

## EUS-BD using TL techniques

A linear echoendoscope was used to achieve biliary access within a segment of dilated bile duct proximal to the site of obstruction. The tip of the echoendoscope was positioned in the gastric fundus or duodenal bulb when accessing the intrahepatic or extrahepatic bile duct, respectively. A 19- or 22-gauge (G) fine-needle aspiration (FNA) needle was used to puncture the bile duct with



**Fig. 1** Fluoroscopic images demonstrating metallic stents across created choledochoduodenostomy (a) and hepatogastrostomy (b).

access confirmed by contrast injection and fluoroscopic imaging. A 0.035-inch, 0.025-inch, or 0.018 inch guidewire was then advanced into the bile duct. The smaller 0.018 inch wires needed to be exchanged for larger wires before stent placement. The puncture track was dilated with a dilating catheter or dilation balloon and a variety of devices were used to facilitate stent placement (e.g. Hurricane balloon, Boston Scientific, Natick, MA, USA; CRE balloon, Boston Scientific; Soehendra Biliary Dilation Catheter, Cook Medical, Winston-Salem, NC; Cystotome, Cysto-Gastro set, Endo-flex, Voerde, Düsseldorf, Germany; needle knife, Cook Medical). These devices were selected based on the patient's anatomy and features of the obstructing stricture. Stent insertion was then performed via antegrade approach (● Fig. 1a, b) [14,21].

## Statistical analysis

Results are reported as mean  $\pm$  standard deviation (SD) for quantitative variables, and absolute and relative frequencies for categorical variables. Statistical analyses were performed using the

**Table 1** Baseline characteristics and outcomes of CDS and HG groups.

	CDS (n=60)	HG (n=61)	P value
Mean age (yr)	67.6 ± 13	63.6 ± 13.8	0.10
Female	46.7	37.7	0.31
<b>Indication for EUS-BD</b>			
Obscured ampulla by tumor or stent	27 (45)	18 (29.5)	0.08
Distorted anatomy/difficult cannulation	19 (31.6)	24 (39.3)	0.38
Gastric outlet obstruction	14 (23.3)	14 (23)	0.96
Others	0 (0)	6 (9.8)	0.04
Mean maximum bile duct diameter (mm)	15.9 ± 6	12.95 ± 4.5	0.02
<b>Electrocautery dilation</b>	Electrocautery: 40%	Electrocautery: 39.3%	0.94
	Non-coaxial: 16.7%	Non-coaxial: 10%	0.28
	Coaxial: 26.9%	Coaxial: 34.4%	0.39
<b>Stent material</b>	Metal: 93.1%	Metal: 87.9%	0.34
	Plastic: 6.9%	Plastic: 12.1%	
Mean pre-EUS-BD bilirubin (mg/dL)	11.3 ± 6.7	8.3 ± 8.6	0.002
Technical success (%)	93.33	91.8	0.75
Clinical success (%)	85.5	82.1	0.64
Procedure duration (mins)	51 ± 34.9	45.3 ± 34.6	0.37
Length of hospital stay (day)	5.6 ± 6	12.7 ± 11.5	<0.001
<b>Adverse events, n (%)</b>	All AE: 8 (13.3)	All AE: 12 (19.67)	0.35
	Mild: 4 (6.67)	Mild: 5 (8.2)	0.75
	Moderate: 3 (5)	Moderate: 5 (8.2)	0.47
	Severe: 0 (0)	Severe: 2 (3.3)	0.16
	Death: 1 (1.67)	Death: 0 (0)	0.31
	Non- mild: 4 (6.67)	Non- mild: 7 (11.48)	0.36
<b>Need for stent exchange during long-term follow-up</b>	8 (stent migration 3; stent occlusion 5)	16 (stent migration 4; stent occlusion 12)	0.21
Mean follow up (days)	152.2 ± 176.7	151.1 ± 141.1	0.45

CDS, choledochoduodenostomy; HG, hepatogastrostomy; EUS-BD, endoscopic ultrasound-guided biliary drainage; AE, adverse events

Student's *t* test and the Mann Whitney U for normally distributed and non-normally continuous variables, respectively. The chi-square or Fisher exact test was used to compare categorical variables. Two-tailed *P* values <0.05 were considered statistically significant. Univariable logistic regression analyses were performed to evaluate possible factors associated with clinical success and adverse events. Multivariable logistic regression of predictors of adverse events was performed to adjust for EUS-BD route if univariable analysis was significant/nearly significant (*P*<0.1). EUS-BD route was considered clinically significant and was therefore included in the multivariable model. For time-dependent adverse events (stent occlusion/migration), proportional hazards assumption was not fulfilled and, therefore, were analyzed by reporting the "survival probability" at 6 months and 1 year as appropriate. Stent patency duration and patient survival times were estimated by the Kaplan-Meier analysis and differences were tested via log rank test. For stent patency, patients were censored at time of analysis, date of last follow up or death. For survival analysis, patients were censored at time of analysis or date of last follow up. Analyses were performed using Stata SE 12.0 (Stata Corporation, Dallas, TX) software package.

## Results

A total of 121 patients (mean age 65.5 ± 13.5 years, female 51 [42%], pancreatic cancer 65 [54%]) underwent EUS-BD. A total of 60 patients (49.6%) underwent EUS-CDS while 61 patients (61.4%) underwent EUS-HG (Table 1). All patients had failed a prior attempt at ERCP. The reason for the ERCP failure and subsequent EUS-BD was obscured ampulla by invasive cancer or enter-

al stent (n=45), distorted anatomy/difficult cannulation (n=43), gastric outlet obstruction (n=28; duodenal bulb 5, second duodenum 18, unspecified=5), and others (n=5). Electrocautery was used during 39.7% (48/121) of cases [coaxial (using cystotome) n=35, non-coaxial (using needle knife) n=16; 3 patients had both used].

EUS-guided cholangiography was successful in 97.5% of patients and delineated distal common bile duct stricture in all subjects. Stent placement in the desired location (technical success) was achieved in 112 patients (92.6%) (EUS-CDS 93.3%, EUS-HG 91.8%, *P*=0.75). A metallic biliary stent was inserted in 102 patients while a plastic stent was utilized in 10. Clinical success in patients with successfully placed biliary stents was attained in 85.5% of those who underwent EUS-CDS as compared to 82.1% of patients who underwent EUS-HG (*P*=0.64). No independent variable was found to significantly predict clinical success (Table 2). Length of hospital stay was significantly shorter in the EUS-CDS group (5.6 ± 6 days vs. 12.7 ± 11.5 days, *P*<0.001). Mean duration of follow up in the study cohort was 151 ± 159 days, with no difference between the two groups (*P*=0.45). Adverse events (AEs) occurred in 15 patients with a total of 20 AEs recorded including peritonitis, bile leak, cholangitis, bleeding, intraperitoneal stent migration, and pancreatitis, (8 graded as mild, 9 moderate, 2 severe, and 1 fatal) (Table 3). Adverse events occurred more commonly in the EUS-HG group, although the difference did not reach statistical significance (19.67% vs. 13.3%, *P*=0.37) (Table 4). On multivariable analysis, both plastic stenting (OR 4.95, 95%CI 1.41 – 17.38, *P*=0.01) and use of non-coaxial electrocautery (OR 3.95, 95%CI 1.16 – 13.40, *P*=0.03) were independently associated with occurrence of AEs (Table 5 and Table 6).

**Table 2** Univariable analysis of predictors of clinical success in technically successful EUS-BD patients.

	Odds ratio (95% CI)	P value
Age	1.01 (0.97–1.04)	0.76
Female gender	1.19 (0.42–3.33)	0.75
Hepatogastrostomy	0.78 (0.28–2.16)	0.64
Plastic stenting	0.75 (0.14–3.88)	0.73
Electrocautery	1.38 (0.48–4.0)	0.55
Coaxial electrocautery	1.15 (0.37–3.61)	0.80
Non-coaxial electrocautery	2.76 (0.34–22.56)	0.34

EUS-BD, endoscopic ultrasound-guided biliary drainage

**Table 3** Adverse events associated with EUS-guided biliary drainage.

Adverse event	Frequency	Grade
Peritonitis	4	2 Mild 2 Moderate
Bile leak	3	2 Mild 1 Moderate
Cholangitis	3	1 Mild 1 Moderate 1 Death
Bleeding	2	1 Mild 1 Moderate
Intraperitoneal stent	2	2 Severe
Pancreatitis	2	1 Mild 1 Moderate
Perforation- EUS-BD-related	1	Moderate
Pneumoperitoneum	1	Moderate
Hepatic collection	1	Moderate
Sheared wire	1	Mild

EUS-BD, endoscopic ultrasound-guided biliary drainage

A total of 17 stent occlusions and 7 stent migrations requiring 22 re-intervention procedures were recorded during a mean long-term follow-up of  $151.7 \pm 158.9$  days. Stent occlusion and/or migration occurred more often in the EUS-HG group (26.2% vs 13.3%) (Table 7). Probability of stent patency at 1 year was

greater in the EUS-CDS groups (0.98, 95%CI 0.76–0.96 vs 0.60, 95%CI 0.35–0.78). Stent patency duration was longer in patients who underwent EUS-CDS as compared to those who underwent EUS-HG, although the difference was not statistically significant ( $P=0.18$ ) (Fig. 2). There was no difference in the success of re-interventions for stent migration and/or occlusion between the two groups (100% and 92.9% for EUS-CDS and EUS-HG, respectively,  $P=0.42$ ). Similarly, there was no statistical difference in the median survival time between the two groups: 252 days (95%CI 131–369) for EUS-CDS and 142 days (95%CI 82–256) for EUS-HG (log rank test,  $P=0.36$ ) (Fig. 3).

## Discussion



The current study assessed outcomes of patients who underwent EUS-BD using a transluminal technique and directly compared efficacy and safety of the procedure when performed via HG to that performed via CDS. Both techniques were associated with equivalent and high efficacy rate with improvement in cholestasis in the majority of patients. AEs occurred more commonly in patients who underwent EUS-HG (19.67% vs. 13.3%) although the difference was not statistically significant. There were no severe adverse events in the EUS-CD group. On the contrary, this was observed in 3.3% of patients who underwent EUS-HG. There was one death in EUS-CDS group, which was due to cholangitis that occurred within 1 week of the procedure.

EUS-BD using either a RV or TL technique requires needle puncture via an intrahepatic or an extrahepatic route. However, the optimal access route has not yet been established for either technique. In cases of rendezvous EUS-BD, Dhir and colleagues recently found that an extrahepatic rendezvous (using transduodenal puncture) was associated with significantly shorter procedure times, less post-procedure pain, bile leak, and air under the diaphragm [22]. In addition, they found that success is likely higher with extrahepatic rendezvous, as was confirmed by Park et al. (93% vs. 50%) [23]. Similarly, in cases of direct transluminal EUS-BD (i.e., all cases included in the current study), an extrahepatic route (choledochoduodenostomy) is believed to be safer than an intrahepatic route (hepatogastrostomy) [7]. However,

**Table 4** Comparison of adverse events in EUS-CDS and EUS-HG<sup>1</sup>.

Adverse events	Overall Frequency	EUS-CDS		EUS-HG	
		Frequency	(n) Grade	Frequency	(n) Grade
Peritonitis	4	1	Moderate	3	(2)Mild (1)Moderate
Bile leak	3	1	Mild	2	(1)Mild (1)Moderate
Cholangitis	3	1	Death <sup>1</sup>	2	(1)Mild (1)Moderate
Bleeding	2	1	Mild	1	Moderate
Intraperitoneal stent	2	0	N/A	2	Severe
Pancreatitis	2	2	(1)Mild (1)Moderate	0	N/A
Perforation (EUS-BD-related)	1	1	Moderate	0	N/A
Pneumoperitoneum	1	1	Mild	0	N/A
Hepatic collection	1	0	N/A	1	Moderate
Sheared wire	1	0	N/A	1	Mild
<b>Total</b>	<b>20</b>	<b>8</b>		<b>12</b>	

EUS-BD, endoscopic ultrasound-guided biliary drainage

<sup>1</sup> Death due to a procedure-related complication occurred in one patient among the CDS group and was due to cholangitis within 1 week of the procedure.

**Table 5** Univariable analysis of predictors of adverse events after EUS-guided biliary drainage.

Predictor	Univariable analysis	
	Odds ratio (95%CI)	P value
Age	0.99 (0.96 – 1.03)	0.73
Gender (F)	0.70 (0.25 – 1.90)	0.49
Hepatogastrostomy	1.56 (0.59 – 4.12)	0.37
Plastic stenting	4.99 (1.5 – 16.51)	<b>0.01</b>
Electrocautery (coaxial and non-coaxial)	1.65 (0.63 – 4.31)	0.31
Non-coaxial electrocautery	3.32 (1.07 – 10.28)	<b>0.04</b>
Coaxial electrocautery	0.76 (0.25 – 2.27)	0.62

EUS, endoscopic ultrasound

**Table 6** Multivariable analysis of predictors of adverse events after EUS-BD adjusting for EUS-BD route.

	Multivariable analysis	
	Odds Ratio (95%CI)	P value
Hepatogastrostomy	1.63 (0.56 – 4.74)	0.374
Plastic stenting	4.95 (1.41 – 17.38)	<b>0.013</b>
Non-coaxial electrocautery	3.95 (1.16 – 13.40)	<b>0.027</b>

EUS-BD, endoscopic ultrasound-guided biliary drainage

**Table 7** Stent occlusion and migration rates.

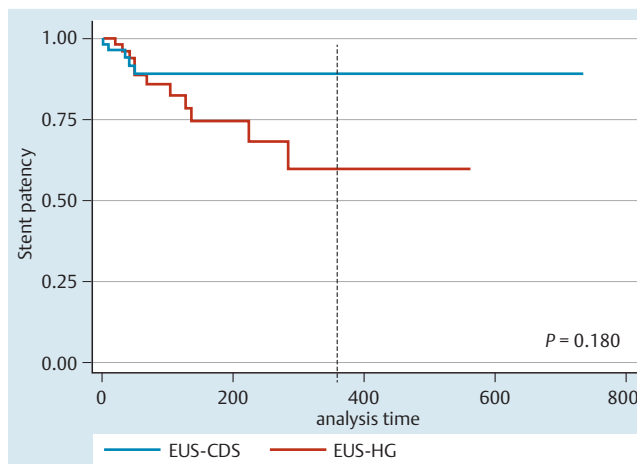
	EUS-CDS (n=60)	EUS-HG (n=61)
Stent occlusion, n (%)	5 (8.3)	12 (19.7)
Stent migration, n (%)	3 (5)	4 (6.5)
Stent occlusion/migration, n (%)	8 (13.3)	16 (26.2)

EUS-CDS, endoscopic ultrasound-guided choledochoduodenostomy; HG, hepatogastrostomy

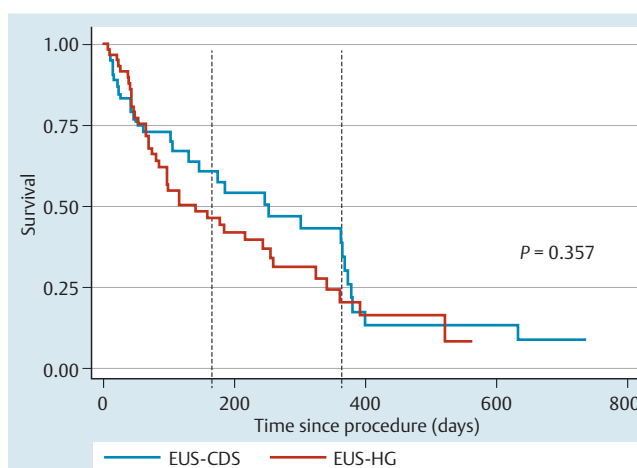
there is a dearth of studies comparing both techniques (EUS-CDS vs. EUS-HG).

Dhir and colleagues also compared success and complication rates in 68 patients undergoing EUS-BD via different methods [24]. EUS-BD was successful in 65 patients (95.6%). There was no significant difference in success rates with the different techniques. Complications were seen in 14 patients (20.6%) and mortality in three patients (4.4%). Complications were significantly higher for the intrahepatic route compared to the extrahepatic (transduodenal) route (30.5% vs. 9.3%,  $P=0.03$ ). There was no significant difference in complication rates among transluminal and transpapillary stent placements, or direct and rendezvous stenting. Logistic regression analysis showed that transhepatic access was the only independent risk factor for complications ( $P=0.03$ ). The authors concluded that EUS-BD can be carried out with high success rates regardless of the choice of access route, stent direction or drainage route. However, complications were significantly higher with the intrahepatic access route. They recommended that the extrahepatic (transduodenal) route should be chosen for EUS-BD and rendezvous stent placements, when both routes are available.

Only one small randomized trial has compared outcomes in patients who underwent EUS-BD using CDS to those using HGS and found that both techniques were associated with similar efficacy and safety [25].



**Fig. 2** Kaplan-Meier plot estimates of the stent patency duration after EUS-CDS and EUS-HG. Dashed line represents probability of stent patency at 1 year: EUS-CDS 0.98 (96%CI: 0.76 – 0.96) vs EUS-HG 0.60 (95%CI: 0.35 – 0.78). Stent patency duration was not significantly different via log-rank test ( $P=0.228$ ).



**Fig. 3** Kaplan-Meier plot estimates of the overall survival after EUS-CDS and EUS-HG. Median survival times (95% CI) were 252 days (131 – 369) for EUS-CDS and 142 days (82 – 256) for EUS-HG. There was no significant difference in survival times between the two groups ( $P=0.357$  via log rank test). Survival probabilities (95% CI) at 6 months were EUS-CDS 0.57 (0.41 – 0.71) vs EUS-HG 0.44 (0.30 – 0.57); and at 1 year, EUS-CDS 0.39 (0.22 – 0.55) vs EUS-HG 0.20 (0.09 – 0.35), as indicated by the dashed line.

Why does it appear that the EUS-HG route may lead to an increased risk of complications compared to EUS-CDS? First, an intrahepatic route involves needle puncture through the thicker gastric wall and a few centimeters of hepatic parenchyma with greater tissue resistance, which (along with the angulated puncture almost perpendicular to the long access of the echoendoscope) makes puncture and stent deployment more challenging. The use of the newer front-viewing echoendoscope for such punctures may be less challenging. Second, the needle puncture route involves the peritoneal cavity, which risks pneumoperitoneum and peritoneal bile leakage. Third, movement of the liver during respiration may lead to both stent migration with resulting bilomas and increased trauma to the bilioenteric tract (which increases risk for post procedure pain and bile leak). Finally, smaller-caliber intrahepatic ducts may not allow placement of wider 8- to 10-mm metallic stents, which can theoretically pre-

dispose to pneumoperitoneum and bile leakage due to incomplete sealing of the bilioenteric fistula. Extrahepatic access (EUS-CDS), on the other hand, has many advantages, including thinner duodenal wall puncture, close proximity of duodenum to dilated bile duct, retroperitoneal location of the bile duct, and a relatively fixed bile duct with minimal respiratory influence.

Park and colleagues studied predictors of AEs in 57 patients who underwent EUS-BD with transluminal stenting [7]. As with the current study, Park's study showed no difference in technical success, clinical success, or rates of AEs between the EUS-CDS and EUS-HG groups, although the current study reports more frequent AEs with EUS-HG. Park and colleagues showed that use of electrocautery was independently associated with occurrence of AEs (OR 12.4,  $P=0.01$ ). However, non-coaxial electrocautery (using needle knife) was used for tract dilation in that study. In the current study, coaxial and non-coaxial electrocautery were separately analyzed and only non-coaxial electrocautery was independently associated with AEs (OR 3.95,  $P=0.03$ ). We recommend using coaxial electrocautery (i.e., with the cystotome) when needed for tract dilation during EUS-BD because it appears to be safer than non-coaxial electrocautery (i.e., needle knife) and facilitates the procedure.

Stent complications, including stent migration and stent occlusion, were comparable in both groups. Proportional hazards assumption was not met, therefore, a comparison of median stent patency duration was not feasible. Stent patency probability at 1 year was higher in the EUS-CDS group with non-overlapping confidence intervals. However, stent patency duration estimates were not significantly different via log rank test ( $P=0.18$ ) (Fig. 2). Although the success rates for re-interventions in both groups were not statistically different, repeat procedures may be more technically challenging after EUS-HG than after EUS-CDS.

It is currently debatable whether plastic or metallic stents should be placed during EUS-BD. In the current study, AEs were significantly more common in patients who underwent plastic stenting as compared to metallic stenting (42.86% vs 13.08%, respectively) and plastic stenting was independently associated with AEs (OR 4.95, 95%CI 1.41 – 17.38,  $P=0.01$ ). Gupta et al. reported no significant difference in complication rates between plastic and metal stenting, although a trend toward better outcomes was present in patients who underwent EUS-BD with placement of metallic stents ( $P=0.09$ ) [26]. In addition, there was a significantly higher incidence of cholangitis in patients with plastic stents in that study (11% vs. 3%,  $P=0.02$ ). We believe that use of the larger covered metallic stents results in complete seal of the iatrogenic bilioenteric tracts and may prevent bile leak. In addition, metallic stents are associated with longer patency rates.

Our study has limitations. It was retrospective study with inherent design limitations. Selection bias may have occurred given the non-randomized nature of the study. The small sample size may have resulted in type II error in terms of predictors of occurrence of AEs. Inclusion of multiple centers may have introduced heterogeneity but, at the same time, it renders the study results more widely applicable. Because all of the endoscopists were experts in interventional endoscopy, the results may not be applicable to endoscopists with less experience in EUS-BD. Lastly, procedures were not standardized as techniques and the accessories used are usually driven by procedural factors, patients' anatomy, and availability of accessories and devices.

In conclusion, both EUS-CDS and EUS-HG are effective and safe techniques for treatment of distal biliary obstruction after failed ERCP. However, EUS-CDS is associated with shorter hospital stay

and may be the safer approach with less severe complications. Metallic stents should be placed whenever feasible as plastic stenting was independently associated with occurrence of AEs. The use of coaxial electrocautery for tract dilation is safe during EUS-BD, whereas non-coaxial electrocautery should be avoided if possible because of increased risk of AEs.

**Competing interests:** Dr. Khashab is a consultant for Boston Scientific, Xlumena and Olympus America and has received research support from Cook Medical.

#### Institutions

- <sup>1</sup> Johns Hopkins Medical Institutions, Baltimore, MD, United States
- <sup>2</sup> Hospital Universitario-Roi Horteiga, Valladolid, Spain.
- <sup>3</sup> University of Tokyo, Tokyo, Japan.
- <sup>4</sup> Winthrop University, Mineola, NY, United States.
- <sup>5</sup> Aichi Cancer Center Hospital, Nagoya, Japan
- <sup>6</sup> Baladota Institute of Digestive Sciences, Mumbai, India.
- <sup>7</sup> Asan Medical Center, Seoul, South Korea.

#### References

- 1 Khashab MA, Varadarajulu S. Endoscopic ultrasonography as a therapeutic modality. *Curr Opin Gastroenterol* 2012; 28: 467–476
- 2 Kahaleh M, Hernandez AJ, Tokar J et al. Interventional EUS-guided cholangiography: evaluation of a technique in evolution. *Gastrointest Endosc* 2006; 64: 52–59
- 3 Maranki J, Hernandez AJ, Arslan B et al. Interventional endoscopic ultrasound-guided cholangiography: long-term experience of an emerging alternative to percutaneous transhepatic cholangiography. *Endoscopy* 2009; 41: 532–538
- 4 Kim YS, Gupta K, Mallery S et al. Endoscopic ultrasound rendezvous for bile duct access using a transduodenal approach: cumulative experience at a single center. A case series. *Endoscopy* 2010; 42: 496–502
- 5 Fabbri C, Luigiano C, Fuccio L et al. EUS-guided biliary drainage with placement of a new partially covered biliary stent for palliation of malignant biliary obstruction: a case series. *Endoscopy* 2011; 43: 438–441
- 6 Komaki T, Kitano M, Sakamoto H et al. Endoscopic ultrasonography-guided biliary drainage: evaluation of a choledochoduodenostomy technique. *Pancreatol* 2011; 11: 47–51
- 7 Park DH, Jang JW, Lee SS et al. EUS-guided biliary drainage with transluminal stenting after failed ERCP: predictors of adverse events and long-term results. *Gastrointest Endosc* 2011; 74: 1276–1284
- 8 Hara K, Yamao K, Niwa Y et al. Prospective clinical study of EUS-guided choledochoduodenostomy for malignant lower biliary tract obstruction. *Am J Gastroenterol* 2011; 106: 1239–1245
- 9 Iwashita T, Lee JG, Shinoura S et al. Endoscopic ultrasound-guided rendezvous for biliary access after failed cannulation. *Endoscopy* 2012; 44: 60–65
- 10 Khashab M, Fujii LL, Baron TH et al. EUS-guided biliary drainage for patients with malignant biliary obstruction with an indwelling duodenal stent (with video). *Gastrointest Endosc* 2012; 76: 209–213
- 11 Henry WA, Singh VK, Kalloo AN et al. Simultaneous EUS-guided transbulbar pancreaticobiliary drainage (with video). *Gastrointest Endosc* 2012; 76: 1065–1067
- 12 Dhir V, Bhandari S, Bapat M et al. Comparison of EUS-guided rendezvous and precut papillotomy techniques for biliary access (with videos). *Gastrointest Endosc* 2012; 75: 354–359
- 13 Shah JN, Marson F, Weilert F et al. Single-operator, single-session EUS-guided anterograde cholangiopancreatography in failed ERCP or inaccessible papilla. *Gastrointest Endosc* 2012; 75: 56–64
- 14 Khashab MA, Valeshabad AK, Modayil E et al. EUS-guided biliary drainage by using a standardized approach for malignant biliary obstruction: rendezvous versus direct transluminal techniques (with videos). *Gastrointest Endosc* 2013; 78: 734–741
- 15 Khashab MA, Valeshabad AK, Afghani E et al. A comparative evaluation of EUS-guided biliary drainage and percutaneous drainage in patients with distal malignant biliary obstruction and failed ERCP. *Dig Dis Sci* 2015; 60: 557–565
- 16 Itoi T, Yamao K. EUS 2008 Working Group document: evaluation of EUS-guided choledochoduodenostomy (with video). *Gastrointest Endosc* 2009; 69: 8–S12

- 17 Savides TJ, Varadarajulu S, Palazzo L. EUS 2008 Working Group document: evaluation of EUS-guided hepaticogastrostomy. *Gastrointest Endosc* 2009; 69: S3–S7
- 18 Artifon EL, Safatle-Ribeiro AV, Ferreira FC et al. EUS-guided antegrade transhepatic placement of a self-expandable metal stent in hepaticojejunal anastomosis. *J Oncol Pract* 2011; 12: 610–613
- 19 Nguyen-Tang T, Binmoeller KF, Sanchez-Yague A et al. Endoscopic ultrasound (EUS)-guided transhepatic antegrade self-expandable metal stent (SEMS) placement across malignant biliary obstruction. *Endoscopy* 2010; 42: 232–236
- 20 Cotton PB, Eisen GM, Aabakken L et al. A lexicon for endoscopic adverse events: report of an ASGE workshop. *Gastrointest Endosc* 2010; 71: 446–454
- 21 Khashab MA, Kumbhari V, Kalloo AN et al. EUS-guided biliary drainage by using a hepatogastrostomy approach. *Gastrointest Endosc* 2014; 78: 675
- 22 Dhir V, Bhandari S, Bapat M et al. Comparison of transhepatic and extrahepatic routes for EUS-guided rendezvous procedure for distal CBD obstruction. *United European Gastroenterol J* 2013; 1: 103–108
- 23 Park do H, Jeong SU, Lee BU et al. Prospective evaluation of a treatment algorithm with enhanced guidewire manipulation protocol for EUS-guided biliary drainage after failed ERCP (with video). *Gastrointest Endosc* 2013; 78: 91–101
- 24 Dhir V, Artifon EL, Gupta K et al. Multicenter study on endoscopic ultrasound-guided expandable biliary metal stent placement: Choice of access route, direction of stent insertion, and drainage route. *Dig Endosc* 2014; 26: 430–435
- 25 Artifon EL, Marson FP, Gaidhane M et al. Hepaticogastrostomy or choledochoduodenostomy for distal malignant biliary obstruction after failed ERCP: is there any difference? *Gastrointest Endosc* 2015; 81: 950–959
- 26 Gupta K, Perez-Miranda M, Kahaleh M et al. Endoscopic ultrasound-assisted bile duct access and drainage: multicenter, long-term analysis of approach, outcomes, and complications of a technique in evolution. *J Clin Gastroenterol* 2014; 48: 80–87